



## Cyproterone

Updated: July 5, 2017.

## OVERVIEW

### Introduction

Cyproterone is a steroidal antiandrogen that has been used in the treatment of prostate cancer in many countries of the world, but not in the United States. Cyproterone therapy can be associated with serum enzyme elevations during therapy and has been linked to many instances of clinically apparent acute liver injury, some of which were fatal.

### Background

Cyproterone (syə pro' ter one) is a synthetic steroidal antiandrogen that has been used to treat prostate cancer in many countries of the world, but was never approved for this use in the United States. Cyproterone is a derivative of hydroxyprogesterone and has mild progesterone-like effects. Its mechanism of action, however, appears to be via blocking of the androgen receptor. Alone or when combined with other agents, cyproterone has been found to be palliative in patients with advanced prostate cancer. Cyproterone has also been evaluated for hormonally sensitive benign conditions such as endometriosis, precocious puberty and infertility, but has not been formally recommended for these uses. Because of its potential to cause liver injury and its inferior efficacy in comparison to other antiandrogens, cyproterone is now rarely used. The typical dose regimen is 50 to 100 mg two to three times daily, often in combination with a gonadotropin releasing hormone agonist such as leuprolide, goserelin, histrelin or triptorelin. Common side effects include hot flashes, sexual dysfunction, nausea, diarrhea, weight change and fluid retention.

### Hepatotoxicity

Cyproterone has been associated with serum enzyme elevations during therapy in 10% to 14% of patients, but these elevations are usually transient and mild and often resolve even without dose modification. More importantly, cyproterone has been associated with many instances of clinically apparent liver injury with jaundice. The time to onset has ranged from a few months to as long as a year, but typically arises within 3 to 6 months of starting treatment. The liver injury is almost always hepatocellular with moderate to marked elevations in serum aminotransferase levels and minimal increases in alkaline phosphatase. Mixed and more cholestatic injury occurs occasionally and may have a more favorable prognosis. Importantly, the hepatocellular injury associated with cyproterone use is often severe and the mortality rate of patients presenting with jaundice is at least 10% (these patients frequently being elderly men with advanced prostate cancer and not qualifying for emergency liver transplantation). Immunoallergic features (fever, rash, eosinophilia) are uncommon, as are autoantibodies. Some patients, however, appear to respond to corticosteroid therapy and rare instances of autoimmune-hepatitis like injury have been attributed to cyproterone. Improvement is usually seen within 1 to 2

weeks of stopping cyproterone and resolution within 1 to 3 months. Nevertheless, many examples of progressive liver injury leading to death from hepatic failure despite prompt discontinuation of therapy have been reported. In rare cases, recovery has been incomplete and patients have had residual evidence of chronic liver disease or cirrhosis.

Likelihood score: B (likely cause of clinically apparent liver injury).

Chronic therapy with cyproterone has also been linked to cases of hepatocellular carcinoma, generally arising after years of therapy with high doses of cyproterone or its combination with other hormonal agents such as estrogens or oral contraceptives. Most cases of hepatocellular carcinoma arose in a noncirrhotic liver and without other evidence of chronic liver injury, although sometimes with elevations in alpha-fetoprotein levels. In some instances, liver cancer was found years after use of cyproterone. The association of cyproterone use with hepatocellular carcinoma remains somewhat controversial.

## Mechanism of Injury

The acute form of liver injury attributed to cyproterone use is probably due to an idiosyncratic reaction to a metabolite of the medication, rather than its antiandrogen or secondary estrogenic effects. The specific mechanism of liver injury caused by cyproterone is not known, but most antiandrogens have hepatotoxicity potential although some to a greater extent than others (cyproterone and flutamide more than bicalutamide and nilutamide).

## Outcome and Management

Cyproterone has been associated with liver injury ranging in severity from asymptomatic or mildly symptomatic elevations in serum enzymes to an acute hepatitis and acute liver failure. At least a dozen instances of fatality from cyproterone acute liver injury have been reported. In some instances, corticosteroids have been used with some evidence of benefit. The most important element is rapid discontinuation of treatment with the first signs of liver injury. Severe and even fatal recurrence of injury upon rechallenge has been reported and restarting of cyproterone after clinically apparent liver injury attributed to its use is inadvisable. Indeed, cross sensitivity to hepatic injury between cyproterone and other antiandrogens (flutamide) has also been reported.

Drug Class: [Antineoplastic Agents](#), [Antiandrogens](#)

## CASE REPORT

### Case 1. Severe acute hepatitis causing cirrhosis due to cyproterone.

[Modified from: Abenavoli L, Milic N, Beaugrand M. Severe hepatitis induced by cyproterone acetate: role of corticosteroids. A case report. *Ann Hepatol* 2013; 12: 152-5. [PubMed Citation](#).]

A 66 year old man with advanced prostate cancer developed fatigue and dark urine followed by jaundice approximately 9 months after starting cyproterone (200 mg daily). He had previously undergone prostatectomy and radiotherapy followed by a two year course of bicalutamide and goserelin. Because of evidence of progression, this regimen was switched to cyproterone. He had no previous history of liver disease and was known to have had normal liver tests in the past. He denied a history of alcohol abuse or risk factors for viral hepatitis and was taking no other medications or herbal products. On presentation, he was jaundiced but had no signs of chronic liver disease. Laboratory tests showed a total bilirubin of 22.3 mg/dL, ALT 2044 U/L, AST 1487 U/L, GGT 335 U/L and alkaline phosphatase 223 U/L (Table). The prothrombin index was 43%. Cyproterone was discontinued and he was admitted for evaluation and monitoring. Tests for hepatitis A, B, C and E and for EBV, HSV and CMV were negative. Autoantibodies were not present. Abdominal ultrasound showed increased hepatic echogenicity, but no evidence of biliary obstruction or gallstones. A liver biopsy showed acute

hepatocellular injury, portal and periportal inflammation, bridging necrosis and areas of regeneration. He was started on prednisone (60 mg daily) and ursodiol. Serum bilirubin and ALT levels began to decline, but a repeat liver biopsy showed evidence of active cirrhosis. Because of hyperglycemia, the prednisone dose was decreased and then stopped, which was followed by reappearance of jaundice. Prednisone and ursodiol were restarted and he again improved. Thereafter, the dose of prednisone was decreased slowly and ultimately withdrawn. Two years after the initial presentation he was asymptomatic, although liver tests were still slightly abnormal.

## Key Points

Medication:	Cyproterone (200 mg daily)
Pattern:	Hepatocellular (R=24)
Severity:	4+ (jaundice, hospitalization, cirrhosis)
Latency:	9 months
Recovery:	Incomplete
Other medications:	None mentioned

## Laboratory Values

Time After Starting	Time After Stopping	ALT (U/L)	Alk P (U/L)	Bilirubin (mg/dL)	Other
9 months	0	2044	223	22.3	Cyproterone stopped; Prednisone started
	1 week	1655	242	29.1	First liver biopsy
10 months	1 month	~300			Prednisone 20 mg/day
11 months	2 months	~50		0.6	Second liver biopsy; prednisone stopped
12 months	3 months	79	288	14.1	Prednisone restarted
14 months	5 months	~60		~5.0	
18 months	9 months	~50		1.7	Prednisone stopped
24 months	15 months	~50		1.7	
<b>Normal Values</b>		<b>&lt;40</b>	<b>&lt;110</b>	<b>&lt;1.2</b>	

\*Some values estimated from Figure 1.

## Comment

An elderly man developed a severe and protracted hepatitis 9 months after starting cyproterone. He was treated with prednisone and ursodiol, but improvement was slow. An initial attempt to withdraw corticosteroids was unsuccessful, but ultimately he was able to stop treatment. However, a liver biopsy showed cirrhosis and he had mild elevations in liver tests in follow up. Typical of cyproterone hepatotoxicity was the delayed latency, the hepatocellular pattern of injury and severe course. In several reports, corticosteroid therapy was considered to be beneficial, but controlled observations have not been made and remarkable spontaneous recovery can occur.

## PRODUCT INFORMATION

### REPRESENTATIVE TRADE NAMES

Cyproterone – Generic, Androcur®

*Box continues on next page...*

Box continued from previous page.

## DRUG CLASS

Antineoplastic Agents

## COMPLETE LABELING

Product labeling at DailyMed, National Library of Medicine, NIH

## CHEMICAL FORMULAS AND STRUCTURES

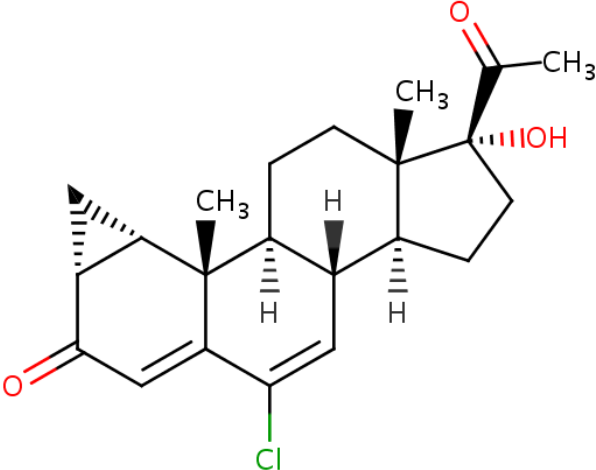
DRUG	CAS REGISTRY NUMBER	MOLECULAR FORMULA	STRUCTURE
Cyproterone [INN:BAN]	2098-66-0	C <sub>22</sub> -H <sub>27</sub> -Cl-O <sub>3</sub>	 <p>The chemical structure of Cyproterone is a complex steroid molecule. It features a four-ring steroid nucleus with several substituents: a ketone group at C3, a double bond between C4 and C5, a chlorine atom at C14, a methyl group at C13, a methyl group at C14, a methyl group at C17, and a hydroxyl group at C20. The stereochemistry is indicated with wedges and dashes.</p>

Table continued from previous page.

DRUG	CAS REGISTRY NUMBER	MOLECULAR FORMULA	STRUCTURE
17-Hydroxyprogesterone	68-96-2	C <sub>21</sub> -H <sub>30</sub> -O <sub>3</sub>	

## ANNOTATED BIBLIOGRAPHY

References updated: 05 July 2017

Zimmerman HJ. Antihypophyseal drugs. Hormonal derivatives and related drugs. In, Zimmerman HJ. Hepatotoxicity: the adverse effects of drugs and other chemicals on the liver. 2nd ed. Philadelphia: Lippincott, 1999, pp. 574-5.

*(Expert review of hepatotoxicity published in 1999 mentions that cyproterone leads to elevated aminotransferase levels in up to 30% of recipients and also causes acute, clinically apparent hepatocellular injury that can be fatal).*

Chitturi S, Farrell GC. Estrogen receptor antagonists. Adverse effects of hormones and hormone antagonists on the liver. In, Kaplowitz N, DeLeve LD, eds. Drug-induced liver disease. 3rd ed. Amsterdam: Elsevier, 2013, pp. 612.

*(Review of hepatotoxicity of hormonal products mentions that liver injury is well recognized with all antiandrogens including cyproterone).*

DeLeve LD. Cyproterone acetate. Cancer chemotherapy. In, Kaplowitz N, DeLeve LD, eds. Drug-induced liver disease. 3rd ed. Amsterdam: Elsevier, 2013, pp. 558-92.

*(Review of hepatotoxicity of cancer chemotherapeutic agents mentions that serum enzyme elevations are reported in 10-14% of patients and that 18 case reports of clinically apparent hepatitis attributed to cyproterone have been published with 6 fatalities).*

- Moy B, Lee RJ, Smith M. Anti-androgens. Natural products in cancer chemotherapy. In, Brunton LL, Chabner BA, Knollman BC, eds. Goodman & Gilman's the pharmacological basis of therapeutics. 12th ed. New York: McGraw-Hill, 2011, pp. 1764-7.
- (Textbook of pharmacology and therapeutics; mentions that cyproterone is a steroidal antiandrogen, but is associated with hepatotoxicity and has inferior efficacy compared to other forms of antiandrogens such as bicalutamide, flutamide and nilutamide).*
- Meijers WH, Willemse PH, Sleijfer DT, Mulder NH, Grond J. Hepatocellular damage by cyproterone acetate. Eur J Cancer Clin Oncol 1986; 22: 1121-2. PubMed PMID: 2946585.
- (Among 20 women with advanced breast cancer treated with cyproterone [200-400 mg daily], 3 developed minimal ALT [ $<3$  times ULN] and 2 severe ALT elevations [ $>10$  times ULN with mild jaundice], 12 and 21 weeks after starting, resolving within 2 to 3 weeks of stopping).*
- Willemse PH, Dikkeschei LD, Mulder NH, van der Ploeg E, Sleijfer DT, de Vries EG. Clinical and endocrine effects of cyproterone acetate in postmenopausal patients with advanced breast cancer. Eur J Cancer Clin Oncol 1988; 24: 417-21. PubMed PMID: 2968261.
- (23 women with breast cancer were treated with cyproterone [200-400 mg daily], of whom 7 [30%] developed serum enzyme elevations, 5 resolving without dose modification, but 2 requiring discontinuation because of hepatitis at 11 and 21 weeks after starting).*
- Lévesque H, Trivalle C, Manchon ND, Vinel JP, Moore N, Hémet J, Courtois H, et al. Fulminant hepatitis due to cyproterone acetate. Lancet 1989; 1 (8631): 215-6. PubMed PMID: 2563116.
- (78 year old man developed jaundice 5-6 months after starting cyproterone for prostate cancer [bilirubin 10.4 mg/dL, ALT 1015 U/L, Alk P 153 U/L, prothrombin index 45%], developing ascites and coma; dying 10 days after presentation).*
- Blake JC, Sawyerr AM, Dooley JS, Scheuer PJ, McIntyre N. Severe hepatitis caused by cyproterone acetate. Gut 1990; 31: 556-7. PubMed PMID: 2140997.
- (71 year old man with prostate cancer developed weakness 8 weeks after starting cyproterone followed by jaundice after 23 weeks [peak bilirubin 46.2 mg/dL, AST 790 U/L, Alk P 166 U/L], with development of ascites and slow but eventual complete recovery).*
- Dore B, Orget J, Irani J, Aubert J. [Hepatitis after treatment with cyproterone acetate. Apropos of a case]. J Urol (Paris) 1990; 96: 169-71. French. PubMed PMID: 2145371.
- (79 year old man developed jaundice 11 weeks after starting cyproterone for prostate cancer [bilirubin 5.2 mg/dL, ALT 856 U/L, Alk P 185 U/L], resolving within 6 weeks of stopping).*
- Parys BT, Hamid S, Thomson RG. Severe hepatocellular dysfunction following cyproterone acetate therapy. Br J Urol 1991; 67: 312-3. PubMed PMID: 1827039.
- (3 cases of severe acute hepatocellular injury from cyproterone for prostate cancer; 65, 72 and 83 year old men on treatment for 3-12 months [bilirubin 10.4, 16.4 and 19.1 mg/dL, AST 155, 254 and 377 U/L, Alk P 155, 218 and 252 U/L], resolving with corticosteroid therapy 3 months after stopping in one patient, the other two dying of liver failure 6 and 11 days after presentation).*
- Antoni M, Bourlière M, Toullec J, Maillot A, Botta-Fridlund D, Gauthier A. [Fatal subfulminant hepatitis caused by cyproterone acetate]. Gastroenterol Clin Biol 1991; 15: 772-3. French. PubMed PMID: 1840042.
- (80 year old man developed jaundice 6 months after starting cyproterone for prostate cancer [bilirubin 27.7 mg/dL, ALT 20 times ULN, Alk P 1.2 times ULN], dying of hepatic failure one month after presentation).*
- Ohri SK, Gaer JA, Keane PF. Hepatocellular carcinoma and treatment with cyproterone acetate. Br J Urol 1991; 67: 213. PubMed PMID: 1848454.

- (75 year old man with prostate cancer developed hepatomegaly 18 months after starting cyproterone [bilirubin 2.5 mg/dL, AST 35 U/L, Alk P 240 U/L], liver biopsy showed hepatocellular carcinoma; no risk factors present).*
- Hassler P, Duchêne R. [Hepatotoxicity of cyproterone acetate]. Rev Med Interne 1992; 13: 245. French. PubMed PMID: 1410910.
- (24 year old woman developed abnormal liver tests 3 months after starting cyproterone and estrogens for hirsutism [bilirubin 0.8 mg/dL, ALT 193 U/L, Alk P 594 U/L], resolving within 6 months of stopping both, possibly estrogen related).*
- Drakos PE, Gez E, Catane R. Hepatitis due to cyproterone acetate. Eur J Cancer 1992; 28A: 1931-2. PubMed PMID: 1389539.
- (78 year old man developed jaundice 3 months after starting cyproterone and triptorelin for prostate cancer [bilirubin 18.7 mg/dL, ALT 468 U/L, Alk P 246 U/L], resolving within 3 months of stopping cyproterone).*
- Roila F, Crinò L, Carloni G, Natalini G. Cyproterone acetate: hepatotoxicity and prostatic cancer treatment. Ann Oncol 1993; 4: 701. PubMed PMID: 8241005.
- (74 year old man developed jaundice 11 months after starting cyproterone and goserelin for prostate cancer [bilirubin 8 mg/dL, ALT 26 times ULN, Alk P "slightly increased"], resolving within 3 months of stopping cyproterone).*
- Bressollette L, Dubois A, Carlhant D, Morand C, Mottier D, Riche C. [Fatal hepatitis caused by cyproterone acetate]. Therapie 1994; 49: 153. French. PubMed PMID: 7817350.
- (79 year old man developed jaundice 9 months after starting cyproterone for prostate cancer [bilirubin 30 times ULN, ALT 9 times ULN, Alk P near-normal, prothrombin index 18%], with progressive liver failure and death within 3 days of admission).*
- Watababe S, Yamasaki S, Tanal A, Hibi I, Ad hoc committee on Androcur Users, Honna T. Three cases of hepatocellular carcinoma among cyproterone users. Lancet 1994; 344: 1567. PubMed PMID: 7983963.
- (Three girls treated with cyproterone for 3-9 years for short stature or Turner syndrome developed hepatocellular carcinoma despite absence of chronic liver disease or cirrhosis).*
- Kattan J, Spatz A, Culine S, Terrier-Lacombe MJ, Elias D, Droz JP. Hepatocellular carcinoma during hormonotherapy for prostatic cancer. Am J Clin Oncol 1994; 17: 390-2. PubMed PMID: 8092108.
- (65 year old man with prostate cancer developed a hepatic mass while on triptorelin and 2 months after a 30 day course of cyproterone [liver tests normal] despite normal CT scan 5 months previously, lobectomy showing hepatocellular carcinoma).*
- Hirsch D, Kovatz S, Bernheim J, Shenkman L. Fatal fulminant hepatitis from cyproterone acetate. Isr J Med Sci 1994; 30: 238-40. PubMed PMID: 8181926.
- (92 year old man developed jaundice 4 months after starting cyproterone for prostate cancer [bilirubin 20 mg/dL, ALT 1080 U/L, Alk P 436 U/L, prothrombin index 34%], developing progressive liver failure despite prompt stopping of the drug and corticosteroid therapy, dying 24 days after admission).*
- Castellani P, Bernardini D, Renou C, Zamora C, Portal I, Gauthier A, Botta-Fridlund D. [Fatal sub-fulminant hepatitis caused by cyproterone acetate. A new case]. Gastroenterol Clin Biol 1996; 20: 915-6. French. PubMed PMID: 8991155.
- (78 year old man developed jaundice 3 months after starting cyproterone for prostate cancer [bilirubin 25.1 mg/dL, ALT 15 times ULN, Alk P normal, prothrombin index 21%], dying with hepatic failure within 12 days of admission).*

Rüdiger T, Beckmann J, Queisser W. Hepatocellular carcinoma after treatment with cyproterone acetate combined with ethinyloestradiol. *Lancet* 1995; 345 (8947): 452-3. PubMed PMID: 7853970.

*(45 year old woman developed unexplained hepatomegaly having been on estrogens and cyproterone for 14 years, dying of progressive liver tumor 7 months later).*

Pinganaud G, Chaslerie A, Bourdel Marchasson I, Decamps A, Manciet G, Emeriau JP. Cyproterone-induced hepatotoxicity. *Ann Pharmacother* 1995; 29: 634. PubMed PMID: 7663042.

*(2 patients with fatal liver injury attributed to cyproterone: 87 and 78 year old men developed fatigue 4 and 12 months after starting cyproterone for prostate cancer [bilirubin 4.9 mg/dL and normal, ALT 100 and 86 U/L, GGT 584 and 252 U/L], both dying 3 weeks later of hepatic failure).*

Murphy BJ, Collins BJ. Severe hepatitis and liver failure induced by cyproterone acetate. *Aust N Z J Med* 1996; 26: 724. PubMed PMID: 8958378.

*(73 year old man developed jaundice 3 months after starting cyproterone for prostate cancer [bilirubin 11.3 mg/dL, AST 763, Alk P 229 U/L, INR 1.8], developing ascites and bacterial peritonitis, but eventually recovering several months after stopping).*

Rabe T, Feldmann K, Heinemann L, Runnebaum B. Cyproterone acetate: is it hepato- or genotoxic? *Drug Saf* 1996; 14: 25-38. PubMed PMID: 8713486.

*(Review of the hepatic adverse events of cyproterone; concluded that there was no correlation between the duration of cyproterone use and liver enzyme elevations, but many isolated cases of liver injury have been reported, particularly with the high doses that are used with prostate cancer).*

Hinkel A, Berges RR, Pannek J, Schulze H, Senge T. Cyproterone acetate in the treatment of advanced prostatic cancer: retrospective analysis of liver toxicity in the long-term follow-up of 89 patients. *Eur Urol* 1996; 30: 464-70. PubMed PMID: 8977068.

*(Among 89 men with prostate cancer treated with cyproterone for up to 12 years, transient liver test abnormalities occurred in 22 [28%], but often from another cause and no patient required drug discontinuation for liver disease or developed clinically apparent liver injury or liver cancer).*

Ruiz-Rebollo ML, Polo F, Palenzuela R, Moretó M [Severe acute hepatitis due to cyproterone]. *Gastroenterol Hepatol* 1997; 20: 385. Spanish. PubMed PMID: 9377242.

*(64 year old man developed jaundice 6 months after starting cyproterone for prostate cancer [bilirubin 11 mg/dL, ALT 1858 U/L, Alk P normal, prothrombin index 60%], resolving almost completely within 2 months of stopping).*

Lombardi A, Ferrazza P, Castaldi F, Covotta L, Tesoriere A, Urbano V, Midiri G. [Acute hepatic necrosis in a patient treated with cyproterone acetate]. *G Chir* 1998; 19: 161-3. Italian. PubMed PMID: 9628065.

*(84 year old man developed jaundice after starting cyproterone for prostate cancer [bilirubin 29.5 mg/dL, ALT 746 U/L, Alk P 152 U/L], dying 9 days after presentation).*

Friedman G, Lamoureux E, Sherker AH. Fatal fulminant hepatic failure due to cyproterone acetate. *Dig Dis Sci* 1999; 44: 1362-3. PubMed PMID: 10489919.

*(Two men [ages 66 and 81 years] with prostate cancer developed jaundice 5 and 6 months after starting cyproterone [bilirubin 12.2 and 30.2 mg/dL, ALT 702 and 395 U/L, Alk P 144 and 376 U/L], with progressive liver failure despite stopping drug promptly, leading to death 36 and 20 days later).*

Pu YS, Liu CM, Kao JH, Chen J, Lai MK. Antiandrogen hepatotoxicity in patients with chronic viral hepatitis. *Eur Urol* 1999; 36: 293-7. PubMed PMID: 10473987.



- (Among 121 men with prostate cancer who were treated with flutamide or cyproterone 22 [18%] had ALT elevations during therapy, of whom 13 [59%] had either HBsAg or anti-HCV, a higher rate than would be expected, suggesting that hepatotoxicity might be more frequent in patients with hepatitis B or C, although the entire cohort was not tested for viral markers).*
- Garty BZ, Dinari G, Gellvan A, Kauli R. Cirrhosis in a child with hypothalamic syndrome and central precocious puberty treated with cyproterone acetate. *Eur J Pediatr* 1999; 158: 367-70. PubMed PMID: 10333116.
- (Boy with hypothalamic syndrome and precocious puberty was treated with cyproterone from age 5 to 10 and then found to have cirrhosis at age 13 [bilirubin normal, ALT 49 U/L, Alk P normal], dying of sepsis and multiorgan failure one year later).*
- Laron Z, Kauli R. Experience with cyproterone acetate in the treatment of precocious puberty. *J Pediatr Endocrinol Metab* 2000 Jul; 13 Suppl 1: 805-10. PubMed PMID: 10969925.
- (Summary of long term experience using cyproterone in 26 girls with precocious puberty states "we found no alterations in liver function tests, checked routinely").*
- Giordano N, Nardi P, Santacroce C, Geraci S, Gennari C. Acute hepatitis induced by cyproterone acetate. *Ann Pharmacother* 2001; 35: 1053-5. PubMed PMID: 11573856.
- (87 year old man with prostate cancer developed jaundice 7 months after starting cyproterone [bilirubin 24.4 mg/dL, ALT 484 U/L, Alk P 91 U/L, prothrombin index 61%], resolving within a month of stopping with corticosteroid therapy).*
- Lin AD, Chen KK, Lin AT, Chang YH, Wu HH, Kuo JY, Huang WJ, et al. Antiandrogen-associated hepatotoxicity in the management of advanced prostate cancer. *J Chin Med Assoc* 2003; 66 (12): 735-40. PubMed PMID: 15015823.
- (Retrospective review of 229 patients with prostate cancer treated with flutamide or cyproterone and a GnRH agonist, orchiectomy or radiotherapy with regular monitoring of ALT levels; ALT above 2 times ULN occurred in 15% on flutamide and 9.5% on cyproterone; ALT above 6 times ULN in 5% on flutamide and 4% on cyproterone; no deaths, but a few subjects had jaundice).*
- Thole Z, Manso G, Salgueiro E, Revuelta P, Hidalgo A. Hepatotoxicity induced by antiandrogens: a review of the literature. *Urol Int* 2004; 73: 289-95. PubMed PMID: 15604569.
- (Systematic review of the literature from the Spanish pharmacovigilance group found 21 reports of hepatotoxicity of cyproterone, 46 flutamide, 4 nilutamide and 1 bicalutamide as well as 6 cases of hepatocellular carcinoma linked to cyproterone therapy).*
- Manolakopoulos S, Bethanis S, Armonis A, Economou M, Avgerinos A, Tzourmakliotis D. Toxic hepatitis after sequential administration of flutamide and cyproterone acetate. *Dig Dis Sci* 2004; 49: 462-5. PubMed PMID: 15139499.
- (76 year old man with prostate cancer developed jaundice 6 months after starting flutamide [bilirubin 23.6 mg/dL, ALT 164 U/L, Alk P 132 U/L], which recurred 5 months after switching to cyproterone [bilirubin 6.8 mg/dL, ALT 162 U/L, Alk P 302 U/L], with similar time to recovery).*
- Savidou I, Deutsch M, Soultati AS, Koudouras D, Kafiri G, Dourakis SP. Hepatotoxicity induced by cyproterone acetate: a report of three cases. *World J Gastroenterol* 2006; 12: 7551-5. PubMed PMID: 17167851.
- (3 men, ages 78-83 years, with prostate cancer developed jaundice 3 to 12 months after starting cyproterone [bilirubin 10.1-30 mg/dL, ALT 283-535 U/L, Alk P 300-380 U/L, INR 1.2-2.2]; two had preexisting cirrhosis and one died).*

- Manso G, Thole Z, Salgueiro E, Revuelta P, Hidalgo A. Spontaneous reporting of hepatotoxicity associated with antiandrogens: data from the Spanish pharmacovigilance system. *Pharmacoepidemiol Drug Saf* 2006; 15: 253-9. PubMed PMID: 16294367.
- (Among 508 adverse events reported to the Spanish Pharmacovigilance registry between 1987 and 2004, 114 were for liver injury, 15 due to cyproterone, mean latency 29 weeks, recovery 3.5 weeks, no deaths).*
- Björnsson E, Olsson R. Suspected drug-induced liver fatalities reported to the WHO database. *Dig Liver Dis* 2006; 38: 33-8. PubMed PMID: 16025496.
- (Survey of drug induced liver fatalities reported to WHO database between 1968-2003 revealed 4690 reports; flutamide ranked 11th with a total of 59 cases, but cyproterone was not among the top 20 listed causes).*
- Miquel M, Soler A, Vaqué A, Ojanguren I, Costa J, Planas R. Suspected cross-hepatotoxicity of flutamide and cyproterone acetate. *Liver Int* 2007; 27: 1144-7. PubMed PMID: 17845544.
- (78 year old man with prostate cancer developed jaundice 3 months after starting flutamide [bilirubin 20.9 mg/dL, ALT 262 U/L, Alk P 104 U/L], resolving upon stopping, but recurring within 2 months of switching to cyproterone [bilirubin 15.6 mg/dL, ALT 373 U/L, Alk P 70 U/L], with similar course of recovery).*
- Reuben A, Koch DG, Lee WM; Acute Liver Failure Study Group. Drug-induced acute liver failure: results of a U.S. multicenter, prospective study. *Hepatology* 2010; 52: 2065-76. [PubMed Citation](#)
- (Among 1198 patients with acute liver failure enrolled in a US prospective study between 1998 and 2007, 133 were attributed to drug induced liver injury, but none were attributed to antiandrogen therapies).*
- Hsu YC, Tai DI. Unusually high alanine aminotransferase to aspartate aminotransferase ratio in a patient with cyproterone-induced icteric hepatitis. *Chang Gung Med J* 2011; 34 (6 Suppl): 34-8. PubMed PMID: 22490456.
- (70 year old man developed jaundice 3 months after starting cyproterone for prostate cancer [bilirubin 14 mg/dL, ALT 1311 U/L, AST 82 U/L, protime 15 sec], which recurred within 2 months of reexposure 1 year later [bilirubin 6.2 mg/dL, ALT 399 U/L, AST 268 U/L, Alk P 115 U/L], imaging showing cirrhosis with ascites; death from multiorgan failure one month later).*
- Abenavoli L, Milic N, Beaugrand M. Severe hepatitis induced by cyproterone acetate: role of corticosteroids. A case report. *Ann Hepatol* 2013; 12: 152-5. PubMed PMID: 23293208.
- (66 year old man with prostate cancer developed jaundice 4 months after starting cyproterone [bilirubin 22.3 mg/dL, ALT 2044 U/L, Alk P 223 U/L], with a prolonged course, corticosteroid therapy, but ultimate recovery).*
- Björnsson ES, Bergmann OM, Björnsson HK, Kvaran RB, Olafsson S. Incidence, presentation and outcomes in patients with drug-induced liver injury in the general population of Iceland. *Gastroenterology* 2013; 144: 1419-25. PubMed PMID: 23419359.
- (In a population based study of drug induced liver injury from Iceland, 96 cases were identified over a 2 year period, but none of the 96 were attributed to cyproterone).*
- Kim JH, Yoo BW, Yang WJ. Hepatic failure induced by cyproterone acetate: A case report and literature review. *Can Urol Assoc J* 2014; 8 (5-6): E458-61. PubMed PMID: 25024808.
- (87 year old man developed jaundice 3 months after starting cyproterone and a GnRH agonist for prostate cancer [bilirubin 10.6 mg/dL, ALT 223 U/L, GGT 85 U/L, INR 2.4], progressing to hepatic failure and death 20 days after presentation; the authors also summarize results from 15 fatal cases in literature).*
- Vodička M, Sálek T, Röderová E, Cerný D. Hepatotoxicity induced by cyproterone acetate in the prostate carcinoma treatment - a case report]. *Klin Onkol* 2013; 26 (1): 47-8. Czech. PubMed PMID: 23528173.

*(75 year old man with prostate cancer developed jaundice 9 months after starting cyproterone [bilirubin 10.3 mg/dL, ALT 994 U/L, Alk P 193 U/L, GGT 1128 U/L, INR 1.23]).*

Hernández N, Bessone F, Sánchez A, di Pace M, Brahm J, Zapata R, A Chirino R, et al. Profile of idiosyncratic drug induced liver injury in Latin America. An analysis of published reports. *Ann Hepatol* 2014; 13: 231-9. PubMed PMID: 24552865.

*(Systematic review of literature of drug induced liver injury in Latin American countries published from 1996 to 2012 identified 176 cases, the most common implicated agents being nimesulide [n=53: 30%], cyproterone [n=18], nitrofurantoin [n=17], antituberculosis drugs [n=13] and flutamide [n=12: 7%]).*

Chalasanani N, Bonkovsky HL, Fontana R, Lee W, Stolz A, Talwalkar J, Reddy KR, et al.; United States Drug Induced Liver Injury Network. Features and outcomes of 899 patients with drug-induced liver injury: The DILIN Prospective Study. *Gastroenterology* 2015; 148: 1340-52. PubMed PMID: 25754159.

*(Among 899 cases of drug induced liver injury enrolled in a US prospective study between 2004 and 2013, one was attributed to bicalutamide, but none to other antiandrogens such as flutamide, nilutamide and cyproterone).*

Bessone F, Isabel Lucena M, Roma MG, Stephens C, Medina-Cáliz I, Frider B, Tsariktsian G, et al. Cyproterone acetate induces a wide spectrum of acute liver damage including corticosteroid-responsive hepatitis: report of 22 cases. *Liver Int* 2016; 36 (2): 302-10. *(Among 22 cases of cyproterone hepatotoxicity enrolled in Spanish and Latin American Pharmacovigilance Registries [Spain 3, Argentina 17, Uruguay 2] between 1993 and 2013, all were in men with prostate cancer, ages 54 to 83 [mean=70] years, arising 33 to 425 [mean=168] days after starting cyproterone [bilirubin 1.7 to 40 mg/dL, ALT 5.7 to 58.5 times ULN, Alk P 0.2 to 2.9 times ULN]; all except one had jaundice and 3 died; several appeared to benefit from corticosteroid therapy).* PubMed PMID: 26104271.