

Daptomycin

Updated: December 4, 2017.

OVERVIEW

Introduction

Daptomycin is an intravenously administered, broad spectrum antibiotic used to treat complex skin and tissue infections, endocarditis and bacteremia. Daptomycin is associated with a low to modest rate of serum enzyme elevations during therapy, but is a very rare cause of clinically apparent liver injury.

Background

Daptomycin (dap" toe mye' sin) is a cyclic lipopeptide antibiotic that is poorly absorbed orally and must be given intravenously. Daptomycin appears to act by binding to bacterial membranes causing their depolarization and disruption and cell death. Daptomycin has been shown to be highly effective in treating severe gram-positive bacterial infections, including methicillin resistant *Staphylococcal aureus* (MRSA) and vancomycin resistant enterococcal (VRE) infections, and bacterial resistance is rare. Because of its value in treating multidrug resistant infections, daptomycin is usually limited for use in complicated infections in the hospital setting. Daptomycin was approved for use in 2006 and current indications include complicated skin and skin structure infections and severe bacteremia and endocarditis caused by susceptible organisms. Daptomycin is available in generic forms and under the brand name Cubicin in single use vials of 500 mg. The typical dose is 4 to 6 mg/kg once daily for 7 to 28 days, depending upon the type of infection and organism. Side effects may include restlessness, dizziness, headache, fever, abdominal pain, nausea, diarrhea and cough. Serum creatine kinase (CK) levels are often raised during intravenous daptomycin therapy, and many instances symptomatic myositis and of rhabdomyolysis have been reported, particularly with higher doses of therapy and in patients on concurrent statin medications. Rare complications include hypersensitivity reactions and interstitial pneumonitis.

Hepatotoxicity

Elevations in serum aminotransferase levels occur in 2% to 6% of patients receiving daptomycin, rates that are minimally higher than with placebo or comparator drugs. The elevations are generally mild-to-moderate, asymptomatic and self-limited, frequently resolving without discontinuation or even interruption of therapy. Isolated case reports of possible liver injury from daptomycin have been reported, but serum bilirubin was normal in most cases, and the serum aminotransferase elevations were mild-to-moderate and typically accompanied by severe muscle injury with marked CK elevations. Such cases without jaundice or alkaline phosphatase elevations are more likely due to muscle rather than liver injury. Nevertheless, a few case reports of mild jaundice with a hepatocellular pattern of serum enzyme elevations and normal CK levels has been published. The latency to onset was 5 weeks, immunoallergic and autoimmune features were not present, and

resolution was slow with mild abnormalities still present 6 weeks later. Thus, clinically apparent liver injury from daptomycin probably occurs, but is quite rare.

Likelihood score: C (probable cause of clinically apparent liver injury).

Mechanism of Liver Injury

The mild-to-moderate serum aminotransferase elevations that occur during daptomycin therapy may represent muscle rather than liver injury and are likely due to direct toxicity to muscle. The rare instances of jaundice and hepatitis with daptomycin therapy probably represent idiosyncratic liver injury.

Outcome and Management

The severity of the liver injury linked to daptomycin therapy is usually mild and self-limited, and dose modification or discontinuation is rarely necessary. No instances of acute liver failure, chronic hepatitis or vanishing bile duct syndrome have been attributed to daptomycin therapy. The outcome of reexposure to daptomycin after liver or muscle injury has not been reported. Also, there is no information on cross sensitivity between daptomycin and other peptide antibiotics (such as the glycopeptides antibiotics, vancomycin and teicoplanin), but there is little reason to believe that such sensitivity exists.

Drug Class: [Antiinfective Agents](#)

CASE REPORT

Case 1. Mild liver injury arising during daptomycin therapy.

[Modified from: Abraham G, Finkelberg D, Spooner LM. Daptomycin-induced acute renal and hepatic toxicity without rhabdomyolysis. *Ann Pharmacother* 2008; 42: 719-21. [PubMed Citation](#)]

A 35 year old man with paraplegia and a decubitus ulcer with a methicillin resistant *Staphylococcus aureus* infection as well as a urinary tract infection with vancomycin resistant enterococci was treated at home with intravenous daptomycin in a dose of 4 mg/kg once daily. After 5 weeks of this treatment, he developed nausea and fatigue and was found to have abnormal liver tests. He had no history of liver disease and denied alcohol abuse and exposures to viral hepatitis. He had a history of drug allergy to penicillin (rash). Other medications included clonazepam for sleep, sertraline for depression, hydromorphone for pain, prochlorperazine for nausea, ferrous sulfate and vitamin C, all of which he had taken for more than a year. On examination, he was anicteric, afebrile and without findings indicative of acute or chronic liver disease. Laboratory tests showed bilirubin 2.0 mg/dL, ALT 8050 U/L, AST 6020 U/L, alkaline phosphatase 370 U/L, INR 1.2 and CK 111 U/L. Daptomycin was stopped and vancomycin and ciprofloxacin were begun. Tests for hepatitis A, B and C were negative and computed tomography of the abdomen showed no biliary dilatation or hepatic masses. Blood cultures grew *Stenotrophomonas maltophilia* which was sensitive to ciprofloxacin. Vancomycin was discontinued and he remained afebrile. Liver tests improved slowly and were near-normal six weeks later (Table).

Key Points

Medication:	Daptomycin (325 mg daily)
Pattern:	Hepatocellular (R=33)
Severity:	3+ (bilirubin elevation and hospitalization)
Latency:	5 weeks
Recovery:	Almost complete at 6 weeks
Other medications:	Clonazepam, sertraline, hydromorphone, prochlorperazine, ferrous sulfate, vitamin C

Laboratory Values

Time After Starting	Time After Stopping	ALT (U/L)	Alk P (U/L)	Bilirubin (mg/dL)	Other
2 weeks	Pre	20			
5 weeks	0	8050	370	2.0	Admission
6 weeks	1 week	819			Discharge
12 weeks	7 weeks	81			AST 51
Normal Values		<40	<130	<1.2	

Comment

The height of the serum aminotransferase levels and rapid fall with stopping daptomycin suggests a direct hepatic toxicity; the phenotype of acute hepatic necrosis. This pattern can also occur after an acute ischemic injury to the liver or acetaminophen (or cocaine) overdose. None of these possibilities seemed reasonable in this case report.

PRODUCT INFORMATION

REPRESENTATIVE TRADE NAMES

Daptomycin – Generic, Cubicin®

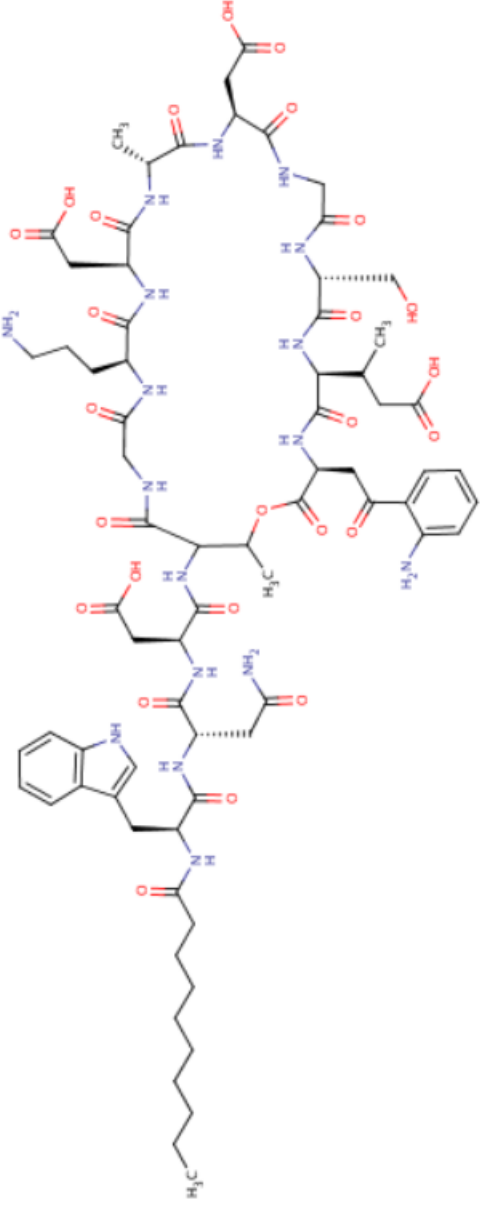
DRUG CLASS

Antiinfective Agents

COMPLETE LABELING

Product labeling at DailyMed, National Library of Medicine, NIH

CHEMICAL FORMULA AND STRUCTURE

DRUG	CAS REGISTRY NUMBER	MOLECULAR FORMULA	STRUCTURE
Daptomycin	103060-53-3	C72-H101-N17-O26	 <p>The image displays the chemical structure of Daptomycin, a cyclic lipopeptide antibiotic. It features a 14-membered macrocyclic ring composed of amino acid residues, including L-phenylalanine, L-lysine, L-threonine, L-valine, L-isoleucine, L-methionine, L-proline, L-tryptophan, L-phenylglycine, L-homoserine, L-threonine, L-valine, L-isoleucine, and L-methionine. The ring is substituted with a long-chain fatty acid (undecanoic acid) and a side chain containing a tryptophan residue and a methyl group. The structure is shown in a 3D perspective view with various atoms and bonds highlighted in red and blue.</p>

ANNOTATED BIBLIOGRAPHY

References updated: 04 December 2017

Abbreviations: MRSA, methicillin resistant *Staphylococcus aureus*

Zimmerman HJ. Hepatotoxic effects of oncotherapeutic and immunosuppressive agents. In, Zimmerman HJ. Hepatotoxicity: the adverse effects of drugs and other chemicals on the liver. 2nd ed. Philadelphia: Lippincott, 1999, pp. 673-708.

(Expert review of hepatotoxicity published in 1999, does not discuss daptomycin).

Moseley RH. Daptomycin. Hepatotoxicity of antimicrobial and antifungal agents. In, Kaplowitz N, DeLeve LD, eds. Drug-induced liver disease. 3rd ed. Amsterdam: Elsevier, 2013, pp. 470.

(Expert review of antibiotic induced liver injury, mentions rare reports of asymptomatic serum enzyme elevations in patients receiving daptomycin).

MacDougall C, Chambers HF. Daptomycin. Protein synthesis inhibitors and miscellaneous antibacterial agents. In, Brunton LL, Chabner BA, Knollman BC, eds. Goodman & Gilman's the pharmacological basis of therapeutics. 12th ed. New York: McGraw-Hill, 2011, pp. 1542-3.

(Textbook of pharmacology and therapeutics; daptomycin is a cyclic lipopeptide antibiotic that was discovered 25 years ago, but developed clinically more recently because of the growing need for antibiotics effective against multidrug resistant bacteria).

Veligandla SR, Louie KR, Malesker MA, Smith PW. Muscle pain associated with daptomycin. Ann Pharmacother 2004; 38: 1860-2. PubMed PMID: 15367725.

(26 year old woman with lupus erythematosus developed muscle pains 7 days after starting daptomycin for MRSA bacteremia [CK rising from 7 to 492 U/L], resolving within 3 days of stopping daptomycin).

Papadopoulos S, Ball AM, Liewer SE, Martin CA, Winstead PS, Murphy BS. Rhabdomyolysis during therapy with daptomycin. Clin Infect Dis 2006; 42: e108-10. PubMed PMID: 16705566.

(45 year old woman with refractory leukemia on chemotherapy developed rhabdomyolysis 9 days after starting daptomycin therapy for a vancomycin resistant enterococcal infection [CK 108 rising to 5350 U/L, urine myoglobin 47,166 ng/mL], with multiorgan failure and death 10 days after stopping daptomycin).

Echevarria K, Datta P, Cadena J, Lewis JS 2nd. Severe myopathy and possible hepatotoxicity related to daptomycin. J Antimicrob Chemother 2005; 55: 599-600. PubMed PMID: 15743894.

(52 year old man with hepatitis C and osteomyelitis developed rash on vancomycin, was switched to daptomycin and 9 days later developed muscle weakness [CK 20,771 U/L, ALT 48 U/L, AST 239 U/L, Alk P 118 U/L] without jaundice, enzymes falling to normal within 2 weeks of stopping).

Kazory A, Dibadj K, Weiner ID. Rhabdomyolysis and acute renal failure in a patient treated with daptomycin. J Antimicrob Chemother 2006; 57: 578-9. PubMed PMID: 16410267.

(53 year old woman with osteomyelitis developed muscle weakness 10 days after starting intravenous daptomycin [CK 21,243 U/L, ALT 219 U/L, AST 375 U/L, bilirubin and Alk P not given], with resolution on stopping).

Fowler VG Jr, Boucher HW, Corey GR, Abrutyn E, Karchmer AW, Rupp ME, Levine DP, et al.; S. aureus Endocarditis and Bacteremia Study Group. Daptomycin versus standard therapy for bacteremia and endocarditis caused by *Staphylococcus aureus*. N Engl J Med 2006; 355: 653-65. PubMed PMID: 16914701.

(In a controlled trial of daptomycin vs standard antibiotic therapy in 135 patients with Staphylococcus aureus bacteremia, CK elevations above 500 U/L were more frequent with daptomycin [9.5% vs 1.5%], while renal dysfunction was less frequent [11% vs 26%]; no mention of hepatotoxicity or ALT elevations).

Patel SJ, Samo TC, Suki WN. Early-onset rhabdomyolysis related to daptomycin use. *Int J Antimicrob Agents* 2007; 30: 472-4. PubMed PMID: 17804204.

(68 year old woman with renal insufficiency, polymyalgia rheumatica, recurrent cholangitis and enterococcal sepsis developed severe muscle weakness and pain 4 days after starting daptomycin [CK 25,234 U/L, ALT 332 U/L, AST 1155 U/L], resolving within 10 days of stopping).

Abraham G, Finkelberg D, Spooner LM. Daptomycin-induced acute renal and hepatic toxicity without rhabdomyolysis. *Ann Pharmacother* 2008; 42: 719-21. PubMed PMID: 18381844.

(35 year old man developed fatigue and nausea 5 weeks after starting intravenous daptomycin for osteomyelitis [bilirubin 2.0 mg/dL, ALT 6020 U/L, Alk P 370 U/L, CK 111 U/L, creatinine 2.9 mg/dL, INR 1.2], with almost complete resolution 6 weeks after switching to vancomycin: Case 1).

Chalasan N, Fontana RJ, Bonkovsky HL, Watkins PB, Davern T, Serrano J, Yang H, Rochon J; Drug Induced Liver Injury Network(DILIN). Causes, clinical features, and outcomes from a prospective study of drug-induced liver injury in the United States. *Gastroenterology* 2008; 135: 1924-34. PubMed PMID: 19132805.

(Among 300 cases of drug induced liver disease in the US collected from 2004 to 2008, none were attributed to daptomycin).

Odero RO, Cleveland KO, Gelfand MS. Rhabdomyolysis and acute renal failure associated with the co-administration of daptomycin and an HMG-CoA reductase inhibitor. *J Antimicrob Chemother* 2009; 63: 1299-300. PubMed PMID: 19346518.

(A patient of undisclosed age and gender on simvastatin [80 mg daily] developed muscle pains and weakness 16 days after starting daptomycin for suspected septicemia [CK 8995 U/L and renal insufficiency], resolving within 7 days of stopping).

Crompton JA, North DS, McConnell SA, Lamp KC. Safety and efficacy of daptomycin in the treatment of osteomyelitis: results from the CORE Registry. *J Chemother* 2009; 21: 414-20. PubMed PMID: 19622460.

(Among 327 patients treated with daptomycin for 1 to 210 days for osteomyelitis, CK elevations occurred in 7% of patients, but only 2 had rhabdomyolysis and another patient had "liver function test abnormalities", but no details given).

Figuroa DA, Mangini E, Amodio-Groton M, Vardianos B, Melchert A, Fana C, Wehbeh W, et al. Safety of high-dose intravenous daptomycin treatment: three-year cumulative experience in a clinical program. *Clin Infect Dis* 2009; 49: 177-80. PubMed PMID: 19500039.

(Among 61 patients with complicated infections treated with daptomycin, only 3 had symptomatic CK elevations [above 1000 U/L], all of which resolved with stopping; no mention of ALT elevations or hepatotoxicity).

Kullar R, Davis SL, Levine DP, Zhao JJ, Crank CW, Segreti J, Sakoulas G, et al. High-dose daptomycin for treatment of complicated gram-positive infections: a large, multicenter, retrospective study. *Pharmacotherapy* 2011; 31: 527-36. PubMed PMID: 21923436.

(Among 250 US patients who received daptomycin [> 8 mg/kg/day] for complicated infections, 16 [6%] had CK elevations above 100 U/L, but all were asymptomatic; no mention of ALT elevations or hepatotoxicity).

Gonzalez-Ruiz A, Beiras-Fernandez A, Lehmkuhl H, Seaton RA, Loeffler J, Chaves RL. Clinical experience with daptomycin in Europe: the first 2.5 years. *J Antimicrob Chemother* 2011; 66: 912-9. PubMed PMID: 21393205.

(Among 1127 patients treated with daptomycin for various infections [average 10 days], CK elevations arose in 26%, but were usually mild, transient and asymptomatic, being symptomatic and requiring discontinuation in only one patient who had pre-existing renal insufficiency).

Byren I, Rege S, Campanaro E, Yankelev S, Anastasiou D, Kuropatkin G, Evans R. Randomized controlled trial of the safety and efficacy of Daptomycin versus standard-of-care therapy for management of patients with osteomyelitis associated with prosthetic devices undergoing two-stage revision arthroplasty. *Antimicrob Agents Chemother* 2012; 56: 5626-32. PubMed PMID: 22908174.

(Among 49 patients treated with daptomycin for 6 weeks for osteomyelitis, 2 [4%] developed rhabdomyolysis and 4 [8%] discontinued therapy early because of CK elevations).

Lai CC, Sheng WH, Wang JT, Liao CH, Ho MW, Chen CJ, Chen DL, et al. Safety and efficacy of daptomycin for the treatment of hospitalized adult patients in Taiwan with severe staphylococcal infections. *J Microbiol Immunol Infect* 2012; 45: 52-7. PubMed PMID: 22153759.

(Among 52 Taiwanese adults treated with daptomycin, CK elevations occurred in 5 [10%] and ALT elevations in 2 [4%], but most were mild).

Kwon H, Lee SH, Kim SE, Lee JH, Jee YK, Kang HR, Park BJ, et al. Spontaneously reported hepatic adverse drug events in Korea: multicenter study. *J Korean Med Sci* 2012; 27: 268-73. PubMed PMID: 22379337.

(Summary of 2 years of adverse event reporting in Korea; of 9360 reports, 567 were liver related, but none were attributed to daptomycin).

Colomba C, Rubino R, Siracusa L, Mazzola G, Titone L. Rhabdomyolysis associated with the co-administration of daptomycin and pegylated interferon α -2b and ribavirin in a patient with hepatitis C. *J Antimicrob Chemother* 2012; 67: 249-50. PubMed PMID: 21965434.

(Patient with chronic hepatitis C receiving peginterferon and ribavirin, was receiving antibiotics for a gluteal abscess and developed muscle aches and fever after a second dose of daptomycin [CPK 12933 U/L rising to 45257 U/L, ALT 371 U/L, ALT 67 U/L, Alk P and bilirubin not given], resolving within 10 days of stopping daptomycin).

Kullar R, Casapao AM, Davis SL, Levine DP, Zhao JJ, Crank CW, Segreti J, et al. A multicentre evaluation of the effectiveness and safety of high-dose daptomycin for the treatment of infective endocarditis. *J Antimicrob Chemother* 2013; 68: 2921-6. PubMed PMID: 23928022.

(Among 70 adults treated with daptomycin for endocarditis, none developed a serious adverse event attributable to the antibiotic).

Bookstaver PB, Bland CM, Qureshi ZP, Faulkner-Fennell CM, Sheldon MA, Caulder CR, Hartis C; SERGE-45 Investigators. Safety and effectiveness of daptomycin across a hospitalized obese population: results of a multicenter investigation in the southeastern United States. *Pharmacotherapy* 2013; 33: 1322-30. PubMed PMID: 23712701.

(Among 126 obese patients treated with daptomycin for an average of 20 days, adverse events included CK elevations [>500 U/L] in 14% of patients; no mention of ALT elevations or hepatotoxicity).

Casapao AM, Kullar R, Davis SL, Levine DP, Zhao JJ, Potoski BA, Goff DA, et al. Multicenter study of high-dose daptomycin for treatment of enterococcal infections. *Antimicrob Agents Chemother* 2013; 57: 4190-6. PubMed PMID: 23774437.

(Among 245 patients with enterococcal infections treated with high doses of daptomycin, 7 [3%] had CK elevations, but none were above 10 times ULN and all were asymptomatic; no mention of hepatotoxicity or ALT elevations).

Rege S, Mohr J, Lamp KC, Yoon M, Lindfield KC. Safety of daptomycin in patients completing more than 14 days of therapy: results from the Cubicin® Outcomes Registry and experience. *Int J Antimicrob Agents* 2013; 41: 421-5. PubMed PMID: 23394685.

(Safety analysis in 2263 patients given daptomycin for more than 14 days found only 3 patients with CK elevations and rare instances of nausea and rash; ALT elevations and hepatotoxicity not mentioned).

Lai CC, Sheng WH, Wang JT, Cheng A, Chuang YC, Chen YC, Chang SC. Safety and efficacy of high-dose daptomycin as salvage therapy for severe gram-positive bacterial sepsis in hospitalized adult patients. *BMC Infect Dis* 2013; 13: 66. PubMed PMID: 23379510.

(Among 67 patients with severe infections treated with daptomycin, bone marrow suppression occurred in 70%, abnormal ALT levels in 29% and renal dysfunction in 20% of patients, but the abnormalities were usually due to the underlying illness rather than the antibiotic therapy).

Björnsson ES, Bergmann OM, Björnsson HK, Kvaran RB, Olafsson S. Incidence, presentation and outcomes in patients with drug-induced liver injury in the general population of Iceland. *Gastroenterology* 2013; 144: 1419-25. PubMed PMID: 23419359.

(In a population based study of drug induced liver injury from Iceland, 96 cases were identified over a 2 year period, but none were attributed to daptomycin).

Hernández N, Bessone F, Sánchez A, di Pace M, Brahm J, Zapata R, A Chirino R, et al. Profile of idiosyncratic drug induced liver injury in Latin America. An analysis of published reports. *Ann Hepatol* 2014; 13: 231-9 PubMed PMID: 24552865.

(Systematic review of literature of drug induced liver injury in Latin American countries published from 1996 to 2012 identified 176 cases, but none were attributed to daptomycin).

Bohm N, Makowski C, Machado M, Davie A, Seabrook N, Wheless L, Bevill B, et al. Case report and cohort analysis of drug-induced liver injury associated with daptomycin. *Antimicrob Agents Chemother* 2014; 58: 4902-3. PubMed PMID: 24820087.

(31 year old man with bacterial endocarditis due to MRSA, developing worsening liver tests within 5 days of starting daptomycin [bilirubin 0.6 rising to 1.8 mg/dL, ALT ~250 to 800 U/L, Alk P ~100 to 400 U/L], improving once daptomycin was stopped).

King ST, Walker ED, Cannon CG, Finley RW. Daptomycin-induced rhabdomyolysis and acute liver injury. *Scand J Infect Dis* 2014; 46: 537-40. PubMed PMID: 24801642.

(44 year old African American woman with osteomyelitis developed rhabdomyolysis a few days after starting daptomycin and ciprofloxacin [bilirubin normal, ALT 236 U/L, AST 750 U/L, Alk P 207 U/L, CPK 16710 U/L, creatinine 4.7 mg/dL], resolving within 1-2 months of stopping daptomycin).

Bland CM, Bookstaver PB, Lu ZK, Dunn BL, Rumley KF; Southeastern Research Group Endeavor (SERGE-45). Musculoskeletal safety outcomes of patients receiving daptomycin with HMG-CoA reductase inhibitors. *Antimicrob Agents Chemother* 2014; 58: 5726-31. PubMed PMID: 25022580.

(Among 220 patients treated with daptomycin, the 49 who were also receiving statins were more likely to have muscle pains [6% vs 3%] and DPK elevations above 1000 U/L [10% vs 5%] than those who were not, but the differences were not statistically significant).

Chalasanani N, Bonkovsky HL, Fontana R, Lee W, Stolz A, Talwalkar J, Reddy KR, et al.; United States Drug Induced Liver Injury Network. Features and outcomes of 899 patients with drug-induced liver injury: The DILIN Prospective Study. *Gastroenterology* 2015; 148: 1340-52.e7. PubMed PMID: 25754159.

(Among 899 cases of drug induced liver injury enrolled in a US prospective study between 2004 and 2013, 2 were attributed to daptomycin).

Mo Y, Nehring F, Jung AH, Housman ST. Possible hepatotoxicity associated with daptomycin: a case report and literature review. *J Pharm Pract* 2016; 29: 253-6. PubMed PMID: 26763341.

(49 year old woman with multiple medical problems developed jaundice while being treated for a MRSA infection with daptomycin in a dose of 300 mg intravenously once daily for 3 weeks [bilirubin 5.8 mg/dL, ALT 1449 U/L, Alk P 935 U/L, INR 4.15, CPK 45 U/L], with slow and incomplete recovery after stopping daptomycin).