



U.S. National Library of Medicine
National Center for Biotechnology Information

NLM Citation: Toomes C, Downey L. Familial Exudative Vitreoretinopathy, Autosomal Dominant – RETIRED CHAPTER, FOR HISTORICAL REFERENCE ONLY. 2005 Mar 21 [Updated 2011 Sep 22]. In: Adam MP, Feldman J, Mirzaz GM, et al., editors. GeneReviews® [Internet]. Seattle (WA): University of Washington, Seattle; 1993-2024. **Bookshelf URL:** <https://www.ncbi.nlm.nih.gov/books/>



Familial Exudative Vitreoretinopathy, Autosomal Dominant – RETIRED CHAPTER, FOR HISTORICAL REFERENCE ONLY

Synonym: adFEVR

Carmel Toomes, PhD, BSc¹ and Louise Downey, PhD, BSc, MBChB, FRCOphth²

Created: March 21, 2005; Revised: September 22, 2011.

Summary

NOTE: THIS PUBLICATION HAS BEEN RETIRED. THIS ARCHIVAL VERSION IS FOR HISTORICAL REFERENCE ONLY, AND THE INFORMATION MAY BE OUT OF DATE.

Clinical characteristics

Autosomal dominant familial exudative vitreoretinopathy (adFEVR) is characterized by failure of peripheral retinal vascularization. The visual problems and variable phenotype associated with adFEVR result from secondary complications caused by retinal ischemia. The retinal avascularity is probably present from birth and generates sequelae that stabilize in early adult life or progress in later life. Expressivity may be asymmetric and is highly variable, ranging from mild or asymptomatic to severe (e.g., registered as blind) within the same family.

Diagnosis/testing

The diagnosis of adFEVR is based on a family history compatible with autosomal dominant inheritance and bilateral peripheral retinal avascularity, seen temporally, by indirect ophthalmoscope and scleral indentation, or by fundus fluorescein angiography. Pathogenic variants in one of three genes are known to be associated with adFEVR: *FZD4*, encoding the protein frizzled-4; *LRP5*, encoding low-density lipoprotein receptor-related protein 5; and *TSPAN12*, encoding tetraspanin-12. Pathogenic variants in these genes are responsible for fewer than 50% of adFEVR cases. Another locus, *EVR3*, has been mapped; the gene is not known.

Management

Treatment of manifestations: Prophylactic cryotherapy or argon laser photocoagulation to induce regression of new vessel growth caused by ischemia resulting from retinal avascularity; treatment is similar for retinal holes

Author Affiliations: 1 Royal Society Principal Research Fellow, Honorary Associate Professor, Section of Ophthalmology and Neuroscience, Leeds Institute of Molecular Medicine, University of Leeds, Leeds, United Kingdom; Email: c.toomes@leeds.ac.uk. 2 Consultant in Ophthalmology, Hull Royal Infirmary, Kingston upon Hull, United Kingdom; Email: downeylouise@hotmail.com.

Copyright © 1993-2024, University of Washington, Seattle. GeneReviews is a registered trademark of the University of Washington, Seattle. All rights reserved.

and areas of retinal exudate to prevent retinal detachment; rhegmatogenous retinal detachments produced by retinal traction are repaired surgically using conventional methods and exudative retinal detachments may be stabilized with cryotherapy, but prognosis is guarded for both.

Prevention of secondary complications: Reduced bone density would be expected to benefit from drugs used to treat osteoporosis; however, long-term follow-up data are not yet available.

Surveillance: Regular fundus examination in children to evaluate for neovascularization, traction, or exudate; review of individuals with retinal traction at intervals determined by the clinical findings.

Evaluation of relatives at risk: Fundus examination and fundus fluorescein angiography to identify characteristic lesions to allow early treatment.

Genetic counseling

Autosomal dominant FEVR is inherited in an autosomal dominant manner. Offspring of an affected individual are at a 50% risk of inheriting the pathogenic variant, but many individuals with adFEVR can be asymptomatic because of reduced penetrance. Prenatal testing is possible if the pathogenic variant has been identified in the family.

Diagnosis

Clinical Diagnosis

The diagnosis of autosomal dominant familial exudative vitreoretinopathy (adFEVR) is based on the following:

- Family history compatible with autosomal dominant inheritance
- Bilateral peripheral retinal avascularity (Figure 1)
 - Retinal avascularity is usually seen temporally, but may be missed unless an indirect ophthalmoscope and scleral indentation are used.
 - Retinal vascular changes may be more apparent with fundus fluorescein angiography; one small study has suggested that this method identifies 100% of FEVR cases [Ober et al 1980].

Other retinal abnormalities that support the diagnosis:

- Retinal neovascularization and peripheral brush border anastomoses
- Peripheral fibrovascular mass
- Retinal holes/tears that may be associated with retinal detachment
- Retinal traction (with macular ectopia and/or straightening of vessels at the posterior pole, acute-angle vascular branching) that may be associated with retinal detachment
- Exudation that may be associated with retinal detachment
- Falciform retinal folds

Rare retinal features:

- Retinoschisis
- Giant retinal tears

No characteristic electrophysiologic features have been identified.

Molecular Genetic Testing

Genes. To date, pathogenic variants in one of three genes are known to be associated with adFEVR:

- *FZD4*, encoding the protein frizzled-4 [Robitaille et al 2002]

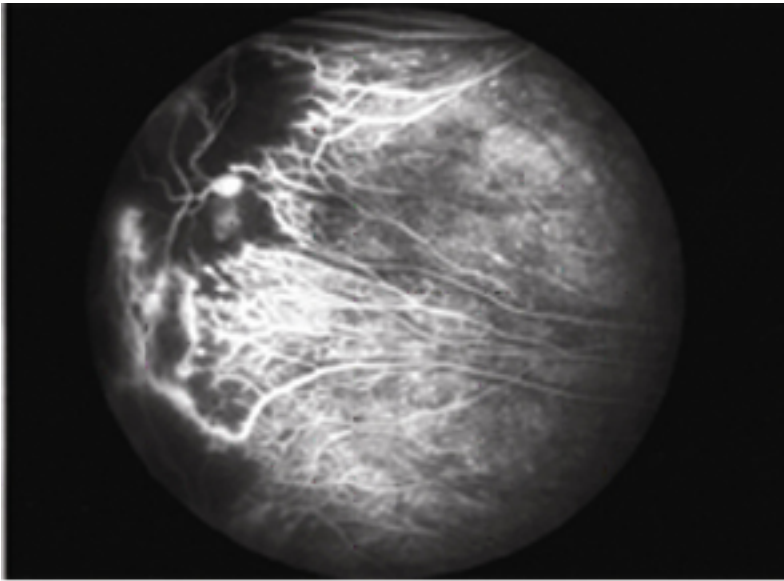


Figure 1A

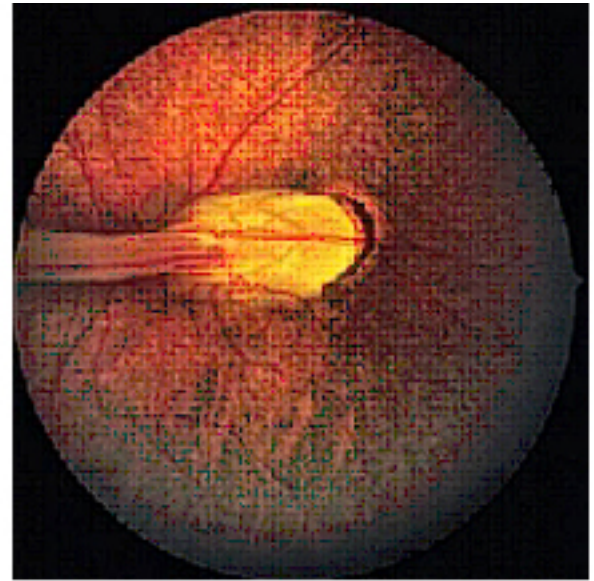


Figure 1B

Figure 1. Classic features of FEVR

1A. Fundus fluorescein angiogram showing the temporal retinal periphery of the right eye of a mildly affected person. Black areas to the left of the photograph represent loss of the normal capillary architecture corresponding to a region of retinal avascularity. Adjacent to this are dilated truncated telangiectatic vessels leaking fluorescein dye (white patches). On the right of the photograph preserved retinal vessels are straightened as they approach the avascular zone.

1B. Fundus photograph of the right eye from an individual with more severe disease. Extensive vitreoretinal traction distorts the retinal vessels emerging from the optic disc, producing a retinal fold extending across the posterior pole to the temporal periphery.

- *LRP5*, encoding low-density lipoprotein receptor-related protein 5 [Toomes et al 2004a]
- *TSPAN12*, encoding tetraspanin-12 [Poulter et al 2010, Nikopoulos et al 2010a]

The proportion of adFEVR attributed to pathogenic variants in each of the genes varies by study:

- ***FZD4***. In the original *FZD4* identification study, pathogenic variants were identified in 40% (2/5) of cases [Robitaille et al 2002]. Most *FZD4* screening studies have found pathogenic variant rates of between 20%-40% although a few studies have found much lower detection rates. Major studies are listed below:
 - 20% (5/24) [Kondo et al 2003]
 - 20% (8/40) [Toomes et al 2004b]
 - 7% (1/13) [MacDonald et al 2005]
 - 3% (2/56) [Qin et al 2005]
 - 3% (3/53) [Nallathambi et al 2006]
 - 14% (9/63) [Drenser et al 2009]
 - 40% (8/20) [Boonstra et al 2009]
 - 31% (5/16) [Nikopoulos et al 2010b]
 - 31% (15/48) [Jia et al 2010]
 - 17% (12/68) [Robitaille et al 2011]
- ***LRP5***. In the original gene identification study, *LRP5* pathogenic variants were responsible for 18% (6/32) of cases [Toomes et al 2004a]. Further studies have found pathogenic variant rates between 10% and 25% (7/56, 2/20 and 4/16) [Qin et al 2005, Boonstra et al 2009, Nikopoulos et al 2010b].

- **TSPAN12.** Two teams identified *TSPAN12*. In the study by Poulter et al pathogenic variants were detected in 10% (7/70) of affected individuals. This figure is likely to be high as the cohort screened in this study had already been screened for pathogenic variants in the other FEVR-related genes [Poulter et al 2010]. In the study by Nikopoulos et al pathogenic variants were detected in 45% (5/11) of individuals. This figure is probably not a true reflection of *TSPAN12* variant frequency as the same pathogenic variant was detected in four of these families, indicating the presence of a founder variant. Only one subsequent study has been undertaken, showing a detection rate of 3% (3/90) [Kondo et al 2011].

Evidence for further locus heterogeneity. A fourth locus for adFEVR, *EVR3* (chromosomal locus 11p12-p13), has been mapped; the gene is not yet known [Downey et al 2001].

Clinical testing

- **FZD4.** Sequence analysis of *FZD4* has identified various types of pathogenic variants (missense, nonsense, small deletions, small insertions); no splice variants have been reported. The pathogenic variants appear to be evenly distributed throughout the gene. No mutational hot spots have been identified.
- **LRP5.** Sequence analysis of *LRP5* has identified many types of pathogenic variants (missense, nonsense, small deletions, small insertions, splicing). The pathogenic variants appear to be evenly distributed throughout the gene. No mutational hot spots have been identified. Each pathogenic variant appears to be family specific.
- **TSPAN12.** Sequence analysis of *TSPAN12* has identified all types of pathogenic variants (missense, nonsense, small deletions, small insertions, splicing). The pathogenic variants appear to be evenly distributed throughout the gene. No mutational hot spots have been identified. Each pathogenic variant appears to be family specific with the exception of c.709G>C (p.Ala237Pro), which is common in the Netherlands.

Table 1. Molecular Genetic Testing Used in Familial Exudative Vitreoretinopathy, Autosomal Dominant

Gene ¹	Proportion of adFEVR Attributed to Pathogenic Variants in Gene	Method	Variants Detected ²
<i>FZD4</i>	4%-40%	Sequence analysis ³	Sequence variants
<i>LRP5</i>	12%-25%		
<i>TSPAN12</i>	3%-10%		

1. See Table A. Genes and Databases for chromosome locus and protein.

2. See Molecular Genetics for information on allelic variants.

3. Sequence analysis detects variants that are benign, likely benign, of uncertain significance, likely pathogenic, or pathogenic.

Pathogenic variants may include small intragenic deletions/insertions and missense, nonsense, and splice site variants; typically, exon or whole-gene deletions/duplications are not detected. For issues to consider in interpretation of sequence analysis results, click [here](#).

Testing Strategy

To confirm/establish the diagnosis in a proband

- The diagnosis of adFEVR is based on a family history compatible with autosomal dominant inheritance and bilateral peripheral retinal avascularity, seen temporally, by indirect ophthalmoscope and scleral indentation, or by fundus fluorescein angiography.
- Molecular genetic testing should begin with sequence analysis of *FZD4*.
- If a pathogenic variant is not identified, sequence analysis of *LRP5* should be performed.
- If a pathogenic variant is not identified, sequence analysis of *TSPAN12* should be performed.
- Because not all genes associated with adFEVR are known, failure to identify a pathogenic variant in *FZD4*, *LRP5* or *TSPAN12* does not rule out the diagnosis.

Clinical Characteristics

Clinical Description

All individuals with autosomal dominant familial exudative vitreoretinopathy (adFEVR) have failure of peripheral retinal vascularization, which by itself usually causes no clinical symptoms. The visual problems and variable phenotype associated with adFEVR result from secondary complications caused by retinal ischemia. This region of retinal avascularity is presumed to be present from birth and initially was thought to generate sequelae that stabilized in early adult life [Ober et al 1980, Tasman et al 1981]. Later studies suggested that disease may progress into later life [Shukla et al 2003].

Autosomal dominant FEVR shows highly variable expressivity and may be markedly asymmetric. The phenotype ranges from mild to severe even within the same family. At the mild end of the spectrum, individuals are asymptomatic; at the severe end, children are registered as blind shortly after birth.

Forty-one percent of the individuals reported by Shukla et al [2003] were at the mild end of the spectrum, in which vision is normal; the only manifestation was an asymptomatic sector of peripheral retinal avascularity. A proportion of individuals demonstrate retinal exudates and retinal traction; about 20% develop rhegmatogenous retinal detachment [Miyakubo et al 1984, van Nouhuys 1991]. Individuals with this severe phenotype often present in the first ten years of life with reduced vision, strabismus, and/or leukocoria.

Individuals with adFEVR and pathogenic variants in *LRP5* have been observed to have reduced bone mass [Toomes et al 2004a, Qin et al 2005]. Preliminary studies indicate that this finding is not seen in individuals with FEVR who have *FZD4* pathogenic variants or those with other forms of FEVR [Qin et al 2005; Toomes, personal communication]. Reduced bone mass is often evident only upon examination and predisposes affected individuals to bone fractures.

Genotype-Phenotype Correlations

Although the phenotype has appeared to be indistinguishable by gene involved, research suggests that individuals with adFEVR who have pathogenic variants within *LRP5* may show signs of osteopenia or osteoporosis on dual x-ray absorptiometry (DXA) [Toomes et al 2004a, Qin et al 2005].

Possible complex inheritance of FEVR. A family with pathogenic variants in both *FZD4* (c.1250G>A; p.Arg417Gln) and *LRP5* (c.1330C>T; p.Arg444Cys) in *cis* configuration on the same chromosome had a more severe phenotype than another unrelated family with the same *FZD4* pathogenic variant only [Qin et al 2005]. Three of four affected family members with both pathogenic variants were blind, whereas three of four affected family members with only the *FZD4* pathogenic variant were asymptomatic. These findings suggest synergy between the *FZD4* pathogenic variant (p.Arg417Gln) and the *LRP5* pathogenic variant (p.Arg444Cys) in the adFEVR phenotype [Qin et al 2005].

In a family with FEVR with an *FZD4* pathogenic variant c.1463G>A (p.Gly488Asp), one affected individual had an *FZD4* sequence variant c.205C>T (p.His69Tyr) in *trans* configuration associated with a more severe ocular phenotype than that in family members with the p.Gly488Asp pathogenic variant only [Kondo et al 2003]. This p.His69Tyr variant was also found in controls and in another family with adFEVR [Omoto et al 2004]. The proband of the family reported by Omoto et al [2004] had a severe phenotype at age six years, while her affected mother and brother had a mild subclinical form of the disease.

Early data suggesting that the **factor V Leiden** pathogenic variant could be modifying the phenotype was not supported by subsequent studies. The cosegregation of an *FZD4* pathogenic variant c.1502delCT and the factor V Leiden variant in a family with a severe adFEVR phenotype suggested that the factor V Leiden variant could be modifying the phenotype [Shastry & Trese 2004]. However, the report of a second family with the same *FZD4*

pathogenic variant and a severe FEVR phenotype but without the Leiden pathogenic variant [Bottomley et al 2006] suggested that the cosegregation of these two variants in the first family was the result of chance alone. This conclusion was further supported by the failure of Bottomley et al [2006] to identify a factor V Leiden variant in 14 additional families with adFEVR.

Penetrance

When using fluorescein angiography to determine clinical status, penetrance is reported to be 100% because all affected individuals have a sector of avascular peripheral retina [Ober et al 1980].

Using examination of the retina with an indirect ophthalmoscope through a dilated pupil to determine clinical status, penetrance is considered to be about 90% [van Nouhuys 1982].

Using reduced vision or other clinical symptoms to determine clinical status, penetrance as low as 10% is reported.

Prevalence

FEVR is often described as a very rare disorder. The prevalence has not been calculated; however, given that molecular testing has shown that as many as 90% of affected individuals may be asymptomatic, it is likely that the frequency of the disorder is underestimated.

FEVR has been described in all ethnic groups.

Genetically Related (Allelic) Disorders

Mutation of *LRP5* is known to cause two autosomal recessive disorders:

- Autosomal recessive FEVR (arFEVR) [Shastry & Trese 1997, de Crecchio et al 1998, Jiao et al 2004]
- Osteoporosis-pseudoglioma syndrome (OPPG) (OMIM 259770) [Gong et al 2001]

Pathogenic missense variants within the first few exons of *LRP5* have been described in the following autosomal dominant disorders characterized by high bone mass:

- High bone mass (OMIM 601884)
- Endosteal hyperostosis (OMIM 144750)
- Osteopetrosis (OMIM 607634) [Boyden et al 2002, Little et al 2002, Van Wesenbeeck et al 2003]

Differential Diagnosis

Familial exudative vitreoretinopathy (FEVR) can be inherited in an autosomal dominant, autosomal recessive, or X-linked manner. The mode of inheritance cannot be distinguished by clinical examination alone.

- **Autosomal dominant FEVR** is the most common of the three modes of inheritance.
- **Autosomal recessive FEVR** is caused by pathogenic variants in *LRP5* [Shastry & Trese 1997, de Crecchio et al 1998, Jiao et al 2004] (see Genetically Related Disorders).
- **X-linked FEVR** is one of the *NDP*-related retinopathies, a range of phenotypes caused by pathogenic variants in *NDP* that includes X-linked FEVR [Chen et al 1993] and Norrie disease.

Incontinentia pigmenti (IP) is a rare X-linked dominant disorder affecting the skin, hair, teeth, nails, and eyes. The eye phenotype is present in one third of affected individuals and resembles FEVR. The other findings of IP distinguish it from FEVR.

Acquired disorders that resemble adFEVR:

- **Retinopathy of prematurity (ROP)**, a sporadic disorder, is the best phenocopy for FEVR. ROP is characterized by failure of the peripheral retinal vasculature to develop, partly as a result of premature birth prior to the completion of retinal vascularization. In some infants with ROP, retinal neovascularization and cicatricial sequelae appear similar to those seen in individuals with FEVR. The history of prematurity and the lack of a family history of FEVR help to distinguish ROP from FEVR.
- **Coats disease, persistent fetal vasculature syndrome, and toxocariasis** have distinctive clinical pictures that may resemble features of the FEVR phenotype, including peripheral retinal fibrovascular mass, retrolental membranes, and exudative detachment.
 - **Coats disease** (OMIM 300216) is characterized by severe retinal telangiectasia. Abnormal vessels can be present throughout the fundus, producing massive exudates that may lead to retinal detachment. It is commonly seen unilaterally in boys.
 - **Persistent fetal vasculature syndrome or persistent hyperplastic primary vitreous (PHPV)** is characterized by retrolental fibrovascular membranes reminiscent of Norrie disease. It is observed in full-term infants and is attributed to failure of regression of the hyaloid vasculature. Involvement is usually unilateral but can be bilateral. Occurrence is usually sporadic but occasionally familial. In contrast to FEVR, the involved eyes are often microphthalmic. Clinical features of abnormal hyaloid artery regression, the physiologic process thought to underlie PHPV, are also seen in some persons with FEVR. In one family with autosomal recessive FEVR, affected family members had a tuft of gliotic tissue at the disc (Bergmeister's papillae) or central vitreous opacity extending from the posterior pole to the lens suggestive of a persistent hyaloid artery [Downey et al 2006].
 - **Toxocariasis** is an acquired, usually unilateral, infestation with the round-worm *Toxocara canis*. In one form, a peripheral granulomatous mass develops. Retinal traction may ensue, forming a retinal fold. The uveitis that can be associated with toxocariasis is not a feature of FEVR.

Management

Evaluations Following Initial Diagnosis

To establish the extent of disease in an individual diagnosed with autosomal dominant familial exudative vitreoretinopathy (adFEVR), the following evaluations are recommended:

- Ophthalmologic examination, including indirect ophthalmoscopy and scleral depression
- Fundus fluorescein angiography, which increases the detection rate of peripheral avascularity in asymptomatic affected individuals [Ober et al 1980]

Treatment of Manifestations

Retinal avascularity per se often requires no treatment; however, it can induce ischemia, leading to neovascularization of the retinal periphery, which can be treated with prophylactic cryotherapy or argon laser photocoagulation to attempt to induce regression of the new vessels. Similar treatments are used to treat retinal holes and areas of retinal exudate to prevent retinal detachment.

Rhegmatogenous retinal detachments produced by retinal traction are repaired surgically using conventional methods, but the prognosis is guarded.

Exudative retinal detachments may be stabilized with cryotherapy, but the prognosis is poor.

Prevention of Primary Manifestations

The arc of peripheral retinal avascularity, thought to be an aberration of retinal development, is not preventable using current treatments.

Prevention of Secondary Complications

Patients with FEVR associated with reduced bone density would be expected to benefit from drugs used to treat osteoporosis, although long-term data demonstrating an increase in bone density in these patients is not yet available [Downey et al 2006].

Surveillance

Children who are at risk based on family history should undergo regular fundus examination to evaluate for the development of retinal neovascularization, traction, or exudate.

Asymptomatic individuals with a small region of peripheral avascularity may require annual review only. Those with active neovascularization or exudate may well require treatment and close observation thereafter.

Individuals with retinal traction require review at intervals depending on the degree of stability of the clinical findings. The frequency of the review varies by individual depending on the assessment of the examining clinician.

Evaluation of Relatives at Risk

Relatives at risk benefit from fundus examination and, ideally, fundus fluorescein angiography to identify any characteristic lesions. Prophylaxis in the form of peripheral retinal ablation with laser photocoagulation or cryotherapy depends on the individual's age and the progression of the lesion.

If the pathogenic variant has been identified in an affected family member, molecular genetic testing of at-risk family members may be useful: relatives who do not have the family-specific pathogenic variant do not need regular retinal examinations.

See Genetic Counseling for issues related to testing of at-risk relatives for genetic counseling purposes.

Therapies Under Investigation

Vascular endothelial growth factor (VEGF) inhibitors are currently in widespread use for acquired retinal diseases with a neovascular or exudative component. An as-yet unpublished study presented information on six children with FEVR and sight-threatening retinal neovascularization and exudate who had failed to stabilize with conventional treatments [Drenser 2006]. Treatment with pegaptanib sodium intravitreal injection resulted in a sustained decrease in exudate over six months; however, retinal traction continued to progress; in some eyes this appeared to be initiated by VEGF inhibition. The long-term effects of VEGF inhibition on the eye and the effects of VEGF inhibition in a pediatric population are currently unknown.

Search [ClinicalTrials.gov](https://clinicaltrials.gov) in the US and [EU Clinical Trials Register](https://european-clinical-trials-register.eu) in Europe for access to information on clinical studies for a wide range of diseases and conditions.

Genetic Counseling

Genetic counseling is the process of providing individuals and families with information on the nature, mode(s) of inheritance, and implications of genetic disorders to help them make informed medical and personal decisions. The following section deals with genetic risk assessment and the use of family history and genetic testing to clarify genetic status for family members; it is not meant to address all personal, cultural, or ethical issues that may arise or to substitute for consultation with a genetics professional. —ED.

Mode of Inheritance

Autosomal dominant familial exudative vitreoretinopathy (adFEVR) is inherited in an autosomal dominant manner.

Risk to Family Members

Parents of a proband

- Most individuals diagnosed with adFEVR have inherited the pathogenic variant from a parent who may or may not be affected.
 - Because of reduced penetrance, it is common for such parents to have no visual complications and thus be undiagnosed.
 - The pathogenic variant may be in an (as-yet) unidentified gene.
- A proband with adFEVR may have the disorder as the result of a *de novo* pathogenic variant. The proportion of cases caused by *de novo* pathogenic variants is currently unknown.
- Recommendations for the evaluation of parents of a proband with an apparent *de novo* pathogenic variant include examination by fundus fluorescein angiography and molecular genetic testing if a pathogenic variant has been identified in the family.

Sibs of a proband

- The risk to the sibs of the proband depends on the genetic status of the proband's parents.
- If a parent of the proband has a pathogenic variant, the risk to the sibs of inheriting the pathogenic variant is 50%.
 - If the sib inherits the pathogenic variant, it is not possible to predict whether symptoms will occur. If symptoms do occur, it is not possible to predict the age of onset or severity of symptoms.
 - Initial studies have shown that up to 90% of individuals with adFEVR can be asymptomatic.
- If a pathogenic variant has not been identified in the proband and both parents have normal findings on fundus fluorescein angiography, the risk to the sibs of a proband for adFEVR is low.
- Although no instances of germline mosaicism have been reported, it remains a possibility.

Offspring of a proband

- Each child of an individual with adFEVR has a 50% chance of inheriting the pathogenic variant.
- If the offspring inherits the pathogenic variant, it is not possible to predict whether symptoms will occur. If symptoms do occur, it is not possible to predict the age of onset or severity.
- Up to 90% of individuals with adFEVR can be asymptomatic.

Other family members of a proband. The risk to other family members depends on the status of the proband's parents. If a parent has a pathogenic variant, his or her family members are at risk.

Related Genetic Counseling Issues

See Management, Evaluation of Relatives at Risk for information on evaluating at-risk relatives for the purpose of early diagnosis and treatment.

Possible complex inheritance of FEVR. While no conclusive evidence is available, some anecdotal findings suggest that the pattern of inheritance of FEVR may be more complex than previously thought (see Genotype-Phenotype Correlations).

Genetic counseling for disorders with reduced penetrance. Reduced penetrance and the likelihood of additional (as-yet unidentified) genes associated with adFEVR result in significant difficulty in determining which at-risk family members have and have not inherited a pathogenic variant. Early studies suggested that

approximately 50% of individuals with adFEVR were asymptomatic [Benson 1995]; however, based on limited data from molecular testing for asymptomatic at-risk family members in research studies, this figure appears to be much higher, perhaps as high as 90%. Additional studies may identify penetrance to be variant specific.

Genetic counseling for disorders with genetic heterogeneity. Because the autosomal dominant, autosomal recessive, and X-linked forms of FEVR cannot be distinguished by ophthalmologic examination alone, determining the mode of inheritance for a particular family can be difficult, and for the simplex case, may not be possible.

Considerations in families with an apparent *de novo* pathogenic variant. When neither parent of a proband with an autosomal dominant condition has clinical evidence of the disorder and/or the pathogenic variant, it is possible that the proband has a *de novo* pathogenic variant or the parent has reduced penetrance. However, possible non-medical explanations including alternate paternity or maternity (e.g., with assisted reproduction) or undisclosed adoption could also be explored.

Family planning

- The optimal time for determination of genetic risk and discussion of the availability of prenatal testing is before pregnancy.
- It is appropriate to offer genetic counseling (including discussion of potential risks to offspring and reproductive options) to young adults who are affected or at risk.

DNA banking is the storage of DNA (typically extracted from white blood cells) for possible future use. Because it is likely that testing methodology and our understanding of genes, allelic variants, and diseases will improve in the future, consideration should be given to banking DNA of affected individuals.

Prenatal Testing and Preimplantation Genetic Diagnosis

Once the pathogenic variant has been identified in an affected family member, prenatal diagnosis for a pregnancy at increased risk and preimplantation genetic diagnosis are possible.

Differences in perspective may exist among medical professionals and within families regarding the use of prenatal testing, particularly if the testing is being considered for the purpose of pregnancy termination rather than early diagnosis. While most centers would consider decisions regarding prenatal testing to be the choice of the parents, discussion of these issues is appropriate.

Resources

GeneReviews staff has selected the following disease-specific and/or umbrella support organizations and/or registries for the benefit of individuals with this disorder and their families. GeneReviews is not responsible for the information provided by other organizations. For information on selection criteria, click [here](#).

- **National Eye Institute**
31 Center Drive
MSC 2510
Bethesda MD 20892-2510
Phone: 301-496-5248
Email: 2020@nei.nih.gov
[Low Vision](#)
- **Retina International**
12 Camden Row
Suite 108, Camden Business Centre

Dublin 8
Ireland
Phone: 353 1 472 0468
Email: avril.daly@retina-International.org
www.retina-international.org

- **American FEVR Research Consortium Registry**

Moran Eye Center, University of Utah
65 Medical Drive
Room 6620-C
Salt Lake City UT 84112
Phone: 800-824-2073 ext 51297; 801-585-1297
Fax: 801-587-7686
Email: jennifer.harmon@hsc.utah.edu

- **eyeGENE - National Ophthalmic Disease Genotyping Network Registry**

Phone: 301-435-3032
Email: eyeGENEinfo@nei.nih.gov
www.nei.nih.gov/eyegene

Molecular Genetics

Information in the Molecular Genetics and OMIM tables may differ from that elsewhere in the GeneReview: tables may contain more recent information. —ED.

Table A. Familial Exudative Vitreoretinopathy, Autosomal Dominant: Genes and Databases

Locus Name	Gene	Chromosome Locus	Protein	Locus-Specific Databases	HGMD	ClinVar
EVR1	<i>FZD4</i>	11q14.2	Frizzled-4	FZD4 database	FZD4	FZD4
EVR4	<i>LRP5</i>	11q13.2	Low-density lipoprotein receptor-related protein 5	LRP5 @ LOVD	LRP5	LRP5
EVR5	<i>TSPAN12</i>	7q31.31	Tetraspanin-12	TSPAN12 @ LOVD	TSPAN12	TSPAN12

Data are compiled from the following standard references: gene from [HGNC](#); chromosome locus from [OMIM](#); protein from [UniProt](#). For a description of databases (Locus Specific, HGMD, ClinVar) to which links are provided, click [here](#).

Table B. OMIM Entries for Familial Exudative Vitreoretinopathy, Autosomal Dominant ([View All in OMIM](#))

133780	EXUDATIVE VITREORETINOPATHY 1; EVR1
601813	EXUDATIVE VITREORETINOPATHY 4; EVR4
603506	LOW DENSITY LIPOPROTEIN RECEPTOR-RELATED PROTEIN 5; LRP5
604579	FRIZZLED CLASS RECEPTOR 4; FZD4
605750	EXUDATIVE VITREORETINOPATHY 3; EVR3
613138	TETRASPANIN 12; TSPAN12
613310	EXUDATIVE VITREORETINOPATHY 5; EVR5

Molecular Pathogenesis

The primary pathologic process in autosomal dominant familial exudative vitreoretinopathy (adFEVR) is believed to be a premature arrest of retinal angiogenesis/vasculogenesis or retinal vascular differentiation, leading to incomplete vascularization of the peripheral retina. To date, pathogenic variants in four genes have been shown to cause FEVR: *NDP* (encoding norrin) (OMIM 300658), *FZD4* (dominant), *LRP5* (dominant and recessive) and *TSPAN12* (dominant). Each of the encoded proteins is a component of the norrin/ β -catenin signaling pathway (also referred to as the norrin/frizzled-4 pathway). In this pathway, the ligand norrin binds to a receptor complex consisting of the receptor frizzled-4, the co-receptor low-density lipoprotein receptor-related protein-5, and the auxiliary protein tetraspanin-12. In the absence of norrin binding, signaling is not activated. This results in cytoplasmic β -catenin becoming phosphorylated and targeted for degradation through the ubiquitin-proteasome pathway. As a result, prospective target genes remain repressed. Signaling is activated by norrin binding to the frizzled-4, LRP5 and TSPAN12 receptor complex. This complex triggers a signal which inhibits the destruction of β -catenin, allowing its cytoplasmic levels to increase. Subsequently, β -catenin enters the nucleus where it interacts with the T-cell factor (TCF)/lymphoid enhancing factor (LEF) family of transcription factors to turn on the expression of norrin target genes. This signaling pathway shares many similarities to the canonic Wnt/ β -catenin pathway except that norrin substitutes Wnt as the ligand and no tetraspanins have been linked to Wnt/ β -catenin signaling. Identifying new FEVR-related genes therefore provides an ideal opportunity to discover new components of this important signaling pathway [Xu et al 2004, Junge et al 2009, Ye et al 2010].

FZD4

Gene structure. *FZD4* mRNA is 7,394 bp long and comprises two exons. For a detailed summary of gene and protein information, see Table A, **Gene**.

Pathogenic variants. Types of pathogenic variants identified in *FZD4* include missense changes, nonsense changes, insertions, and deletions; no splice site variants have been identified. The majority of deletions and insertions result in a frameshift error in the mRNA, but it is not known whether these aberrant mRNAs are targeted for nonsense-mediated mRNA decay or if they produce prematurely terminated truncated proteins.

Table 2. Selected *FZD4* Pathogenic Variants

DNA Nucleotide Change	Predicted Protein Change	Reference Sequences
c.1250G>A ¹	p.Arg417Gln	NM_012193.3 NP_036325.2
c.205C>T ²	p.His69Tyr	
c.1463G>A	p.Gly488Asp	
c.1501_1502delCT	p.Leu501SerfsTer533	

Variants listed in the table have been provided by the authors. *GeneReviews* staff have not independently verified the classification of variants.

GeneReviews follows the standard naming conventions of the Human Genome Variation Society (varnomen.hgvs.org).

1. Associated with a more severe phenotype when *in cis* with *LRP5* c.1330C>T pathogenic variant (see Genotype-Phenotype Correlations, **Possible complex inheritance of FEVR**).

2. Associated with a more severe ocular phenotype when *in trans* with the c.1463G>A pathogenic variant (see Genotype-Phenotype Correlations, **Possible complex inheritance of FEVR**).

Normal gene product. The 537-amino acid protein frizzled-4 is a member of the frizzled family of seven-pass transmembrane receptors that bind Wnt proteins [Huang & Klein 2004]. However, frizzled-4 is the only member of the frizzled family that functions in the norrin/ β -catenin pathway. Evidence suggests that this pathway is the

one underlying FEVR and is triggered by the binding of norrin rather than a Wnt ligand to a receptor complex comprising frizzled-4, LRP5, and tetraspanin12 [Xu et al 2004, Junge et al 2009].

Abnormal gene product. Many of the pathogenic variants in frizzled-4 result in premature termination codons (PTCs). The most likely outcome for pathogenic variants resulting in PTCs is haploinsufficiency induced by nonsense-mediated mRNA decay. However, if the PTC is not followed by a downstream intron, as is the case for all the frameshift variants identified in frizzled-4, the mRNAs can escape this process, enabling them to be translated into truncated mutant proteins. The precise effect of PTCs on frizzled-4 has not been investigated; thus it is not known whether an abnormal gene product is created. However, a study in which a truncated mutant frizzled-4 protein (p.Leu501fsTer533) was created in vitro showed that the mutant protein is not located in its usual position within the cell membrane but is trapped within the endoplasmic reticulum [Robitaille et al 2002, Kaykas et al 2004]. This mutated protein also trapped the wild-type protein within the cell and appeared to act in a dominant-negative manner [Kaykas et al 2004].

The majority of the frizzled-4 pathogenic missense variants appear to be in functional sites, suggesting that they knock out the function of the protein. For example, in vitro experiments have shown that missense variants in the CRD domain (p.Met105Val and p.Met157Val) reduce the ability of frizzled-4 to bind norrin and to activate the β -catenin pathway [Xu et al 2004].

LRP5

Gene structure. *LRP5* mRNA is 5,161 bp long and comprises 23 exons. For a detailed summary of gene and protein information, see Table A, **Gene**.

Pathogenic variants. All types of pathogenic variants have been identified in *LRP5*: missense changes, nonsense changes, insertions, deletions, and splice site variants. The majority of deletions, insertions, and splice variants result in a frameshift error in the mRNA, but it is not known whether these aberrant mRNAs are targeted for nonsense-mediated mRNA decay or if they produce prematurely terminated truncated proteins.

Table 3. Selected *LRP5* Pathogenic Variants

DNA Nucleotide Change	Predicted Protein Change	Reference Sequences
c.518C>T	p.Thr173Met	NM_002335.2 NP_002326.2
c.1330C>T	p.Arg444Cys ¹	
c.4081T>G	p.Cys1361Gly	
c.4099G>A	p.Glu1367Lys	
c.3502T>C	p.Tyr1168His	

Variants listed in the table have been provided by the authors. *GeneReviews* staff have not independently verified the classification of variants.

GeneReviews follows the standard naming conventions of the Human Genome Variation Society (varnomen.hgvs.org).

1. Associated with a more severe phenotype when *in cis* with *FZD4* c.1250G>A pathogenic variant (see Genotype-Phenotype Correlations, **Possible complex inheritance of FEVR**).

Normal gene product. *LRP5* encodes a 1,615-amino acid single-pass transmembrane receptor, termed low-density lipoprotein receptor-related protein 5. It partners with frizzled receptors (e.g., frizzled-4) to bind Wnt proteins [He et al 2004]. *LRP5* also functions in the norrin/ β -catenin pathway. Evidence suggests that this pathway is the one underlying FEVR and is triggered by the binding of norrin rather than a Wnt ligand to a receptor complex comprising frizzled-4, *LRP5*, and tetraspanin12.

Abnormal gene product. The *LRP5* pathogenic variants identified in individuals with adFEVR are predicted to result in functional haploinsufficiency of the protein. Most nonsense and frameshift variants are likely to

undergo nonsense-mediated mRNA decay or produce truncated proteins that are incorrectly transported within the cell; however, no direct evidence exists. In vitro cell-based assays have shown that the adFEVR missense variants p.Tyr1168His and p.Cys1361Gly affect the transduction of β -catenin signaling upon binding of either Wnt or norrin. However, two other adFEVR-related variants (p.Thr173Met and p.Glu1367Lys) tested in a similar manner did not show any effect. When proteins with the adFEVR-related variants p.Thr173Met, p.Glu1367Lys, p.Tyr1168His, and p.Cys1361Gly were cotransfected with wild-type LRP5 protein, none of them interfered with wild-type Wnt/ β -catenin signaling, arguing against a dominant-negative effect for these variants on Wnt signaling [Ai et al 2005].

TSPAN12

Gene structure. *TSPAN12* mRNA is 2579 bp long and comprises eight exons. For a detailed summary of gene and protein information, see Table A, **Gene**.

Pathogenic variants. The types of pathogenic variants identified in *TSPAN12* include missense changes, nonsense changes, insertions, deletions, and splice site variants. The majority of deletions, insertions, and splice variants result in a frameshift error in the mRNA, but it is not known whether these aberrant mRNAs are targeted for nonsense-mediated mRNA decay or if they produce prematurely terminated truncated proteins.

Table 4. Selected *TSPAN12* Pathogenic Variants

DNA Nucleotide Change	Predicted Protein Change	Reference Sequences
c.709G>C	p.Ala237Pro ¹	NM_012338.3 NP_036470.1

Variants listed in the table have been provided by the authors. *GeneReviews* staff have not independently verified the classification of variants.

GeneReviews follows the standard naming conventions of the Human Genome Variation Society (varnomen.hgvs.org).

1. Common in the Netherlands

Normal gene product. *TSPAN12* encodes a 305-amino acid protein containing four transmembrane-spanning domains, termed tetraspanin12. It forms a component of the norrin-LRP5-FZD4 signaling complex; cell-based assays have shown that it enhances the level of norrin/ β -catenin signaling [Junge et al 2009].

Abnormal gene product. The *TSPAN12* pathogenic variants identified in individuals with adFEVR are predicted to result in functional haploinsufficiency of the protein. Most nonsense and frameshift variants are predicted to undergo nonsense-mediated mRNA decay or produce truncated proteins that are incorrectly transported within the cell.

References

Literature Cited

- Ai M, Heeger S, Bartels CF, Schelling DK. Clinical and molecular findings in osteoporosis-pseudoglioma syndrome. *Am J Hum Genet.* 2005;77:741–53. PubMed PMID: 16252235.
- Benson WE. Familial exudative vitreoretinopathy. *Trans Am Ophthalmol Soc.* 1995;93:473–521. PubMed PMID: 8719692.
- Boonstra FN, van Nouhuys CE, Schuil J, de Wijs IJ, van der Donk KP, Nikopoulos K, Mukhopadhyay A, Scheffer H, Tilanus MA, Cremers FP, Hoefsloot LH. Clinical and molecular evaluation of probands and family members with familial exudative vitreoretinopathy. *Invest Ophthalmol Vis Sci.* 2009;50:4379–85. PubMed PMID: 19324841.

- Bottomley HM, Downey LM, Inglehearn CF, Toomes C. Comment on 'cosegregation of two unlinked mutant alleles in some cases of autosomal dominant familial exudative vitreoretinopathy.'. *Eur J Hum Genet.* 2006;14:6–7. PubMed PMID: 16319824.
- Boyden LM, Mao J, Belsky J, Mitzner L, Farhi A, Mitnick MA, Wu D, Insogna K, Lifton RP. High bone density due to a mutation in LDL-receptor-related protein 5. *N Engl J Med.* 2002;346:1513–21. PubMed PMID: 12015390.
- Chen ZY, Battinelli EM, Fielder A, Bunday S, Sims K, Breakefield XO, Craig IW. A mutation in the Norrie disease gene (NDP) associated with X-linked familial exudative vitreoretinopathy. *Nat Genet.* 1993;5:180–3. PubMed PMID: 8252044.
- de Crecchio G, Simonelli F, Nunziata G, Mazzeo S, Greco GM, Rinaldi E, Ventruto V, Ciccodicola A, Miano MG, Testa F, Curci A, D'Urso M, Rinaldi MM, Cavaliere ML, Castelluccio P. Autosomal recessive familial exudative vitreoretinopathy: evidence for genetic heterogeneity. *Clin Genet.* 1998;54:315–20. PubMed PMID: 9831343.
- Downey LM, Bottomley HM, Sheridan E, Ahmed M, Gilmour DF, Inglehearn CF, Reddy A, Agrawal A, Bradbury J, Toomes C. Reduced bone mineral density and hyaloid vasculature remnants in a consanguineous recessive FEVR family with a mutation in LRP5. *Br J Ophthalmol.* 2006;90:1163–7. PubMed PMID: 16929062.
- Downey LM, Keen TJ, Roberts E, Mansfield DC, Bamashmus M, Inglehearn CF. A new locus for autosomal dominant familial exudative vitreoretinopathy maps to chromosome 11p12-13. *Am J Hum Genet.* 2001;68:778–81. PubMed PMID: 11179025.
- Drenser KA. Pharmacologic therapy for pediatric retinal vascular disease. Las Vegas, NV: The Annual Meeting of the American Academy of Ophthalmology; 2006
- Drenser KA, Dailey W, Vinekar A, Dalal K, Capone A Jr, Trese MT. Clinical presentation and genetic correlation of patients with mutations affecting the FZD4 gene. *Arch Ophthalmol.* 2009;127:1649–54. PubMed PMID: 20008721.
- Gong Y, Slee RB, Fukai N, Rawadi G, Roman-Roman S, Reginato AM, Wang H, Cundy T, Glorieux FH, Lev D, Zacharin M, Oexle K, Marcelino J, Suwairi W, Heeger S, Sabatakos G, Apte S, Adkins WN, Allgrove J, Arslan-Kirchner M, Batch JA, Beighton P, Black GC, Boles RG, Boon LM, Borrone C, Brunner HG, Carle GF, Dallapiccola B, De Paepe A, Floege B, Halfhide ML, Hall B, Hennekam RC, Hirose T, Jans A, Juppner H, Kim CA, Keppler-Noreuil K, Kohlschuetter A, LaCombe D, Lambert M, Lemyre E, Letteboer T, Peltonen L, Ramesar RS, Romanengo M, Somer H, Steichen-Gersdorf E, Steinmann B, Sullivan B, Superti-Furga A, Swoboda W, van den Boogaard MJ, Van Hul W, Vikkula M, Votruba M, Zabel B, Garcia T, Baron R, Olsen BR, Warman ML. LDL receptor-related protein 5 (LRP5) affects bone accrual and eye development. *Cell.* 2001;107:513–23. PubMed PMID: 11719191.
- He X, Semenov M, Tamai K, Zeng X. LDL receptor-related proteins 5 and 6 in Wnt/beta-catenin signaling: arrows point the way. *Development.* 2004;131:1663–77. PubMed PMID: 15084453.
- Huang HC, Klein PS. The Frizzled family: receptors for multiple signal transduction pathways. *Genome Biol.* 2004;5:234. PubMed PMID: 15239825.
- Jia LY, Li XX, Yu WZ, Zeng WT, Liang C. Novel frizzled-4 gene mutations in chinese patients with familial exudative vitreoretinopathy. *Arch Ophthalmol.* 2010;128:1341–9. PubMed PMID: 20938005.
- Jiao X, Ventruto V, Trese MT, Shastry BS, Hejtmancik JF. Autosomal recessive familial exudative vitreoretinopathy is associated with mutations in LRP5. *Am J Hum Genet.* 2004;75:878–84. PubMed PMID: 15346351.
- Junge HJ, Yang S, Burton JB, Paes K, Shu X, French DM, Costa M, Rice DS, Ye W. TSPAN12 regulates retinal vascular development by promoting Norrin- but not Wnt-induced FZD4/beta-catenin signaling. *Cell.* 2009;139:299–311. PubMed PMID: 19837033.

- Kaykas A, Yang-Snyder J, Heroux M, Shah KV, Bouvier M, Moon RT. Mutant Frizzled 4 associated with vitreoretinopathy traps wild-type Frizzled in the endoplasmic reticulum by oligomerization. *Nat Cell Biol.* 2004;6:52–8. PubMed PMID: 14688793.
- Kondo H, Hayashi H, Oshima K, Tahira T, Hayashi K. Frizzled 4 gene (FZD4) mutations in patients with familial exudative vitreoretinopathy with variable expressivity. *Br J Ophthalmol.* 2003;87:1291–5. PubMed PMID: 14507768.
- Kondo H, Kusaka S, Yoshinaga A, Uchio E, Tawara A, Hayashi K, Tahira T. Mutations in the TSPAN12 gene in Japanese patients with familial exudative vitreoretinopathy. *Am J Ophthalmol.* 2011;151:1095–1100. PubMed PMID: 21334594.
- Little RD, Carulli JP, Del Mastro RG, Dupuis J, Osborne M, Folz C, Manning SP, Swain PM, Zhao SC, Eustace B, Lappe MM, Spitzer L, Zweier S, Braunschweiger K, Benchekroun Y, Hu X, Adair R, Chee L, FitzGerald MG, Tulig C, Caruso A, Tzellas N, Bawa A, Franklin B, McGuire S, Nogues X, Gong G, Allen KM, Anisowicz A, Morales AJ, Lomedico PT, Recker SM, Van Eerdewegh P, Recker RR, Johnson ML. A mutation in the LDL receptor-related protein 5 gene results in the autosomal dominant high-bone-mass trait. *Am J Hum Genet.* 2002;70:11–9. PubMed PMID: 11741193.
- MacDonald ML, Goldberg YP, Macfarlane J, Samuels ME, Trese MT, Shastry BS. Genetic variants of frizzled-4 gene in familial exudative vitreoretinopathy and advanced retinopathy of prematurity. *Clin Genet.* 2005;67:363–6. PubMed PMID: 15733276.
- Miyakubo H, Hashimoto K, Miyakubo S. Retinal vascular pattern in familial exudative vitreoretinopathy. *Ophthalmology.* 1984;91:1524–30. PubMed PMID: 6084219.
- Nallathambi J, Shukla D, Rajendran A, Namperumalsamy P, Muthulakshmi R, Sundaresan P. Identification of novel FZD4 mutations in Indian patients with familial exudative vitreoretinopathy. *Mol Vis.* 2006;12:1086–92. PubMed PMID: 17093393.
- Nikopoulos K, Gilissen C, Hoischen A, van Nouhuys CE, Boonstra FN, Blokland EA, Arts P, Wieskamp N, Strom TM, Ayuso C, Tilanus MA, Bouwhuis S, Mukhopadhyay A, Scheffer H, Hoefsloot LH, Veltman JA, Cremers FP, Collin RW. Next-generation sequencing of a 40 Mb linkage interval reveals TSPAN12 mutations in patients with familial exudative vitreoretinopathy. *Am J Hum Genet.* 2010a;86:240–7. PubMed PMID: 20159111.
- Nikopoulos K, Venselaar H, Collin RW, Riveiro-Alvarez R, Boonstra FN, Hooymans JM, Mukhopadhyay A, Shears D, van Bers M, de Wijs IJ, van Essen AJ, Sijmons RH, Tilanus MA, van Nouhuys CE, Ayuso C, Hoefsloot LH, Cremers FP. Overview of the mutation spectrum in familial exudative vitreoretinopathy and Norrie disease with identification of 21 novel variants in FZD4, LRP5, and NDP. *Hum Mutat.* 2010b;31:656–66. PubMed PMID: 20340138.
- Ober RR, Bird AC, Hamilton AM, Sehmi K. Autosomal dominant exudative vitreoretinopathy. *Br J Ophthalmol.* 1980;64:112–120. PubMed PMID: 7362811.
- Omoto S, Hayashi T, Kitahara K, Takeuchi T, Ueoka Y. Autosomal dominant familial exudative vitreoretinopathy in two Japanese families with FZD4 mutations (H69Y and C181R). *Ophthalmic Genet.* 2004;25:81–90. PubMed PMID: 15370539.
- Poulter JA, Ali M, Gilmour DF, Rice A, Kondo H, Hayashi K, Mackey DA, Kearns LS, Ruddle JB, Craig JE, Pierce EA, Downey LM, Mohamed MD, Markham AF, Inglehearn CF, Toomes C. Mutations in TSPAN12 cause autosomal-dominant familial exudative vitreoretinopathy. *Am J Hum Genet.* 2010;86:248–53. PubMed PMID: 20159112.
- Qin M, Hayashi H, Oshima K, Tahira T, Hayashi K, Kondo H. Complexity of the genotype-phenotype correlation in familial exudative vitreoretinopathy with mutations in the LRP5 and/or FZD4 genes. *Hum Mutat.* 2005;26:104–12. PubMed PMID: 15981244.

- Robitaille J, MacDonald ML, Kaykas A, Sheldahl LC, Zeisler J, Dube MP, Zhang LH, Singaraja RR, Guernsey DL, Zheng B, Siebert LF, Hoskin-Mott A, Trese MT, Pimstone SN, Shastry BS, Moon RT, Hayden MR, Goldberg YP, Samuels ME. Mutant frizzled-4 disrupts retinal angiogenesis in familial exudative vitreoretinopathy. *Nat Genet.* 2002;32:326–30. PubMed PMID: 12172548.
- Robitaille JM, Zheng B, Wallace K, Beis MJ, Tatlidil C, Yang J, Sheidow TG, Siebert L, Levin AV, Lam WC, Arthur BW, Lyons CJ, Jaakkola E, Tsilou E, Williams CA, Weaver RG Jr, Shields CL, Guernsey DL. The role of Frizzled-4 mutations in familial exudative vitreoretinopathy and Coats disease. *Br J Ophthalmol.* 2011;95:574–9. PubMed PMID: 21097938.
- Shastry BS, Trese MT. Familial exudative vitreoretinopathy: further evidence for genetic heterogeneity. *Am J Med Genet.* 1997;69:217–8. PubMed PMID: 9056564.
- Shastry BS, Trese MT. Cosegregation of two unlinked mutant alleles in some cases of autosomal dominant familial exudative vitreoretinopathy. *Eur J Hum Genet.* 2004;12:79–82. PubMed PMID: 14560311.
- Shukla D, Singh J, Sudheer G, Soman M, John RK, Ramasamy K, Perumalsamy N. Familial exudative vitreoretinopathy (FEVR). Clinical profile and management. *Indian J Ophthalmol.* 2003;51:323–8. PubMed PMID: 14750620.
- Tasman W, Augsburger JJ, Shields JA, Caputo A, Annesley WH Jr. Familial exudative vitreoretinopathy. *Trans Am Ophthalmol Soc.* 1981;79:211–26. PubMed PMID: 7342402.
- Toomes C, Bottomley HM, Jackson RM, Towns KV, Scott S, Mackey DA, Craig JE, Jiang L, Yang Z, Trembath R, Woodruff G, Gregory-Evans CY, Gregory-Evans K, Parker MJ, Black GC, Downey LM, Zhang K, Inglehearn CF. Mutations in LRP5 or FZD4 underlie the common familial exudative vitreoretinopathy locus on chromosome 11q. *Am J Hum Genet.* 2004a;74:721–30. PubMed PMID: 15024691.
- Toomes C, Bottomley HM, Scott S, Mackey DA, Craig JE, Appukuttan B, Stout JT, Flaxel CJ, Zhang K, Black GC, Fryer A, Downey LM, Inglehearn CF. Spectrum and frequency of FZD4 mutations in familial exudative vitreoretinopathy. *Invest Ophthalmol Vis Sci.* 2004b;45:2083–90. PubMed PMID: 15223780.
- van Nouhuys CE. Dominant exudative vitreoretinopathy and other vascular developmental disorders of the peripheral retina. *Doc Ophthalmol.* 1982;54:1–414. PubMed PMID: 6897033.
- van Nouhuys CE. Signs, complications, and platelet aggregation in familial exudative vitreoretinopathy. *Am J Ophthalmol.* 1991;111:34–41. PubMed PMID: 1985487.
- Van Wesenbeeck L, Cleiren E, Gram J, Beals RK, Benichou O, Scopelliti D, Key L, Renton T, Bartels C, Gong Y, Warman ML, De Vernejoul MC, Bollerslev J, Van Hul W. Six novel missense mutations in the LDL receptor-related protein 5 (LRP5) gene in different conditions with an increased bone density. *Am J Hum Genet.* 2003;72:763–71. PubMed PMID: 12579474.
- Xu Q, Wang Y, Dabdoub A, Smallwood PM, Williams J, Woods C, Kelley MW, Jiang L, Tasman W, Zhang K, Nathans J. Vascular development in the retina and inner ear: control by Norrin and Frizzled-4, a high-affinity ligand-receptor pair. *Cell.* 2004;116:883–95. PubMed PMID: 15035989.
- Ye X, Wang Y, Nathans J. The Norrin/Frizzled4 signaling pathway in retinal vascular development and disease. *Trends Mol Med.* 2010;16:417–25. PubMed PMID: 20688566.

Chapter Notes

Revision History

- 3 September 2020 (ma) Chapter retired: outdated; qualified authors not available for update
- 22 September 2011 (cd) Revision: sequence analysis of *TSPAN12* available clinically
- 14 July 2011 (me) Comprehensive update posted live

- 11 December 2008 (cd) Revision: clinical and prenatal testing available for mutations in *LRP5* and *FZD4*; prenatal testing available for mutations in *FZD4*
- 28 August 2008 (cd) Revision: sequence analysis available clinically
- 27 August 2007 (me) Comprehensive update posted live
- 21 March 2005 (me) Review posted live
- 9 September 2004 (ct) Original submission

License

GeneReviews® chapters are owned by the University of Washington. Permission is hereby granted to reproduce, distribute, and translate copies of content materials for noncommercial research purposes only, provided that (i) credit for source (<http://www.genereviews.org/>) and copyright (© 1993-2024 University of Washington) are included with each copy; (ii) a link to the original material is provided whenever the material is published elsewhere on the Web; and (iii) reproducers, distributors, and/or translators comply with the [GeneReviews® Copyright Notice and Usage Disclaimer](#). No further modifications are allowed. For clarity, excerpts of GeneReviews chapters for use in lab reports and clinic notes are a permitted use.

For more information, see the [GeneReviews® Copyright Notice and Usage Disclaimer](#).

For questions regarding permissions or whether a specified use is allowed, contact: admasst@uw.edu.