



Hereditary Coproporphyria

Bruce Wang, MD¹ and D Montgomery Bissell, MD²

Created: December 13, 2012; Revised: May 19, 2022.

Summary

Clinical characteristics

Hereditary coproporphyria (HCP) is an acute (hepatic) porphyria in which the acute symptoms are neurovisceral and occur in discrete episodes. Attacks typically start in the abdomen with low-grade pain that slowly increases over a period of days (not hours) with nausea progressing to vomiting. In some individuals, the pain is predominantly in the back or extremities. When an acute attack is untreated, a motor neuropathy may develop over a period of days or a few weeks. The neuropathy first appears as weakness proximally in the arms and legs, then progresses distally to involve the hands and feet. Some individuals experience respiratory insufficiency due to loss of innervation of the diaphragm and muscles of respiration. Acute attacks are associated commonly with use of certain medications, caloric deprivation, and changes in female reproductive hormones. About 20% of those with an acute attack also experience photosensitivity associated with bullae and skin fragility.

Diagnosis/testing

The most sensitive and specific biochemical screening test for any one of the acute porphyrias (including HCP) during an acute attack is a striking increase in urinary porphobilinogen. Quantitative analysis of porphyrins in both urine and feces is essential to distinguish between the different acute porphyrias and establish the diagnosis of HCP. Identification of a heterozygous pathogenic variant in *CPOX* (encoding the enzyme coproporphyrinogen-III oxidase) confirms the diagnosis and enables family studies.

Management

Treatment of manifestations: Acute attacks are treated by discontinuation of any medications thought to induce attacks, management of dehydration and/or hyponatremia, administration of carbohydrate, and infusion of hematin (Panhematin[®], Recordati Group). Individuals with more than four attacks per year have historically been at highest risk for developing chronic neurologic manifestations. Givosiran, an siRNA that works directly against ALAS1 and is effective in preventing acute attacks in such individuals, was approved in the US in

Author Affiliations: 1 University of California San Francisco San Francisco, California; Email: bruce.wang@ucsf.edu. 2 University of California San Francisco San Francisco, California; Email: montgomery.bissell@ucsf.edu.

Copyright © 1993-2024, University of Washington, Seattle. GeneReviews is a registered trademark of the University of Washington, Seattle. All rights reserved.

November 2019; however, its effectiveness remains to be determined with long-term study. Treatment of symptoms and complications, such as seizures, should be with medications known to be safe in acute porphyria (see www.drugs-porphyrria.org). A minority of affected individuals experience repeat acute attacks, in which case management strategies include suppression of ovulation in females, prophylactic use of hematin, and liver transplantation when attacks and neurologic complications persist despite multiple courses of hematin. Treatment of chronic (cutaneous) manifestations is through avoidance of sun/light, including wearing protective clothing and using protective tinted glass for cars and windows to prevent exposure to blue light.

Prevention of primary manifestations: Agents or circumstances that may trigger an acute attack (including use of oral contraception and progestins in women) are avoided. Suppression of menses using a GnRH agonist (leuprolide, nafarelin, and others) may help *CPOX* heterozygotes who experience monthly exacerbations. Menopausal symptoms may occur as a side effect of GnRH agonists and can be treated with a low dose of estrogen. In *CPOX* heterozygotes undergoing surgery, minimize preoperative fasting and provide intravenous glucose in the perioperative period. Anesthesia induction using non-barbiturate agents is recommended.

Surveillance: Annual liver and kidney function in those with chronically elevated ALA levels and/or those older than age 60 years; assessment for liver fibrosis (transient elastography [FibroScan®] or a blood-based test [FibroTest® or FibroSure®]); annual screening for hepatocellular carcinoma with abdominal imaging and serum alpha-fetoprotein in those older than age 60.

Agents/circumstances to avoid: Fasting, use of oral contraception and progestins in females, and certain drugs including barbiturates and phenytoin.

Evaluation of relatives at risk: If the family-specific *CPOX* pathogenic variant is known, clarification of the genetic status of relatives at risk allows early diagnosis of heterozygotes and education regarding how to avoid risk factors known to be associated with acute attacks.

Genetic counseling

HCP is inherited in an autosomal dominant manner with low penetrance. Most individuals with HCP have an affected parent; the proportion with a *de novo* pathogenic variant is unknown. Each child of an individual with HCP has a 50% chance of inheriting the *CPOX* pathogenic variant. Because of reduced penetrance, many individuals with a *CPOX* pathogenic variant have no signs or symptoms of HCP. Prenatal testing for pregnancies at increased risk is possible if the pathogenic variant in an affected family member is known.

Diagnosis

Hereditary coproporphyrria (HCP) is classified as both an acute (hepatic) porphyria (with neurologic manifestations that occur as discrete, severe episodes) and a chronic (cutaneous) porphyria with long-standing photosensitivity.

Diagnostic criteria for HCP have been published [Anderson et al 2005, Whatley et al 2009].

Suggestive Findings

Acute hepatic porphyria **should be suspected** in individuals with the following symptoms or findings:

- Nausea for at least 48 hours
- Abdominal, back, or extremity pain for at least 48 hours
- New-onset seizures
- Hyponatremia
- Family history of porphyria

Note: (1) Although *CPOX* pathogenic variants occur equally in males and females, acute attacks are much more frequent in women, mainly between ages 16 and 45 years (the years of active ovulation). (2) Absence of a known family history of porphyria does not preclude the diagnosis.

Chronic cutaneous porphyria is suspected in individuals with bullae and fragility of light-exposed skin that result in depigmented scars; however, the cutaneous signs occur in only a minority of heterozygotes, even during an acute attack.

Establishing the Diagnosis

The diagnosis of HCP is **established** in a proband by biochemical testing (see Table 1), followed by identification of a heterozygous pathogenic variant in *CPOX* by molecular genetic testing (see Table 2).

Biochemical Testing

For an individual with pain and neurologic signs, the initial goal is to determine if the symptoms can be attributed to an attack related to any one of the acute porphyrias (i.e., ALA dehydratase deficiency porphyria, acute intermittent porphyria, hereditary coproporphyrria, or variegate porphyria) (see Differential Diagnosis). Note: Since initial management is the same for all four types of acute porphyria, it is not necessary to determine at the outset of treatment which one of the four types of acute porphyria is present.

The most sensitive and specific biochemical diagnostic tests for HCP are detailed in Table 1. Once the diagnosis of an acute porphyria is established by identification of a striking increase in urinary porphobilinogen (PBG), quantitative analysis of porphyrins in both urine and feces may help define the specific type (Figure 1).

- Active HCP is suggested by a quantitative urinary PBG that is at least threefold the upper limit of normal.
- The characteristic finding in stool is COPRO >> PROTO, quantified as units/g dry weight of feces. Note: Some laboratories report units/24 hours, which is inherently inaccurate. US laboratories that do the more precise analysis include [ARUP](#) (Salt Lake City, UT) and the [Porphyria Center, University of Texas Medical Branch](#) (Galveston, TX).
- The diagnosis is further substantiated by analysis of the COPRO-III/COPRO-I fecal porphyrin ratio, showing that 60%-95% of the total COPRO is isomer-III. In a normal (or "negative") test, the predominant fecal porphyrin is PROTO, and the COPRO isomer III/I ratio in many cases is <0.5 [Kühnel et al 2000].

Table 1. Biochemical Characteristics of Hereditary Coproporphyrria

Deficient Enzyme	Urine		Stool	
	Active	Asx	Active	Asx
Coproporphyrinogen-III oxidase ^{1,2}	↑PBG ^{3,4} ↑COPRO ⁵	Normal PBG COPRO ⁶	COPRO >> PROTO ⁷	See footnote 8.

Active = symptomatic *CPOX* heterozygotes; Asx = asymptomatic *CPOX* heterozygotes; COPRO = coproporphyrin; Normal PBG = <2 mg (0.85 μmol) per g urine creatinine; PBG = porphobilinogen; PROTO = protoporphyrin

1. Also known as coproporphyrinogen oxidase and coproporphyrinogen decarboxylase

2. The enzyme assay is not widely available and is not used for diagnostic purposes.

3. Active HCP is suggested by a quantitative urine PBG that is at least threefold the upper limit of normal.

4. Commercial laboratories offer quantitative delta-aminolevulinic acid (ALA), PBG, and fractionated urine porphyrins. Values normalized to urine creatinine are satisfactory for clinical use, making a 24-hour collection unnecessary.

5. See Differential Diagnosis for discussion of nonspecific elevation of COPRO in the urine.

6. Fractionated urine porphyrins may reveal a minor rise in COPRO (<3-fold the upper limit of normal); however, this is nonspecific and insufficient for diagnosis (see Differential Diagnosis).

7. 60%-95% of the total COPRO is isomer-III.

8. Fecal porphyrin analysis is the best test for distinguishing HCP from nonspecific coproporphyrinuria: heterozygotes show a predominance of fecal COPRO and an elevated COPRO III/I ratio (see Biochemical Testing).

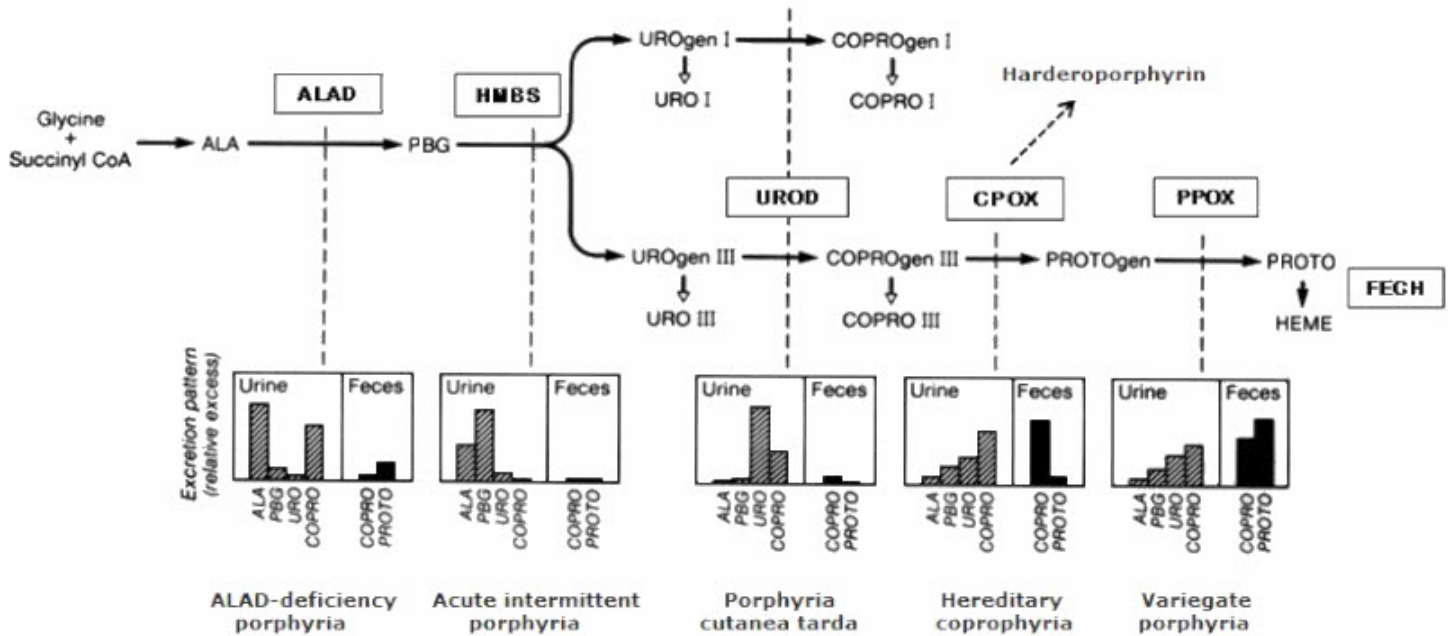


Figure 1. Excretion profile of the hepatic porphyrias

Profile of heme precursor excretion for the types of hepatic porphyria. The pathway of heme synthesis (arrows) is served by a series of enzymes (boxes). Pathogenic variants that decrease the function of a particular enzyme change the profile of heme precursors in urine and/or stool (vertical dashed lines) to one that is characteristic of the specific type of porphyria. The vertical bars depict the relative change in each metabolite, not the absolute amount. To illustrate, the urine PBG in HCP and AIP during an attack may reach similar levels.

Enzyme abbreviations:

ALAD = delta-aminolevulinic acid (ALA) dehydratase

HMBS = hydroxymethylbilane synthase; also known as porphobilinogen (PBG) deaminase

UROD = uroporphyrinogen (UROgen) decarboxylase

CPOX = coproporphyrinogen(COPROgen) decarboxylase

PPOX = protoporphyrinogen(PROTOgen) decarboxylase

FECH = ferrochelatase

Molecular Genetic Testing

The molecular testing approach typically includes **single-gene testing** targeting the type of acute porphyria suggested by biochemical testing.

- Sequence analysis of *CPOX* is performed first and followed by gene-targeted deletion/duplication analysis if no pathogenic variant is found.
- If detailed *CPOX* testing is normal, *PPOX* (the gene for variegate porphyria [VP]) is analyzed. The biochemical findings in HCP and VP can overlap, leading to misassignment of diagnosis in some instances.

Table 2. Molecular Genetic Testing Used in Hereditary Coproporphyrria

Gene ¹	Method	Proportion of Probands with a Pathogenic Variant ² Detectable by Method
CPOX	Sequence analysis ³	32/33 ^{4, 5}
	Gene-targeted deletion/duplication analysis ⁶	See footnote 7.

1. See Table A. Genes and Databases for chromosome locus and protein.

2. See Molecular Genetics for information on allelic variants detected in this gene.

3. Sequence analysis detects variants that are benign, likely benign, of uncertain significance, likely pathogenic, or pathogenic. Variants may include small intragenic deletions/insertions and missense, nonsense, and splice site variants; typically, exon or whole-gene deletions/duplications are not detected. For issues to consider in interpretation of sequence analysis results, click [here](#).

4. Sequence analysis identified a pathogenic variant in 31 of 32 (97%) individuals with the clinical and biochemical diagnosis of HCP [Whatley et al 2009].

5. Grimes et al [2016], Lambie et al [2018]

6. Gene-targeted deletion/duplication analysis detects intragenic deletions or duplications. Methods used may include a range of techniques such as quantitative PCR, long-range PCR, multiplex ligation-dependent probe amplification (MLPA), and a gene-targeted microarray designed to detect single-exon deletions or duplications.

7. A 13-kb deletion extending from exon 4 to the 3'UTR [Whatley et al 2009] and a 1.3-kb deletion spanning exon 5 (found in 4 Swedish families) [Barbaro et al 2012] have been published.

Clinical Characteristics

Clinical Description

Hereditary coproporphyrria (HCP) is classified as both an acute and a chronic porphyria. Porphyrrias with neurologic manifestations are considered acute, because the symptoms occur as discrete, severe episodes. Porphyrrias with cutaneous manifestations are considered chronic, because photosensitivity is long standing (see Table 3).

In a German study of 46 individuals with acute HCP, 90% had abdominal pain; only 13% had cutaneous findings despite substantial overproduction of coproporphyrin [Kühnel et al 2000]. An earlier British study of 111 individuals with HCP reported similar findings [Brodie et al 1977].

Symptoms prior to puberty in individuals who are heterozygous for a *CPOX* pathogenic variant have never been observed.

Fertility and longevity do not appear to be reduced in *CPOX* heterozygotes.

Acute Attacks

The initial symptoms of an acute attack are nonspecific, consisting of low-grade abdominal pain that slowly increases over a period of days (not hours) with nausea progressing to vomiting of all oral intake.

Typically the pain is not well localized but in some instances does mimic acute inflammation of the gallbladder, appendix, or other intra-abdominal organ. In most instances the abdominal examination is unremarkable except for diminished bowel sounds consistent with ileus, which is common and can be seen on abdominal radiography. Typically fever is absent. In a young woman of reproductive age, the symptoms may raise the question of early pregnancy.

Prior to the widespread use of abdominal imaging in the emergency room setting, some individuals with abdominal pain and undiagnosed acute porphyria underwent urgent exploratory surgery. Thus, a history of abdominal surgery with negative findings was considered characteristic of acute porphyria.

A minority of affected individuals has predominantly back or extremity pain, which is usually deep and aching, not localized to joints or muscle groups.

Neurologic manifestations. Seizures may occur early in an attack and be the problem that brings the affected individual to medical attention. In a young woman with abdominal pain and new-onset seizures, it is critical to consider acute porphyria because of the implications for seizure management (see Management).

When an attack is unrecognized as such or treated with inappropriate medications, it may progress to a motor neuropathy, which typically occurs many days to a few weeks after the onset of symptoms. The neuropathy first appears as weakness proximally in the arms and legs, then progresses distally to involve the hands and feet. Neurosensory function remains largely intact.

In some individuals the motor neuropathy eventually involves nerves serving the diaphragm and muscles of respiration. Ventilator support may be needed.

Tachycardia and bowel dysmotility (manifest as constipation) are common in acute attacks and believed to represent involvement of the autonomic nervous system.

Of note, when the acute attack is recognized early and treated appropriately (see Management), the outlook for survival and eventual complete recovery is good. Individuals with frequent recurrent acute attacks (defined as more than four attacks per year) have historically been at highest risk for development of chronic neurologic manifestations. In November 2019, givosiran, an siRNA that works directly against ALAS1, was approved in the US after demonstrating effectiveness in preventing acute attacks in these individuals. Effective prevention of acute attacks with givosiran may reduce or prevent the development of neurologic sequelae in persons with HCP with frequent recurrent attacks, though this remains to be determined with long-term study (see Treatment with Givosiran).

Psychosis. The mental status of people presenting with an acute attack of porphyria varies widely and can include psychosis. Commonly the predominant feature is distress (including pain) that may seem hysterical or feigned, given a negative examination, absence of fever, and abdominal imaging showing some ileus only. Incessant demands for relief may be interpreted as drug-seeking behavior.

Because of the altered affect in acute porphyria, it has been speculated that mental illness is a long-term consequence of an attack and that mental institutions may house disproportionately large numbers of individuals with undiagnosed acute porphyria. Screening of residents in mental health facilities by urinary porphobilinogen (PBG) and/or PBG deaminase activity in blood (which diagnoses [acute intermittent porphyria](#)) has been performed, with mixed results [Jara-Prado et al 2000]. The experience of those who have monitored affected individuals over many years suggests that heterozygotes who are at risk for one of the acute porphyrias are no more prone to chronic mental illness than individuals in the general population; however, a prospective study is needed.

Kidney and liver disease. In people with any type of acute porphyria, the kidneys and liver may develop chronic changes that often are subclinical. One manifestation of the liver problem is excess primary liver cancer (hepatocellular carcinoma). The risk is greatest in women older than age 60 with acute intermittent porphyria (160-fold increased risk above the general population risk); for men there is a 37-fold increase in risk [Sardh et al 2013]. This and the kidney disease may be restricted largely to heterozygotes with chronically elevated plasma or urine delta-aminolevulinic acid (ALA). Hypertension may be chronic in those with frequent symptoms and may contribute to renal disease.

Inasmuch as ALA and PBG tend to be minimally elevated or normal in HCP heterozygotes, the risk of hepatic and renal complications may be less in HCP than in [acute intermittent porphyria](#).

Circumstances commonly associated with acute attacks are caloric deprivation, changes in female reproductive hormones, and use of porphyria-inducing medications or drugs:

- **Caloric deprivation.** Fasting appears to sensitize the heme-synthetic pathway to an inducer, which could be external (i.e., a medication) or internal (ovarian hormones). The sensitizing effect of caloric deprivation was demonstrated in the 1960s in experimental animals and has been confirmed by clinical observation. People who fail to eat because of intercurrent illness or who undertake drastic weight loss are predisposed to an acute attack. First attacks have been reported after reduction gastroplasty for obesity [Bonkovsky et al 2008]. *CPOX* heterozygotes undergoing surgery are at risk because of the routine preoperative fast. This and other anecdotal experience have led to consensus that the first line of treatment for an acute attack is intravenous glucose, which is occasionally helpful.
- **Changes in female reproductive hormones.** A role for female reproductive hormones can be inferred from the fact that acute attacks are infrequent prior to menarche and after menopause. Some women have monthly attacks that appear a few days before the onset of menstruation (when progesterins peak). Attacks have been linked to use of oral contraceptives; the risk may be associated more with the progesterone component than the estrogen component.
- **Use of porphyria-inducing medications or drugs.** See Management, Agents/Circumstances to Avoid.

Chronic (cutaneous) manifestations. Photocutaneous damage is present in only a small minority of those with acute attacks. Bullae and fragility of light-exposed skin, in particular the backs of the hands, result in depigmented scars. Facial skin damage also occurs, with excess hair growth on the temples, ears, and cheeks; this is more noticeable in women than in men.

The cutaneous findings in HCP resemble those in porphyria cutanea tarda (PCT) and in variegate porphyria (VP).

Threshold for a Pathogenic Effect of Porphyrins and Their Precursors

Clinically active acute porphyria is associated with substantial elevation of the precursors ALA and PBG in the blood and urine; the cutaneous porphyrias are associated with increased porphyrins in blood, urine, and feces. In the acute porphyrias and cutaneous porphyrias, a threshold for symptoms appears to exist.

- **Acute (hepatic) porphyrias.** A threshold for acute attacks is suggested by the fact that in virtually all symptomatic individuals, urinary PBG excretion exceeds 25 mg/g creatinine, or more than tenfold the upper limit of normal. Urinary ALA excretion increases roughly in parallel.
- In contrast, in asymptomatic individuals the baseline urinary PBG excretion varies widely, usually low or normal but occasionally exceeding 25 mg/g creatinine. For this reason, it is advisable to establish the baseline urinary PBG excretion for *CPOX* heterozygotes (see Management, Evaluations Following Initial Diagnosis).
- **Chronic (cutaneous) porphyrias.** A threshold has been well defined for porphyria cutanea tarda (PCT), in which photosensitivity occurs at values of urine uroporphyrin (the predominant pathway intermediate) that are more than 20-fold the upper limit of normal. However, the same is not apparent with regard to urine coproporphyrin: only a minority of *CPOX* heterozygotes exhibit any photosensitivity.

Of note, in individuals with HCP and chronic liver disease the cutaneous component may be more prominent than expected for the observed urine or plasma PBG concentration. Coproporphyrin leaves the plasma largely via the liver going into bile. In chronic liver disease, bile transport processes or bile formation may be impaired, leading to accumulation of coproporphyrin in plasma, which then results in photosensitivity.

Pathophysiology

The regulation of heme synthesis differs in liver and in bone marrow, the principal sites of heme production in the body. The liver is the main source of precursors in the acute (hepatic) porphyrias: acute attacks are precipitated when environmental factors stimulate increased hepatic heme synthesis and the genetically altered step in heme production becomes rate limiting (Figure 1). Heme synthesis in the liver largely serves production of the cytochrome P450 family of heme-proteins, which are present in high concentration in the liver and have a relatively high turnover rate.

It is estimated that 20%-25% of total heme production normally occurs in the liver [Billing 1978]; however, that proportion increases when the liver is exposed to xenobiotics that undergo oxidative metabolism and stimulate cytochrome production (especially CYP3A4).

Acute attacks. The precursors ALA and PBG, unlike porphyrins, are colorless and non-fluorescent and do not contribute to photosensitivity in porphyria. Rather, ALA and PBG are highly associated with the neurologic manifestations of acute porphyria and are probably causal, although the mechanism remains speculative. The currently favored hypothesis implicates ALA (more than PBG), in part because acute neurologic symptoms occur in two other inherited conditions involving overproduction of ALA but not PBG (ALA dehydratase deficiency porphyria and [tyrosinemia](#)). In addition, lead poisoning causes a similar biochemical derangement by binding the sulfhydryls of ALA dehydratase and reducing enzymatic activity; the symptoms in lead poisoning closely mimic those of acute porphyria [Bissell et al 2015]. Experimental studies indicate that ALA is a pro-oxidant species that is capable of damaging the inner membrane of mitochondria [Vercesi et al 1994].

Liver transplantation has established that this organ is responsible for acute attacks. Liver transplantation has cured individuals with refractory acute symptoms [Soonawalla et al 2004]. Moreover, transplantation of a porphyric liver into a normal recipient in two cases resulted in high circulating levels of ALA and PBG and symptoms of porphyria [Dowman et al 2011].

Cutaneous manifestations. Porphyrins are energized by blue light (peak wavelength 410 nm). In a test tube, as activated porphyrins relax back to the ground state, the released energy is evident as red fluorescence (ca. 625 nm). In vivo, the cycle of light activation and relaxation back to the ground state causes tissue damage, the nature of which varies with the porphyrin. URO and COPRO give rise to bullae and fragility of light-exposed skin, in particular the backs of the hands.

Genotype-Phenotype Correlations

HCP. *CPOX* pathogenic variants are not clustered around the enzymatic site. Furthermore, no correlation exists between the clinical phenotype and the residual enzymatic activity measured in vitro for a given pathogenic variant [Lamoril et al 2001].

- **Neonatal-onset HCP.** In two reported cases, heterozygous (but not biallelic) *CPOX* variants have been associated with massive elevation of coproporphyrins, cutaneous blistering, and hemolytic anemia with onset in the neonatal period. In one case, the pathogenic variant was in exon 6 causing exon 6 skipping. In the other, it was a four-base-pair deletion in exon 7. The clinical picture resembled harderporphyria (see Genetically Related Disorders), but fecal analysis indicated HCP (markedly increased coproporphyrin and normal harderporphyrin). Both cases also manifested adrenal insufficiency and hypospadias (with a 46,XY karyotype) [Hasegawa et al 2017]. The syndrome has been termed "neonatal-onset HCP," although the same *CPOX* variants also give rise to typical adult-onset HCP. The reason for the dramatic difference in presentation is unknown. It has been suggested that adrenal insufficiency is the proximal cause of the neonatal form, perhaps because heme synthesis is regulated by adrenal steroids to a degree that has not been appreciated.

- **Homozygotes for *CPOX* pathogenic variants** that cause minimal or no symptoms in heterozygotes have very low coproporphyrinogen-III oxidase activity and a severe phenotype [Schmitt et al 2005, Hasanoglu et al 2011] (see Genetically Related Disorders).

Double heterozygosity for pathogenic variants in genes causing two different types of acute (hepatic) porphyria. Double heterozygotes for a pathogenic variant in *CPOX* and either a pathogenic variant in *PPOX* (**variegate porphyria** [VP]) [van Tuyl van Serooskerken et al 2011] or *ALAD* (ALA dehydratase deficiency porphyria [ADP]) [Akagi et al 2006] have been described. The phenotypes of such double heterozygotes vary but are not necessarily more severe than those associated with heterozygosity for either pathogenic variant alone, suggesting that double heterozygotes for two different types of acute porphyria may not be as rare as has been assumed.

Penetrance

Because population studies to determine the prevalence of HCP heterozygosity have not been done, the penetrance of *CPOX* pathogenic variants is unknown. Given the rarity of acute attacks of HCP relative to **acute intermittent porphyria** (AIP), it is suspected that only a small minority of *CPOX* heterozygotes express the clinical disease. In 32 members of an Australian family, 14 (including 10 adults) were determined to have HCP on the basis of a high fecal COPRO III/I ratio and/or low lymphocyte *CPOX* enzyme activity; however, only one had clinical symptoms of porphyria [Blake et al 1992].

HCP, along with AIP and VP, are genetic disorders with reduced penetrance. Heme production in most heterozygotes appears to be adequate for physiologic homeostasis. Thus, environmental or physiologic factors play a role in the pathogenesis of acute attacks (see Management, Agents/Circumstances to Avoid). Genetic cofactors may also be involved; none has been identified to date.

Nomenclature

"Coproporphyrinuria" describes urine with an elevated level of coproporphyrin of any cause.

Coproporphyrria in individuals heterozygous for a *CPOX* pathogenic variant is referred to as hereditary coproporphyrria.

Prevalence

Clinical experience suggests that HCP is the least prevalent of the three principal types of acute porphyria: AIP, VP, and HCP. However, symptoms in HCP may be less frequent than in AIP or VP. Population surveys for *CPOX* pathogenic variants have not been reported.

Genetically Related (Allelic) Disorders

Biallelic *CPOX* pathogenic variants. Certain *CPOX* pathogenic variants (notably D400-K404 in exon 6) in the homozygous state result in a disorder called harderoporphyria [Hasanoglu et al 2011]. Some pathogenic variants may affect the active site of the enzyme, possibly causing premature separation of *CPOX* from its substrate. The result is incomplete decarboxylation of COPROgen, yielding the tricarboxylic intermediate harderoporphyrinogen instead of dicarboxylic PROTOgen (Figure 1).

Heterozygotes for a *CPOX* pathogenic variant that is associated with harderoporphyria have no symptoms; those with biallelic pathogenic variants have large amounts of harderoporphyrin in the stool and neonatal onset of hemolytic anemia and jaundice, which can resemble **congenital erythropoietic porphyria**, an autosomal recessive condition with hemolysis and severe photosensitivity in infancy. They can also have acute porphyric attacks with high levels of urinary delta-aminolevulinic acid (ALA) and porphobilinogen (PBG). One infant died at age five

months, apparently from complications of an acute attack [Hasanoglu et al 2011]. Some develop normally while others exhibit short stature.

Differential Diagnosis

The **genetic porphyrias** comprise a group of distinct diseases, each resulting from alteration of a specific step in the heme synthesis pathway that results in accumulation of a specific metabolite (Figure 1).

In Table 3 the porphyrias are grouped by their principal clinical manifestations (neurovisceral or cutaneous) and the tissue origin of the excess production of pathway intermediates (liver [i.e., hepatic] or bone marrow [i.e., erythropoietic]).

- Porphyrias with neurovisceral manifestations are considered acute because the symptoms occur as discrete, severe episodes, which may be spontaneous but frequently are induced by external factors. The four acute porphyrias are: ALA dehydratase deficiency porphyria (ADP), **acute intermittent porphyria** (AIP), HCP, and **variegate porphyria** (VP). Only a few individuals with ADP have been reported in the world literature.
- Porphyrias with cutaneous manifestations include either chronic blistering skin lesions (i.e., VP as well as PCT, HCP, CEP, and **hepatoerythropoietic porphyria** [HEP]) or acute non-blistering photosensitivity (i.e., **EPP** and **XLP**).

Table 3. Classification of the Hereditary Porphyrias

Type of Porphyria		Findings		MOI
		Neurovisceral ¹	Photocutaneous	
Hepatic	ADP	+	0	AR
	AIP	+	0	AD
	HCP	+	+	AD
	PCT type II	0	+	AD
	VP	+	+	AD
Erythropoietic	CEP	0	+	AR
	EPP, AR	0	+ ²	AR
	XLP	0	+ ²	XL

0 = no symptoms; + = mild to severe symptoms; AD = autosomal dominant; ADP = ALA dehydratase deficiency porphyria; AIP = acute intermittent porphyria; AR = autosomal recessive; CEP = congenital erythropoietic porphyria; EPP = erythropoietic protoporphyria; HCP = hereditary coproporphyria; MOI = mode of inheritance; PCT = porphyria cutanea tarda; VP = variegate porphyria; XL = X-linked; XLP = X-Linked protoporphyria

1. Porphyrias with neurovisceral manifestations have been considered "acute" in part because the most common of these disorders, named "acute intermittent porphyria," is the prototype for the neurovisceral porphyrias in which symptoms can occur acutely as discrete, severe episodes; however, some affected individuals develop chronic manifestations, and a few remain susceptible to exacerbating factors throughout their lives.

2. Photocutaneous manifestations of EPP are acute and non-blistering, in contrast to the chronic blistering in the other cutaneous porphyrias (including VP).

While these clinical distinctions are important for the differential diagnosis, biochemical analysis is always necessary; however, biochemical testing may fail to distinguish HCP from VP, in which case molecular genetic testing of *CPOX* (HCP) and *PPOX* (VP) may be the only definitive diagnostic test.

In individuals with progressive weakness due to the motor neuropathy caused by one of the acute porphyrias (AIP, VP, HCP, and ADP), the entity most likely to be considered is acute ascending polyneuropathy, the

Guillain-Barré syndrome. However, abdominal pain, constipation, and tachycardia precede the acute neurologic illness in the acute porphyrias but not in Guillain-Barré syndrome. CSF protein is normal in the acute porphyrias, but elevated in Guillain-Barré syndrome. Urinary porphobilinogen (PBG) is markedly elevated in the acute porphyrias when symptoms are present, but normal in Guillain-Barré syndrome.

Coproporphyrinuria

- **Lead intoxication.** The predominant elevation of coproporphyrin that is characteristic of HCP can also be seen in lead intoxication, in which the symptoms resemble those of an acute porphyria. The additional diagnostic finding in heavy metal poisoning is elevation of delta-aminolevulinic acid (ALA) unaccompanied by any increase in PBG.
- **Rotor syndrome,** inherited in an autosomal recessive manner and caused by simultaneous deficiencies of the organic anion transporting polypeptides OATP1B1 and OATP1B3, is also associated with coproporphyrinuria [van de Steeg et al 2012].
- **Nonspecific coproporphyrinuria.** The most important differential diagnosis in an individual with elevated urine coproporphyrin is HCP vs nonspecific coproporphyrinuria. Of all the people referred to a porphyria center, the largest subgroup has nonspecific coproporphyrinuria. Elevation of urine coproporphyrin is associated with a wide range of clinical conditions. It is particularly frequent in acquired liver disease (e.g., chronic viral hepatitis), but can also be seen in neurologic or hematologic diseases. Rarely, it is caused by an inherited hepatic transporter defect.

Two tests helpful for the differential diagnosis of coproporphyrinuria are:

- Urine PBG, which is more than tenfold elevated in the inherited acute porphyrias with active symptoms;
- The ratio of copro-III to copro-I in feces as measured by high-performance liquid chromatography (used for fecal porphyrin fractionation in most commercial labs). In nonspecific coproporphyrinuria the ratio is usually similar to that in normal controls [Gibson et al 2000].

For a case example of misdiagnosis of nonspecific coproporphyrinuria, click [here](#).

Management

Evaluations Following Initial Diagnosis

To establish the extent of disease and needs of an individual diagnosed with hereditary coproporphryia (HCP), the evaluations listed in Table 4 are recommended (if they have not already been completed).

Table 4. Recommended Evaluations Following Initial Diagnosis of Hereditary Coproporphryia

Evaluation	Comment
Review of medications for those thought to induce attacks	See Agents/Circumstances to Avoid.
Detailed neurologic exam	<ul style="list-style-type: none"> • For signs of motor neuropathy (indicating a more advanced attack & thus, need for early treatment w/hematin; see Table 5) • Inquiry into possibility of seizures ¹
Measurement of serum sodium concentration	Hyponatremia is characteristic & may be profound (serum sodium concentration <110 mEq/L), requiring urgent correction w/due regard for risk of central pontine myelinolysis.
Quantitation of urinary excretion of PBG on several occasions over a few mos to establish baseline	For future use in determining if a new symptom or drug reaction is due to an acute attack ²

Table 4. continued from previous page.

Evaluation	Comment
Consultation w/medical geneticist &/or genetic counselor	

PBG = porphobilinogen

1. Tran et al [2013]

2. In an acute attack urinary excretion of PBG is substantially elevated over the baseline.

Treatment of Manifestations

Treatment guidelines for HCP have been published [Balwani et al 2017] ([full text](#)).

Acute Attacks

No curative therapy for HCP exists.

Supportive therapy by multidisciplinary specialists is summarized in Table 5.

Details regarding treatment with givosiran, which was approved for prophylactic treatment for individuals with HCP with frequent recurrent acute neurovisceral pain episodes (defined as more than four attacks per year) in the US, but not necessarily in all countries, follow Table 5.

Table 5. Treatment of Acute Attacks in Individuals with Hereditary Coproporphria

Manifestation	Treatment	Consideration/Other
Acute abdominal pain	Identify & discontinue any medications thought to induce attacks.	See Agents/Circumstances to Avoid.
	Discontinue all nonessential medications.	Treat symptoms & complications w/medications known to be safe in acute porphyria (see www.drugs-porphyrria.org).
Nausea/vomiting	Administer glucose-containing IV solution to reverse fasting state.	Some individuals recover w/rehydration & glucose infusion only; those who do not respond in 24-48 hours should receive intravenous hematin.
	Obtain a serum sodium level. ¹	In those w/hyponatremia, rehydration w/10% dextrose in 0.5N sodium chloride is recommended. ²
Moderate-to-severe acute attacks	Administer intravenous hematin.	<ul style="list-style-type: none"> For use in any attack that requires hospitalization. For those w/a confirmed diagnosis & recurrent attacks, hematin is given as soon as it can be obtained, in addition to IV fluids & glucose. Hematin is not stocked by most hospital pharmacies but can be obtained by overnight express from the manufacturer (Panhematin[®], Recordati, 1-888-575-8344). ^{3, 4, 5, 6} Responses to hematin infusion can include: ↓ urine concentration of PBG (the 1st sign) after 2 doses; clinical improvement after 3-4 doses (typically dramatic) w/no further need of narcotic analgesia.
Motor neuropathy	Administer hematin as soon as possible if signs of motor neuropathy are present.	Hematin given at the initial signs of motor neuropathy may halt its progression; however, it has no effect on established motor deficits, which are the result of axonal degeneration. ⁷

Table 5. continued from previous page.

Manifestation	Treatment	Consideration/Other
Seizures	Administer short-acting benzodiazepine (e.g., midazolam) or magnesium. ⁸	A number of commonly used anti-seizure medications, incl phenytoin & sodium valproate, are contraindicated because of the risk of exacerbating an attack.
Status epilepticus or refractory seizures	Consider propofol.	For more prolonged control of seizures, the combination of gabapentin & propofol is effective & safe.
Repeat acute attacks &/or severe disease	Use givosiran prophylactically when recurrent attacks occur $\geq 4x/yr$.	Givosiran is currently only approved for persons w/frequent recurrent attacks to prevent attacks; its role in treatment of acute attacks remains to be evaluated.
	Suppress ovulation in females.	Use a GnRH agonist (leuprolide, nafarelin, others). ⁹
	Use hematin prophylactically.	Chronic use of hematin can lead to iron overload. ^{10, 11, 12, 13}
	Consider liver transplantation in selected cases.	<ul style="list-style-type: none"> The status of the disease in candidates for liver transplantation must be well documented biochemically. Candidates must not have responded to multiple courses of hematin & must demonstrate neurologic complication.

PBG = porphobilinogen

- Hyponatremia is characteristic and may be profound (serum sodium concentration <110 mEq/L), requiring urgent correction with due regard for the risk of central pontine myelinolysis.
- Aggressive administration of dextrose in water may cause the serum sodium concentration to drop to a critically low level.
- Hematin (350-mg vial) is reconstituted at the bedside as described in the package insert. Human albumin may be used in place of water (147 mL of a 25% albumin solution) to reduce the risk of a chemical phlebitis, which is the main side effect of hematin administration [Anderson et al 2006].
- The infusion is started without delay, as hematin in solution decays rapidly [Goetsch & Bissell 1986].
- The preparation is given into a large peripheral vein or via central line over 10-15 minutes to minimize the risk of phlebitis. The dose is weight based at 3-4 mg/kg; 200 mg once daily is appropriate for most individuals.
- An alternative in Europe and elsewhere is heme arginate (Normosang[®]; not available in the US).
- Return of function requires axonal regeneration and takes many months. Although it can be complete, some individuals have residual wrist drop or foot drop.
- This treatment has been used to control eclamptic seizures [Sadeh et al 1991].
- Oral contraceptives and progestins should be avoided.
- Treatment of iron overload is indicated when the serum ferritin exceeds 1,500 ng/mL.
- An oral chelator, such as deferasirox or deferi-prone, is convenient but causes side effects of gastric distress and nausea in some users.
- A small phlebotomy can be done with each hematin infusion, provided the hemoglobin is >10 g/dL. Withdrawal of 100 mL of blood is sufficient for maintaining iron balance, relative to the amount of iron in a 250-mg dose of injectable hematin.
- For those with a significant iron burden, withdrawal of 200 cc of blood with each hematin infusion will produce net negative iron balance.

Treatment with Givosiran

Givosiran is a delta-aminolevulinic acid synthase 1 (ALAS1)-directed small interfering RNA (siRNA) covalently linked to N-acetyl galactosamine (GalNAc) that is taken up selectively by hepatocytes, leading to destruction of ALAS1 mRNA and decreased ALAS1 protein levels within hepatocytes [Chan et al 2015]. It is currently approved in the US for prophylactic treatment in individuals with acute hepatic porphyria who experience at least four attacks per year.

A multinational Phase 3 study of givosiran in 94 individuals with acute hepatic porphyria showed the following [Balwani et al 2020]:

- Annualized attack rates were reduced by 74%.
- Sustained delta-aminolevulinic acid (ALA) and porphobilinogen (PBG) were reduced by 86% and 91%, respectively, relative to baseline during the six-month study.
- Half of affected individuals treated with givosiran experienced no acute attacks during the six-month study, compared with 17% of affected individuals on placebo.
- Most common side effects reported were injection site reactions. Serious adverse events observed more frequently with givosiran included increased serum transaminases and decreased estimated glomerular filtration rate (eGFR).

Of note, only two individuals with HCP were included in the givosiran Phase 3 study. Individuals on givosiran can still experience acute attacks, and these should still be treated with hematin therapy.

Chronic (Cutaneous) Manifestations

Table 6. Treatment of Low-Grade Chronic or Seasonal Cutaneous Symptoms in Individuals with Hereditary Coproporphyrria

Treatment	Consideration/Other
Avoid sun/light.	This includes both direct sun/light & through window glass. ¹
Wear protective clothing: long sleeves, gloves, & wide-brimmed hats.	Topical sunscreens are not helpful because they block UVB light, not the blue light that causes porphyrin-related skin injury.
Use protective tinted glass for cars & windows to prevent exposure to blue light.	Gray or smoke-colored filters provide only partial protection.

1. Damage is caused by blue light and long-wave ultraviolet light (UVA), both of which pass through window glass.

Note: The association of cutaneous manifestations with severe attacks (in which porphyrins as well as ALA and PBG are markedly increased) suggests that the cutaneous as well as the neurovisceral symptoms could respond to hematin administration. Indeed, this is the finding of a case report of an individual with severe HCP who was given "maintenance" hematin [Ma et al 2011].

Prevention of Primary Manifestations

Table 7. Prevention of Acute Attacks in COPX Heterozygotes

Principle	Prevention	Consideration/Other
Identifying those at risk of attacks	See Evaluation of Relatives at Risk.	
Education of at-risk persons	Educate re circumstances that may trigger an acute attack (see Clinical Description).	
Selection of appropriate contraception for females	Recommended method of birth control for HCP heterozygotes: IUD plus a barrier (diaphragm &/or condom) ¹	<ul style="list-style-type: none"> • A copper-releasing IUD is theoretically the safest in women w/porphyria. • A hormone-releasing IUD may also be safe because the systemic ↑ in hormone is quite small; however, little information exists on its use in women w/acute porphyria.
	Suppress menses using a GnRH agonist.	<ul style="list-style-type: none"> • Leuprolide, nafarelin, & other GnRH agonists may help those who experience monthly exacerbations. • If menopausal side effects occur, they can be treated by adding low-dose estrogen. ²

Table 7. continued from previous page.

Principle	Prevention	Consideration/Other
Prevention of acute attacks in those undergoing surgery	Minimize preoperative fast as much as possible.	
	Provide intravenous glucose (10% dextrose in half-normal saline) in perioperative period.	
	Induce anesthesia using non-barbiturate agents that have little or no P450-inducing activity (e.g., propofol, ketamine, short-acting benzodiazepines).	Inhalation agents (isoflurane) & muscle relaxants also appear to be low-risk for triggering an attack.

GnRH = gonadotropin-releasing hormone; IUD = intrauterine device

1. Oral contraceptives (birth control pills) are risky and not recommended.

2. Andersson et al [2003]

Prevention of acute attacks *does not* involve the following:

- **Use of glucose.** Because glucose is used to treat acute attacks, its use in *preventing* attacks has been suggested, and is in fact touted in lay discussions of porphyria; however, there is no evidence that heterozygotes can protect themselves by overeating or adopting a high-carbohydrate diet, and they risk becoming obese. Heterozygotes should adhere to a healthful diet with the usual balance of protein, fat, and carbohydrate. Weight loss is possible but only by incremental restriction of calories combined with exercise. Extreme diets (e.g., all bacon, all brown rice, starvation) are risky and should be avoided.
- **Liver transplantation.** Because the vast majority of attacks respond to hematin and other supportive measures, liver transplantation has no role in prevention of acute attacks in a *CPOX* heterozygote.

Surveillance

For those who have chronically elevated ALA (which is infrequent in those who are asymptomatic) and/or are older than age 60 years, an annual assessment of liver and kidney function is recommended.

Current noninvasive techniques for evaluation of fibrosis in the liver include transient elastography (FibroScan[®]) and a blood-based test (FibroTest[®] or FibroSure[®]) [see Balwani et al 2017]. Note: These assessments have been vetted mainly for people with chronic viral hepatitis or steatohepatitis but may also be useful in porphyria.

For affected individuals older than age 60 and anyone with evidence of chronic liver injury, annual screening for hepatocellular carcinoma with abdominal imaging (e.g., ultrasound) and serum alpha-fetoprotein is indicated [Balwani et al 2017].

Agents/Circumstances to Avoid

Avoid the following:

- **Extreme caloric deprivation** (i.e., total fasting, gastric bypass surgery). A case report of an acute attack occurring in a 23-year-old male who had been taking Hydroxycut[®], an over-the-counter weight loss supplement, has been published [Haimowitz et al 2015].
- **Female reproductive hormones.** For recommendations regarding contraception, see Prevention of Primary Manifestations.
- **Medications.** Some drugs are clearly unsafe for *CPOX* heterozygotes. It is important to note, however, that many other drugs are safe. Providers should not regard individuals with acute porphyria as "untreatable."

Compilations of safe and unsafe drugs are available online and are updated as new information becomes available. See porphyriafoundation.org, drugs-porphyrria.org, or the smartphone app found at porphyriadrugs.com.

In theory, the most dangerous medications are inducers of CYPs, such as barbiturates and the related compound, phenytoin.

Evaluation of Relatives at Risk

It is appropriate to evaluate relatives at risk for HCP in order to identify as early as possible those who would benefit from education regarding the risk factors associated with acute attacks.

- If the *CPOX* pathogenic variant in the family is known, molecular genetic testing can be used to clarify the genetic status of at-risk relatives.
- If the *CPOX* pathogenic variant in the family is not known, a first-degree relative with symptoms can be evaluated with biochemical tests (see Diagnosis). Note: Although some *CPOX* heterozygotes have a diagnostic biochemical profile of heme precursors in urine and feces (see Table 1, **Active** columns), many have normal findings (see Table 1, **Asx** [asymptomatic] columns) and can only be diagnosed by molecular genetic testing.

See Genetic Counseling for issues related to testing of at-risk relatives for genetic counseling purposes.

Pregnancy Management

The effect of pregnancy on inducing acute attacks is unpredictable. In general, serious problems during pregnancy are unusual. In fact, some women with recurrent symptoms associated with the menstrual cycle report improvement during pregnancy. Attacks, if they occur, are usually in the first trimester. The women most at risk are those with hyperemesis gravidarum and inadequate caloric intake [Aggarwal et al 2002]. Among antiemetics, ondansetron is not expected to precipitate or exacerbate acute attacks, although several studies have suggested that ondansetron exposure in the first trimester of pregnancy could lead to an increased risk of cleft palate and/or congenital heart defects in the fetus. These suggested risks have not been confirmed. However, metoclopramide should be avoided, as it may precipitate acute attacks [Shenhav et al 1997].

The experience with administration of hematin (or heme arginate, which is not available in the US) during pregnancy is limited. Badminton & Deybach [2006] published an anecdotal report of successful heme arginate treatment (without adverse fetal effect) in several women experiencing attacks of variegate porphyria or other acute porphyrias during pregnancy. Based on the absence of reported adverse effects, use of hematin to control exacerbations of acute intermittent porphyria during pregnancy has been recommended [Isenschmid et al 1992, Farfaras et al 2010].

No human pregnancies have been reported during or after treatment with givosiran. In animal studies of reproduction, doses of givosiran that caused maternal toxicity in rabbits also resulted in adverse developmental outcomes. In pregnant rats, givosiran given at doses up to 30 mg/kg did not cause developmental defects in the offspring. There are no data on the presence of givosiran in human milk. Women with HCP should discuss the risks and benefits of continuing givosiran with their physician prior to conception.

See [MotherToBaby](#) for further information on medication use during pregnancy.

Therapies Under Investigation

Hematin for infusion (Panhematin[®], Recordati Group) is currently the only approved therapy for symptomatic acute porphyria and is a critical part of management. However, it has shortcomings: poor stability in solution;

the need for intravenous administration with the attendant risk of phlebitis; interference with coagulation; and iron overload.

Alternatives are under investigation. One is gene therapy in which the normal gene (*CPOX* in the case of hereditary coproporphyrria) is targeted to hepatocytes (ClinicalTrials.gov Identifier [NCT02082860](#)).

Search [ClinicalTrials.gov](#) in the US and [EU Clinical Trials Register](#) in Europe for information on clinical studies for a wide range of diseases and conditions.

Genetic Counseling

Genetic counseling is the process of providing individuals and families with information on the nature, mode(s) of inheritance, and implications of genetic disorders to help them make informed medical and personal decisions. The following section deals with genetic risk assessment and the use of family history and genetic testing to clarify genetic status for family members; it is not meant to address all personal, cultural, or ethical issues that may arise or to substitute for consultation with a genetics professional. —ED.

Mode of Inheritance

Hereditary coproporphyrria (HCP) is inherited in an autosomal dominant manner.

Risk to Family Members

- Most individuals with HCP have an affected parent.
- A proband with HCP may harbor a *de novo* *CPOX* pathogenic variant. The proportion of HCP caused by a *de novo* pathogenic variant is unknown.
- Recommendations for the evaluation of parents of a proband with an apparent *de novo* pathogenic variant include molecular genetic testing for the *CPOX* pathogenic variant identified in the proband.
- Evaluation of parents may determine that one has a *CPOX* pathogenic variant but has not been previously diagnosed because of reduced penetrance. Therefore, an apparently negative family history cannot be confirmed until molecular genetic testing has been performed.

Sibs of a proband

- The risk to the sibs of the proband depends on the genetic status of the proband's parents.
- If a parent of the proband is heterozygous for the *CPOX* pathogenic variant identified in the proband, the risk to the sibs of inheriting the *CPOX* pathogenic variant is 50%. Because of reduced penetrance, many individuals heterozygous for a *CPOX* pathogenic variant do not manifest signs and symptoms of HCP.
- If the *CPOX* pathogenic variant found in the proband cannot be detected in either parent, the risk to sibs is low but greater than that of the general population because of the possibility of germline mosaicism.

Offspring of a proband. Each child of an individual with HCP has a 50% chance of inheriting the *CPOX* pathogenic variant. Because of reduced penetrance, many individuals with a *CPOX* pathogenic variant do not manifest signs and symptoms of HCP.

Other family members. The risk to other family members depends on the status of the proband's parents: if a parent is heterozygous for a *CPOX* pathogenic variant, the parent's family members may be at risk.

Related Genetic Counseling Issues

See Management, Evaluation of Relatives at Risk for information on evaluating at-risk relatives for the purpose of early diagnosis and treatment.

Considerations in families with an apparent *de novo* pathogenic variant. When neither parent of a proband with HCP has the *CPOX* pathogenic variant or clinical evidence of the disorder, the *CPOX* pathogenic variant is likely *de novo*. However, non-medical explanations including alternate paternity or maternity (e.g., with assisted reproduction) or undisclosed adoption could also be considered.

Testing of at-risk asymptomatic relatives of individuals with HCP is possible after molecular genetic testing has identified the specific *CPOX* pathogenic variant in the family. Such testing should be performed in the context of formal genetic counseling. The results of molecular genetic testing are not useful in predicting age of onset, severity, or specific symptoms. Note: Although some *CPOX* heterozygotes have a diagnostic biochemical profile of heme precursors in urine and feces (see Table 1, **Active** columns), many have normal biochemical test results (see Table 1, **Asx** [asymptomatic] columns) and can be diagnosed only by molecular genetic testing.

Family planning

- The optimal time for determination of genetic risk and discussion of the availability of prenatal/preimplantation genetic testing is before pregnancy.
- It is appropriate to offer genetic counseling (including discussion of potential risks to offspring and reproductive options) to young adults who are affected or at risk.

DNA banking. Because it is likely that testing methodology and our understanding of genes, pathogenic mechanisms, and diseases will improve in the future, consideration should be given to banking DNA from probands in whom a molecular diagnosis has not been confirmed (i.e., the causative pathogenic mechanism is unknown).

Prenatal Testing and Preimplantation Genetic Testing

Once the *CPOX* pathogenic variant has been identified in an affected family member, prenatal and preimplantation genetic testing for HCP are possible.

Differences in perspective may exist among medical professionals and within families regarding the use of prenatal testing. While most centers would consider use of prenatal testing to be a personal decision, discussion of these issues may be helpful. Parents are encouraged to seek genetic counseling before reaching a decision on the use of prenatal testing.

Note: The presence of a *CPOX* pathogenic variant detected by prenatal testing does not predict whether individuals will be symptomatic, or if they are, what the severity of the clinical manifestations will be. It is common for the offspring who inherit the *CPOX* pathogenic variant from a severely affected individual to be completely asymptomatic.

Resources

GeneReviews staff has selected the following disease-specific and/or umbrella support organizations and/or registries for the benefit of individuals with this disorder and their families. GeneReviews is not responsible for the information provided by other organizations. For information on selection criteria, click [here](#).

- **American Porphyria Foundation (APF)**
Phone: 866-APF-3635
Email: general@porphyriafoundation.org
www.porphyriafoundation.org
- **British Porphyria Association**

United Kingdom

Phone: 0300 30 200 30

Email: helpline@porphyria.org.uk

www.porphyria.org.uk

- **Canadian Association for Porphyria/Association Canadienne de Porphyrie**

Canada

www.canadianassociationforporphyria.ca

- **Find a Porphyria Expert**

American Porphyria Foundation

www.porphyriafoundation.org/for-patients/porphyria-experts

- **MedlinePlus**

[Porphyria](#)

- **Porphyria South Africa**

South Africa

Phone: +27 21-4066332

Fax: +27 21-4066061

Email: Peter.Meissner@uct.ac.za

[Porphyria for Patients](#)

- **United Porphyrias Association**

Phone: 800-868-1292

Email: info@porphyria.org

www.porphyria.org

- **Welsh Medicines Information Centre**

The Welsh Medicines Information Centre (WMIC) offers a specialist advisory service on the safe use of drugs in porphyria.

United Kingdom

Phone: +44 029 2074 4298

[Drugs considered SAFE in the acute porphyrias](#)

- **Global Porphyria Advocacy Coalition**

[GPAC](#)

- **International Porphyria Network**

Email: contact@porphyria.eu

porphyria.eu

- **Swedish Porphyria Association**

Sweden

Phone: +46730803820

Email: porfyrisjukdomar@gmail.com

www.porfyri.se

Molecular Genetics

Information in the Molecular Genetics and OMIM tables may differ from that elsewhere in the GeneReview: tables may contain more recent information. —ED.

Table A. Hereditary Coproporphyrria: Genes and Databases

Gene	Chromosome Locus	Protein	Locus-Specific Databases	HGMD	ClinVar
CPOX	3q11.2	Oxygen-dependent coproporphyrinogen-III oxidase, mitochondrial	CPOX database	CPOX	CPOX

Data are compiled from the following standard references: gene from [HGNC](#); chromosome locus from [OMIM](#); protein from [UniProt](#). For a description of databases (Locus Specific, HGMD, ClinVar) to which links are provided, click [here](#).

Table B. OMIM Entries for Hereditary Coproporphyrria ([View All in OMIM](#))

121300	COPROPORPHYRIA, HEREDITARY; HCP
612732	COPROPORPHYRINOGEN OXIDASE; CPOX

Gene structure. *CPOX* comprises seven exons; the reference sequence of the transcript is [NM_000097.5](#). For a detailed summary of gene and protein information, see Table A, **Gene**.

Pathogenic variants. Pathogenic variants in all seven exons have been identified in persons with HCP (Human Gene Mutation Database, updated from Rosipal et al [1999]). They include missense and nonsense variants, small deletions, insertions, indels, splice variants, and large deletions.

Normal gene product. Coproporphyrinogen-III oxidase (synonyms: coproporphyrinogen oxidase and coproporphyrinogen decarboxylase), the product of *CPOX*, performs an oxidative decarboxylation without a metal, reducing agents, or obligatory cofactors. The details of this unusual reaction remain to be elucidated. The crystal structure of human coproporphyrinogen-III oxidase points to a dimer as the catalytically active unit.

Abnormal gene product. Some *CPOX* pathogenic variants likely alter enzyme activity by disrupting dimer formation [Lee et al 2005].

The 110-residue N-terminal segment is responsible for targeting the enzyme to mitochondria and is the site of its action on the substrate, coproporphyrinogen. Pathogenic variants in this region may affect translocation of the protein and, thus, reduce enzymatic function in tissues without changing activity in cell extracts.

Chapter Notes

Acknowledgments

The work has been carried out under the auspices of the Porphyrria Rare Disease Clinical Research Consortium (KE Anderson, Galveston, TX; DM Bissell, San Francisco, CA; JR Bloomer, Birmingham AL; HL Bonkowsky, Charlotte, NC; RJ Desnick, New York, NY; and JD Phillips, Salt Lake City, UT). The Consortium receives essential support from the NIH/NIDDK (1 U54 DK083909) and the American Porphyrria Foundation.

Author History

D Montgomery Bissell, MD (2012-present)

Theora Cimino, BS; University of California San Francisco (2012-2015)

Jennifer Lai, MD; University of California San Francisco (2012-2018)

Bruce Wang, MD (2012-present)

Revision History

- 19 May 2022 (bp) Revision: added information about givosiran, an FDA-approved prophylactic treatment for individuals with HCP with frequent recurrent acute neurovisceral pain episodes, in Treatment of Manifestations
- 8 November 2018 (ma) Comprehensive update posted live
- 1 July 2015 (me) Comprehensive update posted live
- 13 December 2012 (me) Review posted live
- 9 April 2012 (mb/bw) Original submission

References

Literature Cited

- Aggarwal N, Bagga R, Sawhney H, Suri V, Vasishta K. Pregnancy with acute intermittent porphyria: a case report and review of literature. *J Obstet Gynaecol Res.* 2002;28:160–2. PubMed PMID: 12214832.
- Akagi R, Inoue R, Muranaka S, Tahara T, Taketani S, Anderson KE, Phillips JD, Sassa S. Dual gene defects involving delta-aminolaevulinate dehydratase and coproporphyrinogen oxidase in a porphyria patient. *Br J Haematol.* 2006;132:237–43. PubMed PMID: 16398658.
- Anderson KE, Bloomer JR, Bonkovsky HL, Kushner JP, Pierach CA, Pimstone NR, Desnick RJ. Recommendations for the diagnosis and treatment of the acute porphyrias. *Ann Intern Med.* 2005;142:439–50. PubMed PMID: 15767622.
- Anderson KE, Bonkovsky HL, Bloomer JR, Shedlofsky SI. Reconstitution of hematin for intravenous infusion. *Ann Intern Med.* 2006;144:537–8. PubMed PMID: 16585674.
- Andersson C, Innala E, Bäckström T. Acute intermittent porphyria in women: clinical expression, use and experience of exogenous sex hormones. A population-based study in northern Sweden. *J Intern Med.* 2003;254:176–83. PubMed PMID: 12859699.
- Badminton MN, Deybach JC. Treatment of an acute attack of porphyria during pregnancy. *Eur J Neurol.* 2006;13:668–9. PubMed PMID: 16796597.
- Balwani M, Sardh E, Ventura P, Peiró PA, Rees DC, Stölzel U, Bissell DM, Bonkovsky HL, Windyga J, Anderson KE, Parker C, Silver SM, Keel SB, Wang JD, Stein PE, Harper P, Vassiliou D, Wang B, Phillips J, Ivanova A, Langendonk JG, Kauppinen R, Minder E, Horie Y, Penz C, Chen J, Liu S, Ko JJ, Sweetser MT, Garg P, Vaishnav A, Kim JB, Simon AR, Gouya L, et al. Phase 3 trial of RNAi therapeutic givosiran for acute intermittent porphyria. *N Engl J Med.* 2020;382:2289–301. PubMed PMID: 32521132.
- Balwani M, Wang B, Anderson KE, Bloomer JR, Bissell DM, Bonkovsky HL, Phillips JD, Desnick RJ, et al. Acute hepatic porphyrias: recommendations for evaluation and long-term management. *Hepatology.* 2017;66:1314–22. PubMed PMID: 28605040.
- Barbaro M, Kotajärvi M, Harper P, Floderus Y. Identification of an AluY-mediated deletion of exon 5 in the CPOX gene by MLPA analysis in patients with hereditary coproporphyrria. *Clin Genet.* 2012;81:249–56. PubMed PMID: 21231929.

- Billing BH. Twenty-five years of progress in bilirubin metabolism (1952-77). *Gut*. 1978;19:481–91. PubMed PMID: 98394.
- Bissell DM, Lai JC, Meister RK, Blanc PD. Role of delta-aminolevulinic acid in the symptoms of acute porphyria. *Am J Med*. 2015;128:313–7. PubMed PMID: 25446301.
- Blake D, McManus J, Cronin V, Ratnaïke S. Fecal coproporphyrin isomers in hereditary coproporphyria. *Clin Chem*. 1992;38:96–100. PubMed PMID: 1733615.
- Bonkovsky HL, Siao P, Roig Z, Hedley-Whyte ET, Flotte TJ. Case records of the Massachusetts General Hospital. Case 20-2008. A 57-year-old woman with abdominal pain and weakness after gastric bypass surgery. *N Engl J Med*. 2008;358:2813–25. PubMed PMID: 18579817.
- Brodie MJ, Thompson GG, Moore MR, Beattie AD, Goldberg A. Hereditary coproporphyria. Demonstration of the abnormalities in haem biosynthesis in peripheral blood. *Q J Med*. 1977;46:229–41. PubMed PMID: 866576.
- Chan A, Liebow A, Yasuda M, Gan L, Racie T, Maier M, Kuchimanchi S, Foster D, Milstein S, Charisse K, Sehgal A, Manoharan M, Meyers R, Fitzgerald K, Simon A, Desnick RJ, Querbes W. Preclinical development of a subcutaneous ALAS1 RNAi therapeutic for treatment of hepatic porphyrias using circulating RNA quantification. *Mol Ther Nucleic Acids*. 2015;4:e263. PubMed PMID: 26528940.
- Dowman JK, Gunson BK, Bramhall S, Badminton MN, Newsome PN. Liver transplantation from donors with acute intermittent porphyria. *Ann Intern Med*. 2011;154:571–2. PubMed PMID: 21502660.
- Farfaras A, Zagouri F, Zografos G, Kostopoulou A, Sergentanis TN, Antoniou S. Acute intermittent porphyria in pregnancy: a common misdiagnosis. *Clin Exp Obstet Gynecol*. 2010;37:256–60. PubMed PMID: 21355451.
- Gibson PR, Grant J, Cronin V, Blake D, Ratnaïke S. Effect of hepatobiliary disease, chronic hepatitis C and hepatitis B virus infections and interferon-alpha on porphyrin profiles in plasma, urine and faeces. *J Gastroenterol Hepatol*. 2000;15:192–201. PubMed PMID: 10735544.
- Goetsch CA, Bissell DM. Instability of hematin used in the treatment of acute hepatic porphyria. *N Engl J Med*. 1986;315:235–8. PubMed PMID: 3724815.
- Grimes R, Gillece Y, Appleby T, Stockwell S, Pinto-Sander N, Sahabandu T, Stein P, Bradshaw D. A case of hereditary coproporphyria precipitated by efavirenz. *AIDS*. 2016;30:2142–3. PubMed PMID: 27465283.
- Haimowitz S, Hsieh J, Shcherba M, Averbukh Y. Liver failure after Hydroxycut™ use in a patient with undiagnosed hereditary coproporphyria. *J Gen Intern Med*. 2015;30:856–9. PubMed PMID: 25666208.
- Hasanoglu A, Balwani M, Kasapkara CS, Ezgü FS, Okur I, Tümer L, Cakmak A, Nazarenko I, Yu C, Clavero S, Bishop DF, Desnick RJ. Harderoporphyria due to homozygosity for coproporphyrinogen oxidase missense mutation H327R. *J Inherit Metab Dis*. 2011;34:225–31. PubMed PMID: 21103937.
- Hasegawa K, Tanaka H, Yamashita M, Higuchi Y, Miyai T, Yoshimoto J, Okada A, Suzuki N, Iwatsuki K, Tsukahara H. Neonatal-onset hereditary coproporphyria: a new variant of hereditary coproporphyria. *JIMD Rep*. 2017;37:99–106. PubMed PMID: 28349448.
- Isenschmid M, König C, Fässli C, Haenel A, Hänggi W, Schneider H. Acute intermittent porphyria in pregnancy: glucose or hematin therapy? *Schweiz Med Wochenschr*. 1992;122:1741–5. PubMed PMID: 1448679.
- Jara-Prado A, Yescas P, Sánchez FJ, Ríos C, Garnica R, Alonso E. Prevalence of acute intermittent porphyria in a Mexican psychiatric population. *Arch Med Res*. 2000;31:404–8. PubMed PMID: 11068084.
- Kühnel A, Gross U, Doss MO. Hereditary coproporphyria in Germany: clinical-biochemical studies in 53 patients. *Clin Biochem*. 2000;33:465–73. PubMed PMID: 11074238.
- Lambie D, Florkowski C, Sies C, Raïzis A, Siu WK, Towns C. A case of hereditary coproporphyria with posterior reversible encephalopathy and novel coproporphyrinogen oxidase gene mutation c.863T>G (p.Leu288Trp). *Ann Clin Biochem*. 2018;55:616–19. PubMed PMID: 29660996.

- Lamoril J, Puy H, Whatley SD, Martin C, Woolf JR, Da Silva V, Deybach JC, Elder GH. Characterization of mutations in the CPO gene in British patients demonstrates absence of genotype-phenotype correlation and identifies relationship between hereditary coproporphyrria and harderoporphyria. *Am J Hum Genet.* 2001;68:1130–8. PubMed PMID: 11309681.
- Lee DS, Flachsová E, Bodnárová M, Demeler B, Martásek P, Raman CS. Structural basis of hereditary coproporphyrria. *Proc Natl Acad Sci U S A.* 2005;102:14232–7. PubMed PMID: 16176984.
- Ma E, Mar V, Varigos G, Nicoll A, Ross G. Haem arginate as effective maintenance therapy for hereditary coproporphyrria. *Australas J Dermatol.* 2011;52:135–8. PubMed PMID: 21605099.
- Rosipal R, Lamoril J, Puy H, Da Silva V, Gouya L, De Rooij FW, Te Velde K, Nordmann Y, Martásek P, Deybach JC. Systematic analysis of coproporphyrinogen oxidase gene defects in hereditary coproporphyrria and mutation update. *Hum Mutat.* 1999;13:44–53. PubMed PMID: 9888388.
- Sadeh M, Blatt I, Martonovits G, Karni A, Goldhammer Y. Treatment of porphyric convulsions with magnesium sulfate. *Epilepsia.* 1991;32:712–5. PubMed PMID: 1915181.
- Sardh E, Wahlin S, Björnstedt M, Harper P, Andersson DE. High risk of primary liver cancer in a cohort of 179 patients with acute hepatic porphyria. *J Inherit Metab Dis.* 2013;36:1063–71. PubMed PMID: 23344888.
- Schmitt C, Gouya L, Malonova E, Lamoril J, Camadro JM, Flamme M, Rose C, Lyoumi S, Da Silva V, Boileau C, Grandchamp B, Beaumont C, Deybach JC, Puy H. Mutations in human CPO gene predict clinical expression of either hepatic hereditary coproporphyrria or erythropoietic harderoporphyria. *Hum Mol Genet.* 2005;14:3089–98. PubMed PMID: 16159891.
- Shenhav S, Gemer O, Sassoon E, Segal S. Acute intermittent porphyria precipitated by hyperemesis and metoclopramide treatment in pregnancy. *Acta Obstet Gynecol Scand.* 1997;76:484–5. PubMed PMID: 9197454.
- Soonawalla ZF, Orug T, Badminton MN, Elder GH, Rhodes JM, Bramhall SR, Elias E. Liver transplantation as a cure for acute intermittent porphyria. *Lancet.* 2004;363:705–6. PubMed PMID: 15001330.
- Tran TP, Leduc K, Savard M, Dupré N, Rivest D, Nguyen DK. Acute porphyria presenting as epilepsy partialis continua. *Case Rep Neurol.* 2013;5:116–24. PubMed PMID: 23898283.
- van de Steeg E, Stránecký V, Hartmannová H, Nosková L, Hřebíček M, Wagenaar E, van Esch A, de Waart DR, Oude Elferink RP, Kenworthy KE, Sticová E, al-Edreesi M, Knisely AS, Kmoch S, Jirsa M, Schinkel AH. Complete OATP1B1 and OATP1B3 deficiency causes human Rotor syndrome by interrupting conjugated bilirubin reuptake into the liver. *J Clin Invest.* 2012;122:519–28. PubMed PMID: 22232210.
- van Tuyll van Serooskerken AM, de Rooij FW, Edixhoven A, Bladergroen RS, Baron JM, Jousen S, Merk HF, Steijlen PM, Poblete-Gutiérrez P, te Velde K, Wilson JH, Koole RH, van Geel M, Frank J. Digenic inheritance of mutations in the coproporphyrinogen oxidase and protoporphyrinogen oxidase genes in a unique type of porphyria. *J Invest Dermatol.* 2011;131:2249–54. PubMed PMID: 21734717.
- Vercesi AE, Castilho RF, Meinicke AR, Valle VG, Hermes-Lima M, Bechara EJ. Oxidative damage of mitochondria induced by 5-aminolevulinic acid: role of Ca²⁺ and membrane protein thiols. *Biochim Biophys Acta.* 1994;1188:86–92. PubMed PMID: 7947907.
- Whatley SD, Mason NG, Woolf JR, Newcombe RG, Elder GH, Badminton MN. Diagnostic strategies for autosomal dominant acute porphyrias: retrospective analysis of 467 unrelated patients referred for mutational analysis of the HMBS, CPOX, or PPOX gene. *Clin Chem.* 2009;55:1406–14. PubMed PMID: 19460837.

License

GeneReviews® chapters are owned by the University of Washington. Permission is hereby granted to reproduce, distribute, and translate copies of content materials for noncommercial research purposes only, provided that (i) credit for source (<http://www.genereviews.org/>) and copyright (© 1993-2024 University of Washington) are included with each copy; (ii) a link to the original material is provided whenever the material is published elsewhere on the Web; and (iii) reproducers, distributors, and/or translators comply with the [GeneReviews® Copyright Notice and Usage Disclaimer](#). No further modifications are allowed. For clarity, excerpts of GeneReviews chapters for use in lab reports and clinic notes are a permitted use.

For more information, see the [GeneReviews® Copyright Notice and Usage Disclaimer](#).

For questions regarding permissions or whether a specified use is allowed, contact: admasst@uw.edu.