



Urofacial Syndrome

Synonym: Ochoa Syndrome

William G Newman, MA, PhD, FRCP,¹ Adrian S Woolf, MA, MD,² Glenda M Beaman, PhD,¹ and Neil A Roberts, PhD²

Created: August 22, 2013; Updated: September 28, 2023.

Summary

Clinical characteristics

Urofacial syndrome (UFS; also known as Ochoa syndrome) is characterized by prenatal or childhood onset of urinary bladder voiding dysfunction, abnormal facial movement with expression (resulting from abnormal co-contraction of the corners of the mouth and eyes), and often bowel dysfunction (constipation and/or encopresis). Bladder voiding dysfunction can present before birth as megacystis. In infancy and later childhood, UFS can present with a poor urinary stream and dribbling incontinence; incomplete bladder emptying can lead to urinary infection with progressive kidney failure. Investigations after birth can show abnormal bladder contractility and vesicoureteral reflux of urine into the ureter and renal pelvis. Nocturnal lagophthalmos (incomplete closing of the eyes during sleep) has also been documented.

Diagnosis/testing

The clinical diagnosis of UFS can be established in an individual with urinary tract dysfunction and characteristic facial movement with expression, or the molecular diagnosis can be established in an individual with characteristic features and biallelic pathogenic variants in either *HPSE2* or *LRIG2* identified by molecular genetic testing.

Management

Treatment of manifestations: Rapid and complete antibiotic therapy for acute urinary tract infections. Anticholinergic and alpha-1 adrenergic blocking medications can respectively lower raised pressure within the bladder and enhance voiding of urine. Drug treatment can be complemented by intermittent catheterization per urethra or through vesicostomy. Management of kidney disease per nephrology; management of severe kidney failure may warrant long-term dialysis and kidney transplantation. Lubricant eye drops during the day and eye

Author Affiliations: 1 Manchester Centre for Genomic Medicine, Evolution, Infection and Genomics, University of Manchester and Manchester University NHS Foundation Trust, Manchester, United Kingdom; Email: william.newman@manchester.ac.uk; Email: glenda.beaman@manchester.ac.uk. 2 Division of Cell Matrix Biology & Regenerative Medicine University of Manchester, Manchester, United Kingdom; Email: adrian.woolf@manchester.ac.uk; Email: neil.roberts-2@manchester.ac.uk.

ointment at night under the care of an ophthalmologist for nocturnal lagophthalmos; standard management for constipation and encopresis.

Surveillance: Ultrasonography to monitor for evidence of urinary tract dysfunction including incomplete bladder emptying and hydronephrosis. Kidney excretory function should be monitored, initially by measuring plasma creatinine at intervals determined by urinary tract features at presentation and their subsequent progression. Ophthalmology examinations to assess for corneal involvement; assessment for bowel dysfunction annually or at each visit.

Agents/circumstances to avoid: Nephrotoxic substances.

Evaluation of relatives at risk: At-risk sibs: it is appropriate to examine sibs of an affected individual as soon as possible after birth to determine if facial and/or urinary tract manifestations of UFS are present to allow prompt evaluation of the urinary tract and renal function and initiation of necessary treatment. At-risk fetus: although no guidelines for prenatal management of UFS exist, it seems appropriate to perform ultrasound examination of pregnancies at risk (in the second and third trimesters) to determine if urinary tract involvement of UFS is present, as this may influence the timing and/or location of delivery (e.g., in a tertiary medical center that could manage renal/urinary complications immediately after birth).

Genetic counseling

UFS is inherited in an autosomal recessive manner. If both parents are known to be heterozygous for a UFS-related pathogenic variant, each sib of an affected individual has at conception a 25% chance of being affected, a 50% chance of being an asymptomatic carrier, and a 25% chance of being unaffected and not a carrier. Once the UFS-related pathogenic variants have been identified in an affected family member, carrier testing for at-risk relatives and prenatal and preimplantation genetic testing are possible.

Diagnosis

No formal diagnostic criteria for urofacial syndrome (UFS) have been published.

Suggestive Findings

UFS **should be suspected** in individuals with the following clinical findings and family history.

Classic clinical findings

- **Urinary bladder dysfunction** (also termed non-neurogenic neurogenic voiding dysfunction, occult or subclinical neuropathic bladder) with detrusor overactivity and detrusor sphincter dyssynergia [Feldman & Bauer 2006]. Affected individuals are at risk for urinary incontinence, urosepsis, and progressive kidney failure [Ochoa 2004, Aydogdu et al 2010, Stuart et al 2013]. Urinary tract features have been present in nearly all reported individuals [Aydogdu et al 2010, Stuart et al 2013, Stuart et al 2015, Beaman et al 2022, Grenier et al 2023].

Characteristic urinary tract abnormalities:

- Prenatal ultrasonography in the second or third trimester can show an enlarged bladder (megacystis) and dilated upper urinary tracts (hydronephrosis).
- Postnatal imaging by ultrasonography and micturating cystourethrography typically shows muscular thickening and trabeculation of the urinary bladder, but appearances may also be normal [Ochoa 1992, Ochoa 2004, Derbent et al 2009, Aydogdu et al 2010].
- Hydronephrosis associated with vesicoureteral reflux is common in UFS [Ochoa 1992, Ochoa 2004].

- Micturating cystourethrography and direct visualization by cystoscopy reveals a patent urethra, critically distinguishing UFS from conditions such as posterior urethral valves, which are characterized by an anatomic obstruction within the lumen of the urethra [Ochoa 2004].

Urodynamics is generally only available in specialist pediatric urology centers. If performed, typical findings are abnormally high hydrostatic pressure within the bladder that persists during cycles of incomplete voiding. This is associated with failure of the outflow tract to fully dilate during voiding, the so-called dyssynergic voiding [Ochoa 2004].

- **A characteristic abnormality of facial movement with expression**, resulting from abnormal co-contraction of the corners of the mouth and eyes, which is most obvious during smiling or laughing (see Figure 1) and often described as a "grimace" [Ochoa 2004, Aydogdu et al 2010, Ganesan & Thomas 2011]. Typical facial expressions have been present in nearly all affected individuals.

Other clinical findings

- **Bowel dysfunction**, including constipation (66%) and encopresis (33%) of affected individuals [Ochoa 2004]
- **Nocturnal lagophthalmos** (incomplete closing of the eyelids during sleep)

Family history is consistent with autosomal recessive inheritance (e.g., affected sibs and/or parental consanguinity). Absence of a known family history does not preclude the diagnosis.

Establishing the Diagnosis

The clinical diagnosis of UFS can be **established** in a proband with urinary bladder dysfunction and characteristic abnormality of facial movement with expression described in Suggestive Findings, or the molecular diagnosis can be established in a proband with suggestive findings and biallelic pathogenic (or likely pathogenic) variants in either *HPSE2* or *LRIG2* identified by molecular genetic testing (see Table 1).

Note: (1) Per ACMG/AMP variant interpretation guidelines, the terms "pathogenic variant" and "likely pathogenic variant" are synonymous in a clinical setting, meaning that both are considered diagnostic and can be used for clinical decision making [Richards et al 2015]. Reference to "pathogenic variants" in this section is understood to include likely pathogenic variants. (2) Identification of biallelic *HPSE2* or *LRIG2* variants of uncertain significance (or of one known *HPSE2* or *LRIG2* pathogenic variant and one *HPSE2* or *LRIG2* variant of uncertain significance) does not establish or rule out the diagnosis.

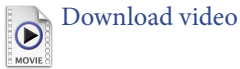
Molecular genetic testing approaches can include a combination of **gene-targeted testing** (serial single gene testing, concurrent gene testing, multigene panel) and **comprehensive genomic testing** (exome sequencing, genome sequencing). Gene-targeted testing requires that the clinician determine which gene(s) are likely involved (see Option 1), whereas comprehensive genomic testing does not (see Option 2).

Option 1

Serial single-gene testing. Sequence analysis of *HPSE2* is performed first to detect missense, nonsense, and splice site variants and small intragenic deletions/insertions. Note: Depending on the sequencing method used, single-exon, multiexon, or whole-gene deletions/duplications may not be detected. If only one or no pathogenic variants are identified on sequence analysis of *HPSE2*, perform gene-targeted deletion/duplication analysis to detect intragenic deletions or duplications [Beaman et al 2022]. If testing of *HPSE2* is non-diagnostic, perform sequence analysis of *LRIG2*.

Concurrent gene testing or a **multigene panel** that includes *HPSE2*, *LRIG2*, and other genes of interest (see Differential Diagnosis) may be considered to identify the genetic cause of the condition while limiting identification of variants of uncertain significance and pathogenic variants in genes that do not explain the

Figure 1. A video of a young man with urofacial syndrome demonstrating his facial appearance on smiling
Reproduced from Beaman et al [2022]



underlying phenotype. Note: (1) The genes included in the panel and the diagnostic sensitivity of the testing used for each gene vary by laboratory and are likely to change over time. (2) Some multigene panels may include genes not associated with the condition discussed in this *GeneReview*. (3) In some laboratories, panel options may include a custom laboratory-designed panel and/or custom phenotype-focused exome analysis that includes genes specified by the clinician. (4) Methods used in a panel may include sequence analysis, deletion/duplication analysis, and/or other non-sequencing-based tests.

Option 2

Comprehensive genomic testing does not require the clinician to determine which gene(s) are likely involved. **Exome sequencing** is most commonly used; **genome sequencing** is also possible.

For an introduction to comprehensive genomic testing click [here](#). More detailed information for clinicians ordering genomic testing can be found [here](#).

Table 1. Molecular Genetic Testing Used in Urofacial Syndrome

Gene ^{1, 2}	Proportion of UFS Attributed to Pathogenic Variants in Gene ³	Proportion of Pathogenic Variants ⁴ Detectable by Method	
		Sequence analysis ⁵	Gene-targeted deletion/duplication analysis ⁶
<i>HPSE2</i>	~64%	<85% ⁷	>15% ⁷
<i>LRIG2</i>	~20%	100% ⁷	See footnote 8.
Unknown	≤16%	NA	

NA = not applicable; UFS = urofacial syndrome

1. Genes are listed in alphabetic order.

2. See Table A. Genes and Databases for chromosome locus and protein.

3. Stuart et al [2013], Stuart et al [2015], Osorio et al [2021], Beaman et al [2022]

4. See Molecular Genetics for information on variants detected in this gene.

5. Sequence analysis detects variants that are benign, likely benign, of uncertain significance, likely pathogenic, or pathogenic. Variants may include small intragenic deletions/insertions and missense, nonsense, and splice site variants; typically, exon or whole-gene deletions/duplications are not detected. For issues to consider in interpretation of sequence analysis results, click [here](#).

6. Gene-targeted deletion/duplication analysis detects intragenic deletions or duplications. Methods used may include a range of techniques such as quantitative PCR, long-range PCR, multiplex ligation-dependent probe amplification (MLPA), and a gene-targeted microarray designed to detect single-exon deletions or duplications.

7. Data derived from the subscription-based professional view of Human Gene Mutation Database [Stenson et al 2020]

8. A large Alu insertion resulting in exon skipping in *LRIG2* has been reported [Stuart et al 2013].

Clinical Characteristics

Clinical Description

Urofacial syndrome (UFS) is characterized by urinary bladder voiding dysfunction, abnormal facial expression, and often bowel dysfunction. Significant inter- and intrafamilial phenotypic variability has been observed. To date, more than 150 individuals with UFS have been identified/reported. The following description of the phenotypic features associated with this condition is based on these reports.

Table 2. Urofacial Syndrome: Frequency of Select Features

Feature	% of Persons w/Feature	Comment
Urinary tract dysfunction	>98%	
Abnormal facial expression	>99%	Co-contraction of the corners of the mouth & eyes
Nocturnal lagophthalmos	Unknown	Incomplete closing of the eyes during sleep
Constipation	~66%	
Encopresis	~33%	

Urinary tract dysfunction is the main reason for presenting to medical attention and the main cause of associated morbidity and mortality. Urinary tract dysfunction has been present in all but two of more than 150 clinically defined individuals [Aydogdu et al 2010, Stuart et al 2013, Stuart et al 2015]. Antenatal ultrasound examination (if performed) is frequently described as abnormal and is associated with megacystis, hydroureteronephrosis, and renal pelvis dilatation [Skálová et al 2006, Bacchetta & Cochat 2010, Daly et al 2010, Stuart et al 2013]. In one large series, hydroureteronephrosis was found in 29/50 (58%) affected individuals. Vesicoureteral reflux occurred in 32/50 (64%); reflux was bilateral in 18 (36%) [Ochoa 1992, Ochoa 2004].

The typical complications of urinary tract dysfunction include recurrent urinary sepsis and failure to achieve urinary continence [Ochoa 1992, Ochoa 2004]. More severe complications of urinary tract dysfunction, including urinary bladder rupture and sepsis, have been reported in some infants [Ochoa 1992, Skálová et al 2006].

Kidney disease. The associated renal parenchymal damage with early impairment of kidney function and progression to severe kidney failure causes substantial morbidity and mortality [Ochoa 2004, Skálová et al 2006, Sutay et al 2010, Mahmood et al 2012]. The proportion of individuals who develop this is unknown but likely to be significant in the context of severe and recurrent urosepsis, especially if not promptly and completely treated with antibiotics [Ochoa & Gorlin 1987, Ochoa 1992, Ochoa 2004, Aydogdu et al 2010].

Abnormal facial expression. The most prominent facial feature, abnormal co-contraction of the corners of the mouth and eyes, is most obvious during smiling or laughing [Ochoa 2004, Aydogdu et al 2010, Ganesan & Thomas 2011] and can be socially debilitating. Abnormal facial movement with crying has been observed as early as the neonatal period [Ochoa 1992, Skálová et al 2006]. Rarely, affected individuals may have the typical facial phenotype with no urinary bladder dysfunction or symptoms [Stuart et al 2013; Authors, personal communication].

Symmetric partial facial paresis in the distribution of the facial nerve has been noted; however, the proportion of individuals in whom weakness is a significant feature is unknown [Garcia-Minaur et al 2001; Authors, personal observation].

Nocturnal lagophthalmos (incomplete closing of the eyes during sleep) appears to be a common and significant finding that may lead to keratitis, corneal abrasion, infection, vascularization, and, in extreme cases, ocular perforation, endophthalmitis, and loss of the eye [Mermerkaya et al 2014].

Gastrointestinal tract dysfunction. Constipation is reported in about 66% of affected individuals; encopresis is present in 33% [Ochoa 2004]. Fecal retention in the neonatal period has been noted once [Nicanor et al 2005]. Rectal prolapse has also been reported once in association with severe constipation [Al Badr et al 2011].

Central nervous system function is normal. Affected individuals do not typically show any other features of neurologic dysfunction besides nocturnal lagophthalmos. Development and intellect are normal. Brain MRI and imaging of the truncal spinal cord are typically normal [Nicanor et al 2005, Derbent et al 2009, Aydogdu et al 2010, Al Badr et al 2011, Akl & Al Momany 2012].

Genotype-Phenotype Correlations

There is evidence that individuals with biallelic missense variants in *LRIG2* have urinary tract-limited disease (i.e., lacking the characteristic facial expression) [Stuart et al 2013, Roberts et al 2019, Grenier et al 2023].

Prevalence

UFS is rare. Its prevalence is currently unknown but is likely to be higher in certain regions with known founder variants (e.g., Colombia) [Ochoa 2004, Pang et al 2010].

Genetically Related (Allelic) Disorders

No phenotypes other than those discussed in this *GeneReview* are known to be associated with pathogenic variants in *HPSE2* or *LRIG2*.

Differential Diagnosis

The urinary tract features of urofacial syndrome (UFS) overlap with those seen in association with multiple other conditions [Woolf et al 2014a].

Antenatal or congenital megacystis and/or hydronephrosis

- Urethral obstruction due to posterior urethral valves or atresia
- Chromosome abnormalities (e.g., megacystis in association with trisomy 21 and 13)
- Prune-belly sequence (e.g., caused by biallelic pathogenic variants in *CHRM3* or *MYOCD*) (See Table 3.)
- Megacystis microcolon intestinal hypoperistalsis syndrome, a heterogeneous condition resulting from smooth muscle dysfunction (See Table 3.)

Table 3. Monogenic Disorders with Antenatal or Congenital Megacystis and/or Hydronephrosis in the Differential Diagnosis of Urofacial Syndrome

Gene(s)	Disorder	MOI	GI/GU Involvement	Other Features
<i>ACTA2</i>	Multisystem smooth muscle dysfunction syndrome (OMIM 613834) (See also Heritable Thoracic Aortic Disease Overview .)	AD	Hypotonic bladder, ¹ cryptorchidism, malrotation & hypoperistalsis of the gut; ² prune-belly sequence may be associated. ³	Thoracic aortic aneurysms & aortic dissections, PDA, stenosis & dilatation of cerebral vessels, mydriasis, periventricular white matter hyperintensities on MRI, pulmonary hypertension
<i>ACTG2</i>	ACTG2 visceral myopathy (OMIM 619431)	AD ³	Mild-to-severe smooth muscle dysfunction of the bladder & GI system. <ul style="list-style-type: none"> • Bladder: neonatal megacystis & megaureter (incl prune-belly syndrome) to recurrent urinary tract infections & bladder dysfunction • GI: microcolon, CIPO, malrotation, functional intestinal obstruction 	
<i>CHRM3</i>	Prune-belly syndrome (OMIM 100100)	AR	Prune-belly sequence w/distended, areflexic/hyporeflexic bladder; hydroureter, hydronephrosis; cryptorchidism; constipation, posterior urethral valves ⁴	Mydriasis

Table 3. continued from previous page.

Gene(s)	Disorder	MOI	GI/GU Involvement	Other Features
<i>CHRNA3</i>	Bladder dysfunction, autonomic, w/ impaired pupillary reflex & secondary CAKUT (OMIM 191800)	AR	Impaired bladder innervation, thick bladder wall, neurogenic vesicoureteral reflux w/hydroureter, hydronephrosis; secondary small, cystic kidneys & chronic kidney disease, hypospadias	Impaired pupillary reflex
<i>EBF3</i>	EBF3 neurodevelopmental disorder (OMIM 617330)	AD	~30% of affected persons have renal or lower urinary tract features overlapping w/phenotype in urofacial syndrome. ⁵	Developmental delay, intellectual disability, speech delay, gait or truncal ataxia, hypotonia, behavioral issues, facial dysmorphism
<i>LMOD1</i>	<i>LMOD1</i> -related MMIHS	AR	Classic features of MMIHS (e.g., megacystis, microcolon, intestinal dysmotility)	
<i>MYH11</i>	<i>MYH11</i> -related MMIHS	AR	<ul style="list-style-type: none"> Overlapping features of MMIHS & prune-belly sequence (1 person) Overlapping features of MMIHS & MSMDS (1 person) 	PDA in 1 child ⁶
<i>MYL9</i>	<i>MYL9</i> -related MMIHS (OMIM 619365)	AR	MMIHS w/prune-belly sequence	Mydriasis; vascular smooth muscle dysfunction has not been reported.
<i>MYLK</i>	<i>MYLK</i> -related MMIHS (OMIM 249210)	AR	MMIHS	Familial thoracic aortic aneurysm & dissection, esp assoc w/hypertension
<i>MYOCD</i>	Congenital megabladder (OMIM 618719)	AD AR ⁷	Prune-belly sequence	Can be assoc w/thoracic aortic disease

AD = autosomal dominant; AR = autosomal recessive; CAKUT = congenital anomalies of the kidney and urinary tract; CIPO = chronic intestinal pseudo-obstruction; GI = gastrointestinal; GU = genitourinary; MMIHS = megacystis-microcolon-intestinal hyperperistalsis syndrome; MOI = mode of inheritance; MSMDS = multisystem smooth muscle dysfunction syndrome; PDA = patent ductus arteriosus

1. The bladder phenotype is associated specifically with the heterozygous *de novo* variant p.Arg179His [Milewicz et al 2010].

2. Milewicz et al [2010]

3. Richer et al [2012]

4. *ACTG2* visceral myopathy is typically inherited in an autosomal dominant manner. Apparent autosomal recessive inheritance was suggested in one family.

5. Harkness et al [2020]

6. Gauthier et al [2015]

7. Sex-limited inheritance: disorder is lethal in males with heterozygous pathogenic variants, females only have manifestations of the disorder if they have biallelic pathogenic variants.

Urinary bladder voiding dysfunction

- Neuropathic bladder (e.g., due to a neurologic lesion such as spina bifida)
- Voiding dysfunction of unclear etiology, variably termed occult neuropathic bladder, subclinical neuropathic bladder, non-neurogenic neurogenic bladder, and Hinman-Allen syndrome

Primary nonsyndromic vesicoureteral reflux

- Common in the general population
- May be familial and is genetically heterogeneous [Darlow et al 2017]

Management

No clinical practice guidelines for urofacial syndrome (UFS) have been published.

Evaluations Following Initial Diagnosis

To establish the extent of disease and needs in an individual diagnosed with UFS, the evaluations summarized in Table 4 (if not performed as part of the evaluation that led to the diagnosis) are recommended.

Table 4. Urofacial Syndrome: Recommended Evaluations Following Initial Diagnosis

System/Concern	Evaluation	Comment
Urinary tract dysfunction	<ul style="list-style-type: none"> Urinalysis & urine culture for those w/manifestations of occult or chronic urinary tract infection Urinary tract ultrasound Micturating cystourethrogram Uroflowmetry or urodynamic testing 	
Kidney disease	<ul style="list-style-type: none"> Serum creatinine concentration &/or estimated glomerular filtration rate Blood pressure measurement 	
	Assessment of kidney parenchymal damage: as indicated by the affected person's presentation, DMSA isotope scan to visualize non-functional kidney parenchyma (i.e., scars) combined w/ ultrasonography to detect thinned kidney cortex ¹	
Nocturnal lagophthalmos	Ophthalmologic exam for evidence of nocturnal lagophthalmos	
Constipation	Assessment of bowel emptying	
Genetic counseling	By genetics professionals ¹	To inform affected persons & their families re nature, MOI, & implications of UFS to facilitate medical & personal decision making

DMSA = dimercaptosuccinic acid; MOI = mode of inheritance; UFS = urofacial syndrome

1. Ochoa [2004], Aydogdu et al [2010], Stuart et al [2013]

2. Medical geneticist, certified genetic counselor, certified advanced genetic nurse

Treatment of Manifestations

Supportive care to improve quality of life, maximize function, and reduce complications is recommended. This ideally involves multidisciplinary care by specialists in relevant fields (see Table 5).

Table 5. Urofacial Syndrome: Treatment of Manifestations

Manifestation/Concern	Treatment	Considerations/Other
Urinary tract dysfunction	<ul style="list-style-type: none"> Rapid & complete antibiotic therapy for acute urinary tract infections Anticholinergic & alpha-1 adrenergic blocking medications can respectively lower raised pressure w/in the bladder & enhance voiding of urine. Drug treatment can be complemented by intermittent catheterization per urethra or through vesicostomy to reduce residual urine volumes, achieve continence, & reduce risk of infections. 	No evidence-based guidelines exist for treatment of the urinary tract abnormalities of UFS.

Table 5. continued from previous page.

Manifestation/Concern	Treatment	Considerations/Other
Kidney disease	Mgmt as nephrologist to prevent or slow progression	Mgmt of severe kidney failure may warrant long-term dialysis & kidney transplantation.
Abnormal facial expression	Successful treatment w/botulinum toxin has been reported in a single person & requires further eval. ¹	
Nocturnal lagophthalmos	Typically under care of ophthalmologist: <ul style="list-style-type: none"> • Lubricant drops during day • Eye ointments at night 	To protect cornea from exposure keratopathy ²
Bowel dysfunction	Standard mgmt for constipation & encopresis	

UFS = urofacial syndrome

1. Barbon et al [2023]

2. Mermerkaya et al [2014]

Surveillance

To monitor existing manifestations, the individual's response to supportive care, and the emergence of new manifestations, the evaluations summarized in Table 6 are recommended.

Table 6. Urofacial Syndrome: Recommended Surveillance

System/Concern	Evaluation	Frequency
Urinary tract dysfunction	Ultrasonography to monitor for evidence of urinary tract dysfunction incl incomplete bladder emptying & hydroureteronephrosis	At least annually through childhood
Kidney disease	Assessment of kidney excretory function by measurement of plasma creatinine	Per nephrologist & determined by urinary tract features at presentation & disease progression
Nocturnal lagophthalmos	Ophthalmology exam to assess for evidence of significant corneal involvement	Recommended frequency is undetermined
Bowel dysfunction	Assess for constipation/encopresis by parental report	Annually or at each visit

Agents/Circumstances to Avoid

Nephrotoxic substances contraindicated in individuals with renal impairment should be avoided if possible.

Evaluation of Relatives at Risk

At-risk sibs of a proband. It is appropriate to clarify the genetic/clinical status of sibs of an affected individual as soon as possible after birth in order to identify those who would benefit from prompt evaluation of the urinary tract and renal function and early initiation of necessary treatment. Evaluations can include:

- Molecular genetic testing if the pathogenic variants in the family are known;
- Physical examination and urinary tract ultrasound examination to determine whether facial and/or urinary tract manifestations of UFS are present if the pathogenic variants in the family are not known.

At-risk fetus. Although no guidelines for prenatal management of UFS exist, it seems appropriate to perform ultrasound examination of pregnancies at risk (in the second and third trimesters) to determine if urinary tract

involvement of UFS is present in the fetus, as it may influence the timing and/or location of delivery (e.g., in a tertiary medical center that could manage renal/urinary complications immediately after birth).

See Genetic Counseling for issues related to testing of at-risk relatives for genetic counseling purposes.

Therapies Under Investigation

Studies of gene therapy to correct the urinary tract manifestations in mice with mutated *HPSE2* have been published and indicate that this may be a future therapeutic option (see [bioRxiv](#)).

Search [ClinicalTrials.gov](#) in the US and [EU Clinical Trials Register](#) in Europe for information on clinical studies for a wide range of diseases and conditions. Note: There may not be clinical trials for this disorder.

Genetic Counseling

Genetic counseling is the process of providing individuals and families with information on the nature, mode(s) of inheritance, and implications of genetic disorders to help them make informed medical and personal decisions. The following section deals with genetic risk assessment and the use of family history and genetic testing to clarify genetic status for family members; it is not meant to address all personal, cultural, or ethical issues that may arise or to substitute for consultation with a genetics professional. —ED.

Mode of Inheritance

Urofacial syndrome (UFS) is inherited in an autosomal recessive manner.

Risk to Family Members

Parents of a proband

- The parents of an affected child are presumed to be heterozygous for a UFS-related pathogenic variant.
- If a molecular diagnosis has been established in the proband, molecular genetic testing is recommended for the parents of the proband to confirm that both parents are heterozygous for a UFS-related pathogenic variant and to allow reliable recurrence risk assessment.
- If a pathogenic variant is detected in only one parent and parental identity testing has confirmed biological maternity and paternity, it is possible that one of the pathogenic variants identified in the proband occurred as a *de novo* event in the proband or as a postzygotic *de novo* event in a mosaic parent [Jónsson et al 2017]. If the proband appears to have homozygous pathogenic variants (i.e., the same two pathogenic variants), additional possibilities to consider include:
 - A single- or multiexon deletion in the proband that was not detected by sequence analysis and that resulted in the artifactual appearance of homozygosity;
 - Uniparental isodisomy for the parental chromosome with the pathogenic variant that resulted in homozygosity for the pathogenic variant in the proband.
- Heterozygotes (carriers) are asymptomatic and are not at risk of developing the disorder.

Sibs of a proband

- If both parents are known to be heterozygous for a UFS-related pathogenic variant, each sib of an affected individual has at conception a 25% chance of being affected, a 50% chance of being an asymptomatic carrier, and a 25% chance of being unaffected and not a carrier.
- Significant intrafamilial phenotypic variability has been observed [Ochoa 1992, Aydogdu et al 2010, Stuart et al 2013, Stuart et al 2015].
- Heterozygotes (carriers) are asymptomatic and are not at risk of developing the disorder.

Offspring of a proband. Unless the proband's reproductive partner also has UFS or is a carrier of UFS, offspring of a proband with *HPSE2*-related or *LRIG2*-related UFS will be obligate heterozygotes for an *HPSE2* or *LRIG2* pathogenic variant, respectively (i.e., all offspring are carriers of a pathogenic variant inherited from their parent).

Other family members. Each sib of the proband's parents is at a 50% risk of being a carrier of a UFS-related pathogenic variant.

Carrier Detection

Carrier testing for at-risk relatives requires prior identification of the UFS-related pathogenic variants in the family.

Related Genetic Counseling Issues

See Management, Evaluation of Relatives at Risk for information on evaluating at-risk relatives for the purpose of early diagnosis and treatment.

Family planning

- The optimal time for determination of genetic risk and discussion of the availability of prenatal/preimplantation genetic testing is before pregnancy.
- It is appropriate to offer genetic counseling (including discussion of potential risks to offspring and reproductive options) to young adults who are affected, are carriers, or are at risk of being carriers.
- Carrier testing should be considered for the reproductive partners of individuals affected with UFS and the reproductive partners of individuals known to be carriers of UFS, particularly if consanguinity is likely and/or if both partners are of the same ethnic background. An *HPSE2* founder variant has been identified in individuals of Colombian ancestry (see Table 7).

DNA banking. Because it is likely that testing methodology and our understanding of genes, pathogenic mechanisms, and diseases will improve in the future, consideration should be given to banking DNA from probands in whom a molecular diagnosis has not been confirmed (i.e., the causative pathogenic mechanism is unknown). For more information, see Huang et al [2022].

Prenatal Testing and Preimplantation Genetic Testing

Molecular genetic testing. Once the UFS-related pathogenic variants have been identified in an affected family member, prenatal and preimplantation genetic testing are possible.

Fetal ultrasonography. In families at risk of having an affected child, prenatal ultrasound of the urinary tract may show megacystis, hydroureteronephrosis, or renal pelvis dilatation in an affected pregnancy. These features are not specific for UFS.

Note: Ultrasound examination of a fetus at risk (in the second and third trimesters) to determine if UFS-related urinary tract involvement is present should be considered, as it may influence the timing and/or location of delivery (see Evaluations of Relatives at Risk).

Differences in perspective may exist among medical professionals and within families regarding the use of prenatal testing. While most centers would consider use of prenatal testing to be a personal decision, discussion of these issues may be helpful.

Resources

GeneReviews staff has selected the following disease-specific and/or umbrella support organizations and/or registries for the benefit of individuals with this disorder and their families. GeneReviews is not responsible for the information provided by other organizations. For information on selection criteria, click [here](#).

- **Genetic and Rare Diseases Information Center (GARD)**
Ochoa syndrome
- **MedlinePlus**
Ochoa Syndrome

Molecular Genetics

Information in the Molecular Genetics and OMIM tables may differ from that elsewhere in the GeneReview: tables may contain more recent information. —ED.

Table A. Urofacial Syndrome: Genes and Databases

Gene	Chromosome Locus	Protein	Locus-Specific Databases	HGMD	ClinVar
<i>HPSE2</i>	10q24.2	Inactive heparanase-2	HPSE2 database	HPSE2	HPSE2
<i>LRIG2</i>	1p13.2	Leucine-rich repeats and immunoglobulin-like domains protein 2		LRIG2	LRIG2

Data are compiled from the following standard references: gene from [HGNC](#); chromosome locus from [OMIM](#); protein from [UniProt](#). For a description of databases (Locus Specific, HGMD, ClinVar) to which links are provided, click [here](#).

Table B. OMIM Entries for Urofacial Syndrome ([View All in OMIM](#))

236730	UROFACIAL SYNDROME 1; UFS1
608869	LEUCINE-RICH REPEATS- AND IMMUNOGLOBULIN-LIKE DOMAINS-CONTAINING PROTEIN 2; LRIG2
613469	HEPARANASE 2; HPSE2
615112	UROFACIAL SYNDROME 2; UFS2

See Figure 2 and Figure 3 for a spectrum of known published pathogenic variants in *HPSE2* and *LRIG2* associated with UFS.

Molecular Pathogenesis

The molecular pathogenesis of urofacial syndrome (UFS) is not fully understood. However, there is increasing evidence that UFS represents an abnormality of peripheral neurodevelopment or function [Ganesan & Thomas 2011, Stuart et al 2013, Roberts et al 2014, Woolf et al 2014b, Stuart et al 2015, Roberts et al 2019].

Both *HPSE2* and its encoded protein (inactive heparanase-2) and *LRIG2* and its encoded protein (leucine-rich repeats and immunoglobulin-like domains protein 2, or LRIG2) are expressed and localize to the peripheral nervous system, including the developing nerves of the fetal bladder [McKenzie et al 2000, Guo et al 2004, Homma et al 2009, Daly et al 2010, Stuart et al 2013, Stuart et al 2015, Beaman et al 2022, Grenier et al 2023].

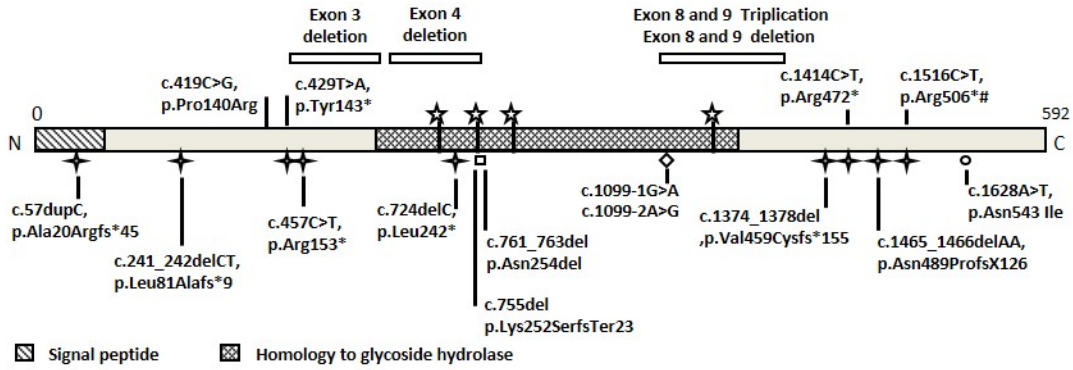


Figure 2. A graphic of *HPSE2* with all published pathogenic variants to date
Adapted from Beaman et al [2022]

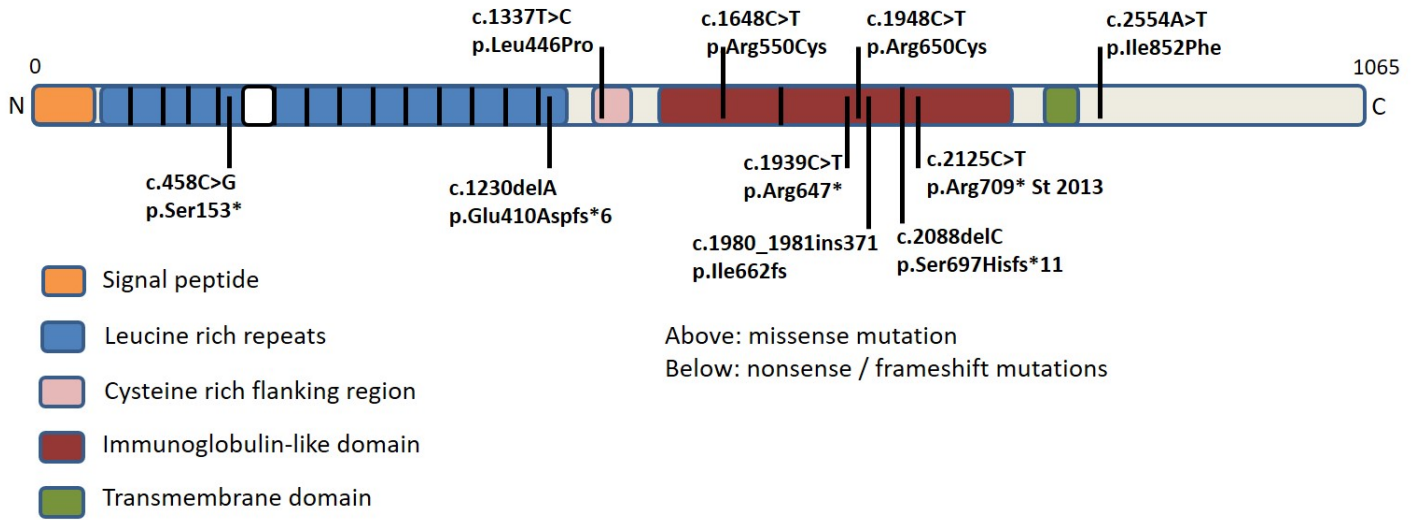


Figure 3. A graphic of *LRIG2* with all published pathogenic variants to date
Adapted from Grenier et al [2023]

While the functions of heparanase-2 and LRIG2 are not fully understood, current knowledge suggests that they have a role in regulating growth factor signaling [Hedman & Henriksson 2007; Fux et al 2009; Levy-Adam et al 2010; Pang et al 2010; Cui et al 2011; Authors, personal communication].

Mechanism of disease causation. Unknown; predicted to be due to loss of function

Table 7. Pathogenic Variants Referenced in This *GeneReview* by Gene

Gene	Reference Sequences	DNA Nucleotide Change	Predicted Protein Change	Comment [Reference]
HPSE2	NM_021828.4 NP_068600.4	c.1465_1466delAA	p.Asn489ProfsTer126	Common variant in persons of Irish ancestry [Daly et al 2010, Pang et al 2010]
		c.1516C>T	p.Arg506Ter	Founder variant in Colombian population [Pang et al 2010]

Variants listed in the table have been provided by the authors. *GeneReviews* staff have not independently verified the classification of variants.

GeneReviews follows the standard naming conventions of the Human Genome Variation Society (varnomen.hgvs.org). See [Quick Reference](#) for an explanation of nomenclature.

Chapter Notes

Author Notes

William G Newman is a clinical geneticist with a research program that includes the identification of the causes of rare inherited disorders. He leads a national UK network on research for lower urinary tract disorders.

Adrian S Woolf is a clinician scientist and has run a kidney and lower urinary tract genetic clinic. His research interest is to find out why some children are born with abnormal urinary tracts.

Glenda M Beaman is a postdoctoral fellow researching the causes of lower urinary tract disorders.

Neil A Roberts is a scientist developing advanced therapies for lower urinary tract disorders including urofacial syndrome.

William G Newman (william.newman@manchester.ac.uk) is actively involved in clinical research regarding individuals with urofacial syndrome. He would be happy to communicate with persons who have any questions regarding diagnosis of urofacial syndrome or other considerations.

William G Newman (william.newman@manchester.ac.uk) is also interested in hearing from clinicians treating families affected by urofacial syndrome in whom no causative variant has been identified through molecular genetic testing of the genes known to be involved in this disorder.

Author History

Glenda M Beaman, PhD (2023-present)

William G Newman, MA, PhD (2013-present)

Neil A Roberts, PhD (2023-present)

Helen M Stuart, MD; University of Manchester (2013-2018)

Adrian S Woolf, MA, MD (2013-present)

Acknowledgments

The authors' work on UFS has been funded by Kidney Research UK (Paed_RP/002/20190925, Paed_RP/005/20190925), Newlife (15-15/03 and 15-16/06), National Institute for Health Research (NIHR203308), the Medical Research Council (MR/L002744/1, MR/T016809/1, MR/Y008340/1) and the Wellcome Trust. We have been supported by ERIC, a UK charity dedicated to improving children's bowel and

bladder health. We dedicate this review to our colleague Dr Edward McKenzie, who first cloned *HPSE2* and worked with us to understand the importance of this protein to health.

Revision History

- 28 September 2023 (sw) Comprehensive update posted live
- 7 June 2018 (bp) Comprehensive update posted live
- 22 August 2013 (me) Review posted live
- 17 May 2013 (wgn) Original submission

References

Literature Cited

- Akl KF, Al Momany HM. Urofacial syndrome. *Saudi J Kidney Dis Transpl.* 2012;23:346-8. PubMed PMID: 22382233.
- Al Badr W, Al Bader S, Otto E, Hildebrandt F, Ackley T, Peng W, Xu J, Li J, Owens KM, Bloom D, Innis JW. Exome capture and massively parallel sequencing identifies a novel *HPSE2* mutation in a Saudi Arabian child with Ochoa (urofacial) syndrome. *J Pediatr Urol.* 2011;7:569-73. PubMed PMID: 21450525.
- Aydogdu O, Burgu B, Demirel F, Soygur T, Ozcakar ZB, Yalcinkaya F, Tekgul S. Ochoa syndrome: a spectrum of urofacial syndrome. *Eur J Pediatr.* 2010;169:431-5. PubMed PMID: 19669792.
- Bacchetta J, Cochat P. Severe voiding dysfunction: ask the child to smile. *Kidney Int.* 2010;78:225-6. PubMed PMID: 20588289.
- Barbon C, Grünherz L, Schweizer R, Lindenblatt N, Giovanoli P. Botulinum toxin to improve facial expression in a patient with urofacial (Ochoa) syndrome. *Am J Med Genet A.* 2023;191:559-63. PubMed PMID: 36321812.
- Beaman GM, Lopes FM, Hofmann A, Roesch W, Promm M, Bijlsma EK, Patel C, Akinci A, Burgu B, Knijnenburg J, Ho G, Aufschlaeger C, Dathe S, Voelckel MA, Cohen M, Yue WW, Stuart HM, Mckenzie EA, Elvin M, Roberts NA, Woolf AS, Newman WG. Expanding the *HPSE2* genotypic spectrum in urofacial syndrome, a disease featuring a peripheral neuropathy of the urinary bladder. *Front Genet.* 2022;13:896125. PubMed PMID: 35812751.
- Cui H, Shao C, Liu Q, Yu W, Fang J, Yu W, Ali A, Ding K. Heparanase enhances nerve-growth-factor-induced PC12 cell neuritogenesis via the p38 MAPK pathway. *Biochem J.* 2011;440:273-82. PubMed PMID: 21831044.
- Daly SB, Urquhart JE, Hilton E, McKenzie EA, Kammerer RA, Lewis M, Kerr B, Stuart H, Donnai D, Long DA, Burgu B, Aydogdu O, Derbent M, Garcia-Minaur S, Reardon W, Gener B, Shalev S, Smith R, Woolf AS, Black GC, Newman WG. Mutations in *HPSE2* cause urofacial syndrome. *Am J Hum Genet.* 2010;86:963-9. PubMed PMID: 20560210.
- Darlow JM, Darlay R, Dobson MG, Stewart A, Charoen P, Southgate J, Baker SC, Xu Y, Hunziker M, Lambert HJ, Green AJ, Santibanez-Koref M, Sayer JA, Goodship THJ, Puri P, Woolf AS, Kenda RB, Barton DE, Cordell HJ. Genome-wide linkage and association study implicates the 10q26 region as a major genetic contributor to primary nonsyndromic vesicoureteric reflux. *Sci Rep.* 2017;7:14595. PubMed PMID: 29097723.
- Derbent M, Melek E, Arman A, Uçkan S, Baskin E. Urofacial (Ochoa) syndrome: can a facial gestalt represent severe voiding dysfunction? *Ren Fail.* 2009;31:589-92. PubMed PMID: 19839856.
- Feldman AS, Bauer SB. Diagnosis and management of dysfunctional voiding. *Curr Opin Pediatr.* 2006;18:139-47. PubMed PMID: 16601493.

- Fux L, Ilan N, Sanderson RD, Vlodaysky I. Heparanase: busy at the cell surface. *Trends Biochem Sci*. 2009;34:511-9. PubMed PMID: 19733083.
- Ganesan I, Thomas T. More than meets the smile: facial muscle expression in children with Ochoa syndrome. *Med J Malaysia*. 2011;66:507-9. PubMed PMID: 22390114.
- Garcia-Minaur S, Oliver F, Yanez JM, Soriano JR, Quinn F, Reardon W. Three new European cases of urofacial (Ochoa) syndrome. *Clin Dysmorphol*. 2001;10:165-70. PubMed PMID: 11446407.
- Gauthier J, Ouled Amar Bencheikh B, Hamdan FF, Harrison SM, Baker LA, Couture F, Thiffault I, Ouazzani R, Samuels ME, Mitchell GA, Rouleau GA, Michaud JL, Soucy JF. A homozygous loss-of-function variant in MYH11 in a case with megacystis-microcolon-intestinal hypoperistalsis syndrome. *Eur J Hum Genet*. 2015;23:1266-8. PubMed PMID: 25407000.
- Grenier C, Lopes FM, Cueto-González AM, Rovira-Moreno E, Gander R, Jarvis BW, McCloskey KD, Gurney AM, Beaman GM, Newman WG, Woolf AS, Roberts NA. Neurogenic defects occur in LRIG2-associated urinary bladder disease. *Kidney Int Rep*. 2023;8:1417-29. PubMed PMID: 37441484.
- Guo D, Holmlund C, Henriksson R, Hedman H. The LRIG gene family has three vertebrate paralogs widely expressed in human and mouse tissues and a homolog in Ascidiacea. *Genomics*. 2004;84:157-65. PubMed PMID: 15203213.
- Harkness JR, Beaman GM, Teik KW, Sidhu S, Sayer JA, Cordell HJ, Thomas HB, Wood K, Stuart HM, Woolf AS, Newman WG. Early B-cell factor 3-related genetic disease can mimic urofacial syndrome. *Kidney Int Rep*. 2020;5:1823-7. PubMed PMID: 33102976.
- Hedman H, Henriksson R. LRIG inhibitors of growth factor signalling - double-edged swords in human cancer? *Eur J Cancer*. 2007;43:676-82. PubMed PMID: 17239582.
- Homma S, Shimada T, Hikake T, Yaginuma H. Expression pattern of LRR and Ig domain-containing protein (LRIG protein) in the early mouse embryo. *Gene Expr Patterns*. 2009;9:1-26. PubMed PMID: 18848646.
- Huang SJ, Amendola LM, Sternen DL. Variation among DNA banking consent forms: points for clinicians to bank on. *J Community Genet*. 2022;13:389-97. PubMed PMID: 35834113.
- Jónsson H, Sulem P, Kehr B, Kristmundsdóttir S, Zink F, Hjartarson E, Hardarson MT, Hjorleifsson KE, Eggertsson HP, Gudjonsson SA, Ward LD, Arnadóttir GA, Helgason EA, Helgason H, Gylfason A, Jonasdóttir A, Jonasdóttir A, Rafnar T, Frigge M, Stacey SN, Th Magnusson O, Thorsteinsdóttir U, Masson G, Kong A, Halldorsson BV, Helgason A, Gudbjartsson DF, Stefansson K. Parental influence on human germline de novo mutations in 1,548 trios from Iceland. *Nature*. 2017;549:519-22. PubMed PMID: 28959963.
- Levy-Adam F, Feld S, Cohen-Kaplan V, Shteingauz A, Gross M, Arvatz G, Naroditsky I, Ilan N, Doweck I, Vlodaysky I. Heparanase 2 interacts with heparan sulfate with high affinity and inhibits heparanase activity. *J Biol Chem*. 2010;285:28010-9. PubMed PMID: 20576607.
- Mahmood S, Beetz C, Tahir MM, Imran M, Mumtaz R, Bassmann I, Jahic A, Malik M, Nürnberg G, Hassan SA, Rana S, Nürnberg P, Hübner CA. First HPSE2 missense mutation in urofacial syndrome. *Clin Genet*. 2012;81:88-92. PubMed PMID: 21332471.
- McKenzie E, Tyson K, Stamps A, Smith P, Turner P, Barry R, Hircock M, Patel S, Barry E, Stubberfield C, Terrett J, Page M. Cloning and expression profiling of Hpa2, a novel mammalian heparanase family member. *Biochem Biophys Res Commun*. 2000;276:1170-7. PubMed PMID: 11027606.
- Mermerkaya M, Süer E, Öztürk E, Gülpınar Ö, Gökçe Mİ, Yağcındağ FN, Soygür T, Burgu B. Nocturnal lagophthalmos in children with urofacial syndrome (Ochoa): a novel sign. *Eur J Pediatr*. 2014;173:661-5. PubMed PMID: 24248520.
- Milewicz DM, Østergaard JR, Ala-Kokko LM, Khan N, Grange DK, Mendoza-Londono R, Bradley TJ, Olney AH, Adès L, Maher JF, Guo D, Buja LM, Kim D, Hyland JC, Regalado ES. De novo ACTA2 mutation causes a

- novel syndrome of multisystemic smooth muscle dysfunction. *Am J Med Genet A*. 2010;152A:2437-43. PubMed PMID: 20734336.
- Nicanor FA, Cook A, Pippi-Salle JL. Early diagnosis of the urofacial syndrome is essential to prevent irreversible renal failure. *Int Braz J Urol*. 2005;31:477-81. PubMed PMID: 16255797.
- Ochoa B. Can a congenital dysfunctional bladder be diagnosed from a smile? The Ochoa syndrome updated. *Pediatr Nephrol*. 2004;19:6-12. PubMed PMID: 14648341.
- Ochoa B. The urofacial (Ochoa) syndrome revisited. *J Urol*. 1992;148:580-3. PubMed PMID: 1640526.
- Ochoa B, Gorlin RJ. Urofacial (Ochoa) syndrome. *Am J Med Genet*. 1987;27:661-7. PubMed PMID: 3631137.
- Osorio S, Rivillas ND, Martinez JA. Urofacial (Ochoa) syndrome: a literature review. *J Pediatr Urol*. 2021;17:246-54. PubMed PMID: 33558177.
- Pang J, Zhang S, Yang P, Hawkins-Lee B, Zhong J, Zhang Y, Ochoa B, Agundez JA, Voelckel MA, Fisher RB, Gu W, Xiong WC, Mei L, She JX, Wang CY. Loss-of-function mutations in HPSE2 cause the autosomal recessive urofacial syndrome. *Am J Hum Genet*. 2010;86:957-62. PubMed PMID: 20560209.
- Richards S, Aziz N, Bale S, Bick D, Das S, Gastier-Foster J, Grody WW, Hegde M, Lyon E, Spector E, Voelkerding K, Rehm HL, et al. Standards and guidelines for the interpretation of sequence variants: a joint consensus recommendation of the American College of Medical Genetics and Genomics and the Association for Molecular Pathology. *Genet Med*. 2015;17:405-24. PubMed PMID: 25741868.
- Richer J, Milewicz DM, Gow R, de Nanassy J, Maharajh G, Miller E, Oppenheimer L, Weiler G, O'Connor M. R179H mutation in ACTA2 expanding the phenotype to include prune-belly sequence and skin manifestations. *Am J Med Genet A*. 2012;158A:664-8. PubMed PMID: 22302747.
- Roberts NA, Hilton EN, Lopes FM, Singh S, Randles MJ, Gardiner NJ, Chopra K, Coletta R, Bajwa Z, Hall RJ, Yue WW, Schaefer F, Weber S, Henriksson R, Stuart HM, Hedman H, Newman WG, Woolf AS. Lrig2 and Hpse2, mutated in urofacial syndrome, pattern nerves in the urinary bladder. *Kidney Int*. 2019;95:1138-52. PubMed PMID: 30885509.
- Roberts NA, Woolf AS, Stuart HM, Thuret R, McKenzie EA, Newman WG, Hilton EN. Heparanase 2, mutated in urofacial syndrome, mediates peripheral neural development in *Xenopus*. *Hum Mol Genet*. 2014;23:4302-14. PubMed PMID: 24691552.
- Skálová S, Rejtar I, Novák I, Jüttnerová V. The urofacial (Ochoa) syndrome--first case in the central European population. *Prague Med Rep*. 2006;107:125-9.
- Stenson PD, Mort M, Ball EV, Chapman M, Evans K, Azevedo L, Hayden M, Heywood S, Millar DS, Phillips AD, Cooper DN. The Human Gene Mutation Database (HGMD®): optimizing its use in a clinical diagnostic or research setting. *Hum Genet*. 2020;139:1197-207. PubMed PMID: 32596782.
- Stuart HM, Roberts NA, Burgu B, Daly SB, Urquhart JE, Bhaskar S, Dickerson JE, Mermerkaya M, Silay MS, Lewis MA, Olondriz MB, Gener B, Beetz C, Varga RE, Gülpınar O, Süer E, Soygür T, Özçakar ZB, Yalçinkaya F, Kavaz A, Bulum B, Gücük A, Yue WW, Erdogan F, Berry A, Hanley NA, McKenzie EA, Hilton EN, Woolf AS, Newman WG. LRIG2 mutations cause urofacial syndrome. *Am J Hum Genet*. 2013;92:259-64. PubMed PMID: 23313374.
- Stuart HM, Roberts NA, Hilton EN, McKenzie EA, Daly SB, Hadfield KD, Rahal JS, Gardiner NJ, Tanley SW, Lewis MA, Sites E, Angle B, Alves C, Lourenço T, Rodrigues M, Calado A, Amado M, Guerreiro N, Serras I, Beetz C, Varga RE, Silay MS, Darlow JM, Dobson MG, Barton DE, Hunziker M, Puri P, Feather SA, Goodship JA, Goodship TH, Lambert HJ, Cordell HJ, Saggari A, Kinali M, Lorenz C, Moeller K, Schaefer F, Bayazit AK, Weber S, Newman WG, Woolf AS, et al. Urinary tract effects of HPSE2 mutations. *J Am Soc Nephrol*. 2015;26:797-804. PubMed PMID: 25145936.
- Sutay NR, Kulkarni R, Arya MK. Ochoa or Urofacial syndrome. *Indian Pediatr*. 2010;47:445-6. PubMed PMID: 20519791.

Woolf AS, Stuart HM, Newman WG. Genetics of human congenital urinary bladder disease. *Pediatr Nephrol.* 2014a;29:353-60. PubMed PMID: 23584850.

Woolf AS, Stuart HM, Roberts NA, McKenzie EA, Hilton EN, Newman WG. Urofacial syndrome: a genetic and congenital disease of aberrant urinary bladder innervation. *Pediatr Nephrol.* 2014b;29:513-8. PubMed PMID: 23832138.

License

GeneReviews® chapters are owned by the University of Washington. Permission is hereby granted to reproduce, distribute, and translate copies of content materials for noncommercial research purposes only, provided that (i) credit for source (<http://www.genereviews.org/>) and copyright (© 1993-2024 University of Washington) are included with each copy; (ii) a link to the original material is provided whenever the material is published elsewhere on the Web; and (iii) reproducers, distributors, and/or translators comply with the [GeneReviews® Copyright Notice and Usage Disclaimer](#). No further modifications are allowed. For clarity, excerpts of GeneReviews chapters for use in lab reports and clinic notes are a permitted use.

For more information, see the [GeneReviews® Copyright Notice and Usage Disclaimer](#).

For questions regarding permissions or whether a specified use is allowed, contact: admasst@uw.edu.