

Dacarbazine

Updated: November 10, 2017.

OVERVIEW

Introduction

Dacarbazine (also known as DTIC) is an intravenously administered alkylating agent used in the therapy of Hodgkin disease and malignant melanoma. Dacarbazine therapy has been associated with serum enzyme elevations during therapy and occasional cases of severe and distinctive acute hepatic failure, probably caused by acute sinusoidal obstruction syndrome.

Background

Dacarbazine (da kar' ba zeen) is a triazene analogue of 5-aminoimidazole-4-carboxamide, a precursor in purine biosynthesis. Its mechanism of action in cancer chemotherapy is unclear. Dacarbazine may act as a purine analogue and antimetabolite. In addition, it is extensively metabolized in the liver and produces intermediates some of which have alkylating activity, causing methylation, modification and cross linking of DNA, thus inhibiting DNA, RNA and protein synthesis. Dacarbazine is popularly known as DTIC and was approved for use in the United States in 1975. Current indications include Hodgkin lymphoma and metastatic malignant melanoma usually in combination with other antineoplastic agents. Dacarbazine is available for injection in vials of 10 mg/mL and the recommended dose varies by indication and body weight (2 to 4.5 mg/kg/day or 150 mg/m²/day). Dacarbazine is given by intravenous infusion typically for five to ten days in cycles of every 3 to 4 weeks. Common side effects are hypotension, alopecia, anoxia, nausea, vomiting, headache, peripheral neuropathy, and flu-like illness. Rare potentially severe adverse events include severe bone marrow suppression, neutropenia, sepsis, embryo-fetal toxicity and de novo carcinogenesis from long term use.

Hepatotoxicity

Mild and transient elevations in serum aminotransferase levels are not uncommon during courses of systemic combination chemotherapy and the role of dacarbazine in these abnormalities is not clear. However, dose modification for serum enzyme elevations is rarely necessary. More importantly, dacarbazine is associated with a severe and distinctive liver injury which typically arises during the second or third cycle of therapy and most likely represents severe acute sinusoidal obstruction syndrome. Patients typically develop the sudden onset of severe abdominal pain, hemodynamic instability and rapidly rising levels of serum aminotransferase levels and prothrombin time, with death within 1 to 10 days (Cases 1 and 2). Liver biopsy and necropsy findings indicate centrilobular necrosis with occlusion of sinusoids and small and large hepatic veins. In some cases, hepatic infarcts are found as well. Eosinophilic infiltrations are common and peripheral eosinophilia may also be present. Unlike with other alkylating agents, sinusoidal obstruction syndrome caused by dacarbazine is associated with the usual chemotherapy doses, not the higher doses used in myeloablation in preparation for

bone marrow transplantation. This syndrome is now rarely reported, probably because of use of dacarbazine in somewhat lower doses.

Likelihood score: B (highly likely cause of clinically apparent liver injury).

Mechanism of Injury

The mechanism of hepatotoxicity from dacarbazine is not known; however, clinical and pathologic features suggest direct injury to sinusoidal endothelial cells causing their death and extrusion into sinusoids with subsequent obstruction. The injury may be immunologically mediated as it usually occurs with the second or third cycle and is accompanied by eosinophilia. In several cases, the initial cycle of dacarbazine was marked by eosinophilia and fever.

Outcome and Management

The severity of sinusoidal obstruction syndrome varies considerably, but most published cases have been severe and rapidly fatal. Anecdotal reports suggest that corticosteroids may be beneficial, but many cases have demonstrated fatal hepatic injury by the time of recognition. Rechallenge should not be done. Defibrotide has been approved for treatment of severe sinusoidal obstruction syndrome with solid organ failure in patients undergoing hematopoietic cell transplantation, but has not been specifically approved for the acute liver failure associated with dacarbazine use.

Drug Class: [Antineoplastic Agents, Alkylating Agents](#)

CASE REPORTS

Case 1. Acute hepatic failure after dacarbazine therapy.

[Modified from: Herishanu Y, Lishner M, Kitay-Cohen Y. The role of glucocorticoids in the treatment of fulminant hepatitis induced by dacarbazine. *Anticancer Drugs* 2002; 13: 177-9. [PubMed Citation](#)]

A 69 year old man with malignant melanoma developed fever, epigastric pain and nausea on day 2 of a second 5 day course of dacarbazine (DTIC: 250 mg/m² daily). On examination, he was febrile (39.5 °C) and hypotensive (blood pressure 74/40 mmHg). His abdomen was distended and he had marked right upper quadrant tenderness. There was no jaundice or rash and no peripheral manifestations of chronic liver disease. The white blood cell count was normal without eosinophilia. Liver tests showed a total bilirubin of 1.1 mg/dL, ALT 7040 U/L, AST 6080 U/L, LDH 23,635 U/L, alkaline phosphatase 259 U/L and GGT 159 U/L. Serum creatinine was 2.1 mg/dL, and INR was 1.8. Abdominal ultrasound showed a moderate amount of ascitic fluid and two suspected metastases in the liver (~2.4 cm in diameter). On hospital day 3, the patient developed early hepatic encephalopathy and serum ammonia levels were elevated (95 µmol/L). On day 4, mild hypoglycemia occurred and he was treated with fluids, lactulose, neomycin and intravenous hydrocortisone (300 mg/day). On day 5, he was stuporous, but subsequently he began to improve clinically such that he could be discharged by the hospital day 10. Two weeks later he was minimally symptomatic, had no ascites, and serum enzymes had markedly improved.

Key Points

Medication:	Dacarbazine (250 mg/m ² daily in 5 day cycles)
Pattern:	Sinusoidal obstruction syndrome (hepatocellular)
Severity:	4+ (acute liver failure with spontaneous survival)
Latency:	2 days after starting a second 5 day cycle

Table continued from previous page.

Recovery:	10 days
Other medications:	Interferon- α and previous therapy with chlorambucil and prednisone

Comment

Most cases of acute hepatic necrosis due to dacarbazine are rapidly fatal. Typically, the injury arises abruptly during the second course of therapy with sudden onset of fever and abdominal pain followed by cardiovascular collapse and marked rises in serum aminotransferase levels and LDH. Coagulopathy is usually present early, while bilirubin elevations occur later and with progressive hepatic failure (ascites, hepatic encephalopathy). Many cases have a history of mild nausea and fever with peripheral eosinophilia during the first course of therapy, a clinical pattern that also occurs with halothane hepatotoxicity. While the cause of the dacarbazine hepatic injury is believed to be acute sinusoidal obstruction syndrome, other features resemble acute ischemic necrosis due to shock or hepatic infarction. The presence of eosinophilia suggests hypersensitivity which is also supported by the occurrence during reexposure and the history of fever with the initial cycle of treatment. Regardless, the syndrome is severe and corticosteroid therapy is not unreasonable if started early. Furthermore, patients who develop fever and eosinophilia during dacarbazine therapy should not receive a second course.

Case 2. Acute veno-occlusive disease and liver failure due to dacarbazine.

[Modified from: Ceci G, Bella M, Melissari M, Gabrielli M, Bocchi P, Cocconi G. Fatal hepatic toxicity of DTIC: Is It Really a Rare Event? *Cancer* 1985; 61: 1988-91. [PubMed Citation](#)]

A 52 year old man with metastatic malignant melanoma developed fever during day 2 of a second cycle of dacarbazine followed on day 4 by acute abdominal pain and shock. He had tolerated the first cycle of dacarbazine with only mild nausea and vomiting and a few days of fever of 38-39 °C immediately after the 5 day course. At the time of restarting dacarbazine, he was without symptoms and the tumor had decreased in size. On presentation with hepatic injury, he was hypotensive and had tender hepatomegaly. Laboratory tests showed total bilirubin of 2.8 mg/dL, ALT 2050 U/L, AST 2990 U/L, LDH 3270 U/L, alkaline phosphatase 153 U/L, and INR 1.64. Ultrasound of the abdomen showed an enlarged liver and ascites. Acute cholecystitis was suspected and a laparotomy was performed. The gallbladder showed signs of chronic inflammation but no perforation. The liver was enlarged and dark. A liver biopsy showed diffuse centrilobular hepatic necrosis and hemorrhage. After surgery, he developed multiorgan failure and progressive hepatic decompensation, dying on hospital day 8. At autopsy, the liver was enlarged and histology showed centrilobular necrosis and hemorrhage with occlusion of small and medium sized hepatic veins.

Key Points

Medication:	Dacarbazine (250 mg/m ² for 5 days every 3 weeks)
Pattern:	Hepatocellular (R=35)
Severity:	5+ (fatal)
Latency:	2 days (fever)
Recovery:	None
Other medications:	Metoclopramide for nausea

Comment

The acute hepatic injury attributed to dacarbazine has a very typical clinical presentation and course, with evidence of acute hepatic necrosis as shown by a marked early rise in ALT and LDH with coagulopathy that

reverses rapidly if not fatal. The fever and nausea associated with the first course of dacarbazine is typical of subsequent acute liver injury. While the pathology demonstrates sinusoidal obstruction syndrome, there also appears to be an element of acute ischemic necrosis. The rapid appearance on reexposure and the frequent occurrence of fever and eosinophilia suggests a hypersensitivity reaction.

PRODUCT INFORMATION

REPRESENTATIVE TRADE NAMES

Dacarbazine – Generic, DTIC,[®] DTIC-Dome[®]

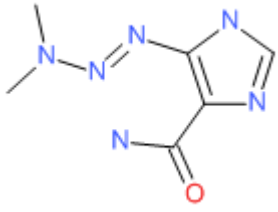
DRUG CLASS

Antineoplastic Agents, Alkylating Agents

COMPLETE LABELING

Product labeling at DailyMed, National Library of Medicine, NIH

CHEMICAL FORMULA AND STRUCTURE

DRUG	CAS REGISTRY NUMBER	MOLECULAR FORMULA	STRUCTURE
Dacarbazine	4342-03-4	C ₆ H ₁₀ N ₆ O	

ANNOTATED BIBLIOGRAPHY

References updated: 10 November 2017

Zimmerman HJ. Oncotherapeutic and immunosuppressive agents. In, Zimmerman HJ. Hepatotoxicity: the adverse effects of drugs and other chemicals on the liver. 2nd ed. Philadelphia: Lippincott, 1999, pp. 673-708.

(Expert review of hepatotoxicity of cancer chemotherapeutic agents published in 1999 mentions that dacarbazine has been linked to fatal cases of veno-occlusive disease).

DeLeve LD. Cancer chemotherapy. In, Kaplowitz N, DeLeve LD, eds. Drug-induced liver disease. 3rd ed. Amsterdam: Elsevier, 2013, pp. 549-68.

(Review of hepatotoxicity of cancer chemotherapeutic agents; mentions that dacarbazine has been implicated in at least 15 cases of sinusoidal obstruction syndrome often associated with eosinophilia).

Chabner BA, Bertino J, Clearly J, Ortiz T, Lane A, Supko JG, Ryan DP. Cytotoxic agents. Chemotherapy of neoplastic diseases. In, Brunton LL, Chabner BA, Knollman BC, eds. Goodman & Gilman's the pharmacological basis of therapeutics. 12th ed. New York: McGraw-Hill, 2011, pp. 1315-404.

(Textbook of pharmacology and therapeutics).

- Frosch PJ, Czarnetzki BM, Macher E, Grundmann E, Gottschalk I. Hepatic failure in a patient treated with dacarbazine (DTIC) for malignant melanoma. *J Cancer Res Clin Oncol* 1979; 95: 281-6. PubMed PMID: 528568.
- (55 year old woman with melanoma developed cardiovascular collapse on the third day of second cycle of dacarbazine, with subsequent multiorgan failure and death; autopsy showing ischemic necrosis but evidence of veno-occlusive disease as well).*
- Houghton AN, Shafi N, Rickles FR. Acute hepatic vein thrombosis occurring during therapy for Hodgkin's disease: a case report. *Cancer* 1979; 44: 2324-9. PubMed PMID: 509400.
- (50 year old man with Hodgkin disease developed abdominal pain and fever, followed by cardiovascular collapse on the fifth day of the second course of adriamycin, vinblastine and dacarbazine with bilirubin 1.4 mg/dL, AST 5200 U/L, Alk P 88 U/L, progressing to multiorgan failure and death in 2 days; autopsy showed Budd Chiari syndrome with hepatic vein thrombosis).*
- Asbury RF, Rosenthal SN, Descalzi ME, Ratcliffe RL, Arseneau JC. Hepatic veno-occlusive disease due to DTIC. *Cancer* 1980; 45: 2670-4. PubMed PMID: 7379000.
- (59 year old man with melanoma developed fever and nausea 5 days after a 5 day course of dacarbazine which resolved, but then had severe abdominal pain on day 3 of a second cycle [bilirubin 1.6 mg/dL, AST 162 rising to 13,860 U/L, protime 17.3 rising to 30.7 seconds], with death in 2 days; autopsy showing massive centrilobular necrosis).*
- Balda BR, Bassermann R. DTIC therapie und Budd-Chiari-Syndrom. *Munch Med Wschr* 1980; 122: 792-4. PubMed PMID: 6771598.
- (58 year old woman with malignant melanoma developed severe abdominal pain during second cycle of dacarbazine; autopsy showing thrombosis of medium and large hepatic veins with eosinophilic infiltration).*
- Runne U, Doepfmer K, Antz H, Groth W, Feaux de Lacrois W. Budd-Chiari-Syndrom unter Dacarbazin. *Dtsch Med Wochenschr* 1980; 105: 230-3. PubMed PMID: 6986251.
- (50 year old man with malignant melanoma developed shock during second cycle of dacarbazine, with autopsy showing thrombosis of medium and larger veins and eosinophilic infiltration).*
- Voigt H, Caselitz J, Jänner M. [Veno-occlusive syndrome with acute liver dystrophy following dacarbazine therapy of malignant melanoma]. *Klin Wochenschr* 1981; 59: 229-36. German. PubMed PMID: 7218735.
- (68 year old man with malignant melanoma developed cardiovascular collapse during a second course of dacarbazine therapy, with death within 5 days [peak ALT 4950 U/L, LDH 11,059 U/L, GGT 46 U/L]).*
- Czarnetzki BM, Macher E. DTIC(dacarbazine)-induced hepatic damage. Possible pathogenesis and prevention. *Arch Dermatol Res* 1981; 270: 375-6. PubMed PMID: 6115618.
- (71 year old woman with malignant melanoma developed ALT elevations [peak values 96 and 37 U/L] and eosinophilia after first two cycles of dacarbazine, which did not occur with subsequent courses with concurrent prednisone therapy).*
- Greenstone MA, Dowd PM, Mikhailidis DP, Scheuer PJ. Hepatic vascular lesions associated with dacarbazine treatment. *Br Med J (Clin Res Ed)* 1981; 282: 1744-5. PubMed PMID: 6786601.
- (Two cases, 53 and 46 year old men with malignant melanoma, developed liver injury on the third to fourth day of a second course of dacarbazine therapy, dying within 72 hours [patient 1: bilirubin 4.5 mg/dL, ALT 1780 U/L, Alk P 148 U/L], autopsy showing hepatic infarcts).*
- Doering CH, Pickartz H, Orfanos CE, Altenahr E. [Dacarbazine in malignant melanoma. Rare, severe side-effect: Budd-Chiari-syndrom]. *Z Hautkr* 1982; 57: 971-80. German. PubMed PMID: 7113323.

(54 year old man with melanoma developed fever and eosinophilia during first course and fever and shock during second course of dacarbazine [bilirubin 2.1 mg/dL, ALT 1574 U/L, prothrombin index 23%], dying 11 days later, autopsy showing fresh thromboses in small and medium hepatic veins).

Swenson-Beck H, Trettel WH. Budd-Chiari-Syndrom bei DTIC-therapie. Hautarzt 1982; 33: 30-1. PubMed PMID: 7085277.

(41 year old woman with melanoma developed abdominal pain and shock on second day of second course of dacarbazine [ALT >900 U/L, 28% eosinophils], dying within 24 hours, biopsy showed changes suggestive of hepatic vein thrombosis).

Feaux de Lacroix W, Runne U, Hauk H, Doepfmer K, Groth W, Wacker D. Acute liver dystrophy with thrombosis of hepatic veins: a fatal complication of dacarbazine treatment. Cancer Treat Rep 1983; 67: 779-84. PubMed PMID: 6883354.

(4 cases of acute liver failure in 50-59 year old patients with malignant melanoma, with shock-like symptoms arising during the second cycle of dacarbazine with rapid progression to death; autopsies showed hemorrhagic necrosis and thrombosis of small hepatic veins, often with eosinophilic infiltrates, some patients having peripheral eosinophilia).

Dancygier H, Runne U, Leuschner U, Milbradt R, Classen M. Dacarbazine (DTIC)-induced human liver damage: light and electron-microscopic findings. Hepatogastroenterology 1983; 30: 93-5. PubMed PMID: 6884975.

(61 year old man with malignant melanoma developed severe liver injury during second cycle of dacarbazine, liver biopsy showing centrolobular necrosis and electron microscopy showing intracytoplasmic vacuoles in hepatocyte with membranous blebs; patient recovered on methylprednisolone therapy).

Sotaniemi EA, Sutinen S, Arranto AJ, Sutinen S, Sotaniemi KA, Lehtola J, Pelkonen RO. Liver damage in nurses handling cytostatic agents. Acta Med Scand 1983; 214: 181-9. PubMed PMID: 6660024.

(Three nurses developed liver injury after years of handling cytostatic drugs including dacarbazine; they had neurological symptoms associated with elevated ALT and alkaline phosphatase levels; liver histology showed portal hepatitis with piecemeal necrosis in one of them, the others had hepatic fibrosis and fat accumulation).

Erichsen C, Jönsson PE. Venous-occlusive liver disease after dacarbazine therapy (DTIC) for melanoma. J Surg Oncol 1984; 27: 268-70. PubMed PMID: 6503301.

(46 year old man with malignant melanoma developed abdominal pain and ascites after a third cycle of dacarbazine [bilirubin 3.1 mg/dL ALT 5282 U/L, Alk P 534 U/L, prothrombin index 12%] and died within days; autopsy showed veno-occlusive disease with eosinophilic infiltrates).

Leyh F, Winzer M, Weber M, Hypa F. Budd-Chiari syndrome following dacarbazine therapy of malignant melanoma--an avoidable complication? Z Hautkr 1985; 60: 961-72. PubMed PMID: 4024678.

(51 year old woman with malignant melanoma died of Budd-Chiari syndrome during treatment with dacarbazine).

Paschke R, Heine M. Pathophysiological aspects of dacarbazine-induced human liver damage. Hepatogastroenterology 1985; 32: 273-5. PubMed PMID: 4093126.

(39 year old with Hodgkin disease developed hypotension after 4 days of dacarbazine therapy, with rise in ALT to 561 U/L and 21% eosinophilia with ascites and progressive hepatic failure; autopsy showed venoocclusive disease).

Rollins BJ. Hepatic veno-occlusive disease. Am J Med 1986; 8: 297-306. PubMed PMID: 3526887.

(Review of the diagnosis, clinical course, histology and pathogenesis of veno-occlusive disease, now known as sinusoidal obstruction syndrome).

Joensuu H, Soderstrom KO, Nikkanen V. Fatal necrosis of the liver during ABVD chemotherapy for Hodgkin's disease. A case report. *Cancer* 1986; 58: 1437-40. PubMed PMID: 2427187.

(50 year old man with Hodgkin lymphoma treated with ABVD [doxorubicin, bleomycin, vinblastine and dacarbazine] at 4 week intervals developed acute liver failure during fourth cycle and autopsy showed centrilobular necrosis).

Jones RJ, Lee KS, Beschorner WE, Vogel VG, Grochow LB, Braine HG, Vogelsang GB, et al. Venous-occlusive disease of the liver following bone marrow transplantation. *Transplantation* 1987; 4: 778-83. PubMed PMID: 3321587.

(Among 235 patients undergoing bone marrow transplantation between 1982 and 1985, sinusoidal obstruction syndrome [SOS] developed in 52 [22%] of whom half died, making SOS the third most common cause of death in this population).

Ceci G, Bella M, Melissari M, Gabrielli M, Bocchi P, Cocconi G. Fatal hepatic vascular toxicity of DTIC. Is it really a rare event? *Cancer* 1988; 61: 1988-91. PubMed PMID: 3359400.

(Among 68 patients with malignant melanoma, 2 developed hepatic failure on dacarbazine therapy; 52 and 70 year old men developed fever and shock during a second cycle of dacarbazine [patient 1: bilirubin 2.8 mg/dL, ALT 2050 U/L, Alk P 153 U/L, INR 1.6], with multiorgan failure and death 1 and 8 days later; autopsies showed massive centrilobular necrosis and occlusion of small hepatic veins and infiltrates of eosinophils: Case 2).

Marsh JC. Hepatic vascular toxicity of dacarbazine (DTIC): not a rare complication. *Hepatology* 1989; 9: 790-2. PubMed PMID: 2707742.

(Summary and comment on article by Ceci [1988]).

Paschke R, Heine M, Braun S, Usadel KH. Mechanisms of hepatotoxicity caused by dacarbazine in rats. *J Cancer Res Clin Oncol* 1993; 119: 475-81. PubMed PMID: 8509437.

(In rats, high doses of dacarbazine cause acute hepatocellular necrosis; no hepatic venous changes or eosinophilia).

Bearman SI. The syndrome of hepatic veno-occlusive disease after marrow transplantation. *Blood* 1995; 85: 3005-20. PubMed PMID: 7756636.

(Review of hepatic veno-occlusive disease after bone marrow transplantation; usually presents with painful hepatomegaly, weight gain [fluid and ascites] and jaundice within 3 weeks of myeloablation, with occlusion of central veins and sinusoids and extensive zone 3 [centrilobular] injury).

Quinio P, Bouche O, Lambolais C, Savry C, Cartier H, Egretieu JP. Fatal hepatic toxicity of DTIC: a new case. *Intens Care Med* 1997; 23: 1099-1102. PubMed PMID: 9407248.

(50 year old woman with malignant melanoma developed abdominal pain and fever on day 2 of the second cycle of dacarbazine [ALT 2348 U/L, LDH 20,430 U/L, INR 3.9], with ascites, multiorgan failure and death 5 days later).

Herishanu Y, Lishner M, Kitay-Cohen Y. The role of glucocorticoids in the treatment of fulminant hepatitis induced by dacarbazine. *Anticancer Drugs* 2002; 13: 177-9. PubMed PMID: 11901312.

(61 year old man with malignant melanoma developed fever and abdominal pain on second day of second cycle of dacarbazine [bilirubin 1.1 mg/dL, ALT 7040 U/L, LDH 23,635 U/L, Alk P 249 U/L, INR 1.8], with ascites, hypotension, and encephalopathy, with improvement after corticosteroid therapy and rapid recovery: Case 1).

McDonald GB. Hepatobiliary complications of hematopoietic cell transplantation, 40 years on. *Hepatology* 2010; 51: 1450-60. PubMed PMID: 20373370.

(Review of liver complications of bone marrow [hematopoietic cell] transplantation, which have become less frequent with better understanding of their causes and means of prevention; the rate of sinusoidal obstruction syndrome has decreased because of avoidance of more aggressive ablative therapies [total body irradiation and high doses of cyclophosphamide] and better understanding of pharmacokinetics of the alkylating agents).

Reuben A, Koch DG, Lee WM; Acute Liver Failure Study Group. Drug-induced acute liver failure: results of a U.S. multicenter, prospective study. *Hepatology* 2010; 52: 2065-76. PubMed PMID: 20949552.

(Among 1198 patients with acute liver failure enrolled in a US prospective study between 1998 and 2007, 133 were attributed to drug induced liver injury, none of which were attributed to dacarbazine).

García-Del-Muro X, López-Pousa A, Maurel J, Martín J, Martínez-Trufero J, Casado A, Gómez-España A, et al; Spanish Group for Research on Sarcomas. Randomized phase II study comparing gemcitabine plus dacarbazine versus dacarbazine alone in patients with previously treated soft tissue sarcoma: a Spanish Group for Research on Sarcomas study. *J Clin Oncol* 2011; 29: 2528-33. PubMed PMID: 21606430.

(Controlled trial of dacarbazine with or without gemcitabine in 113 patients with soft tissue sarcomas; side effects were frequent, but no mention of ALT elevations or clinically apparent liver injury).

Robert C, Thomas L, Bondarenko I, O'Day S, Weber J, Garbe C, Lebbe C, et al. Ipilimumab plus dacarbazine for previously untreated metastatic melanoma. *N Engl J Med* 2011; 364: 2517-26. PubMed PMID: 21639810.

(Controlled trial of dacarbazine with or without ipilimumab [monoclonal anti-CTLA-4] in 502 patients with metastatic melanoma; ALT elevations occurred in 33% of combination versus 6% of dacarbazine alone treated patients and "immune related hepatitis" in 38% on ipilimumab, with no mortality, but delay in resolution averaging 10 weeks).

Hernández N, Bessone F, Sánchez A, di Pace M, Brahm J, Zapata R, A Chirino R, et al. Profile of idiosyncratic drug induced liver injury in Latin America. An analysis of published reports. *Ann Hepatol* 2014; 13: 231-9. PubMed PMID: 24552865.

(Systematic review of literature of drug induced liver injury in Latin American countries published from 1996 to 2012 identified 176 cases, 40 of which were attributed to antineoplastic agents, but none specifically to dacarbazine).

Douros A, Bronder E, Andersohn F, Klimpel A, Thomae M, Sarganas G, Kreutz R, et al. Drug-induced liver injury: results from the hospital-based Berlin Case-Control Surveillance Study. *Br J Clin Pharmacol* 2015; 79: 988-99. PubMed PMID: 25444550.

(Among 198 patients with hepatitis of unknown cause enrolled in a prospective database from 51 Berlin hospitals between 2002 and 2011, none were attributed to dacarbazine).

Chalasani N, Bonkovsky HL, Fontana R, Lee W, Stolz A, Talwalkar J, Reddy KR, et al.; United States Drug Induced Liver Injury Network. Features and outcomes of 899 patients with drug-induced liver injury: The DILIN Prospective Study. *Gastroenterology* 2015; 148: 1340-52.e7. PubMed PMID: 25754159.

(Among 899 cases of drug induced liver injury enrolled in a US prospective study between 2004 and 2013, 49 cases were attributed to antineoplastic agents, but none to dacarbazine).