



RNU4atac-opathy

Synonym: *RNU4ATAC* Spectrum Disorder

Angela Duker, MS,¹ Danita Velasco, MD,² Nic Robertson, MRCPCH, PhD,³ Andrew Jackson, MRCP, PhD,³ Magee DeFelice, MD,¹ and Michael B Bober, MD, PhD¹

Created: February 16, 2023.

Summary

Clinical characteristics

RNU4atac-opathy encompasses the phenotypic spectrum of biallelic *RNU4ATAC* pathogenic variants, including the three historically designated clinical phenotypes microcephalic osteodysplastic primordial dwarfism type I/III (MOPDI), Roifman syndrome, and Lowry-Wood syndrome, as well as varying combinations of the disease features / system involvement that do not match specific defined phenotypes. Findings present in all affected individuals include growth restriction, microcephaly, skeletal dysplasia, and cognitive impairment. Less common but variable findings include brain anomalies, seizures, strokes, immunodeficiency, and cardiac anomalies, as well as ophthalmologic, skin, renal, gastrointestinal, hearing, and endocrine involvement.

Diagnosis/testing

The diagnosis of RNU4atac-opathy is established in a proband with suggestive findings and biallelic pathogenic (or likely pathogenic) variants in *RNU4ATAC* identified by molecular genetic testing.

Management

Treatment of manifestations: Supportive care to improve quality of life, maximize function, and reduce complications is recommended. This ideally involves multidisciplinary care by specialists in relevant fields, including orthopedists to monitor the associated skeletal dysplasia and immunologists to manage antibiotic treatment of infections and use of immunoglobulin replacement therapy as indicated to avoid life-threatening infections.

Surveillance: To monitor existing manifestations and response to supportive care (such as growth, developmental progress, and educational needs), and to detect new manifestations (particularly brain MRI for detection of stroke in children with MOPDI with neurologic deterioration).

Author Affiliations: 1 Nemours Children's Health, Wilmington, Delaware; Email: aduker@nemours.org; Email: magee.defelice@nemours.org; Email: mbober@nemours.org. 2 University of Nebraska Medical Center, Omaha, Nebraska; Email: dvelasco@unmc.edu. 3 University of Edinburgh, Edinburgh, Scotland, UK; Email: nic.robertson@ed.ac.uk; Email: andrew.jackson@ed.ac.uk.

Agents/circumstances to avoid: Perform immunologic evaluation prior to administration of live vaccines. For those with MOPDI, minimize medically stressful situations as much as possible, including stress during anesthesia, due to energy-related strokes.

Genetic counseling

RNU4atac-opathy is inherited in an autosomal recessive manner. If both parents are known to be heterozygous for an *RNU4ATAC* pathogenic variant, each sib of an affected individual has at conception a 25% chance of being affected, a 50% chance of being an asymptomatic carrier, and a 25% chance of inheriting neither of the familial pathogenic variants. Intrafamilial clinical variability has been reported between sibs who inherit the same biallelic *RNU4ATAC* pathogenic variants. Once the *RNU4ATAC* pathogenic variants have been identified in an affected family member, carrier testing for at-risk relatives and prenatal/preimplantation genetic testing are possible.

GeneReview Scope

With the current widespread use of multigene panels and comprehensive genomic testing, it has become apparent that the phenotypic spectrum of biallelic *RNU4ATAC* pathogenic variants encompasses the three historically designated clinical diagnoses microcephalic osteodysplastic primordial dwarfism type I/III (MOPDI), Roifman syndrome, and Lowry-Wood syndrome, as well as varying combinations of disease features / system involvement that do not match specific defined phenotypes (see Table 1). The term "RNU4atac-opathy" refers to the entire phenotypic spectrum that can be associated with biallelic *RNU4ATAC* pathogenic variants and emphasizes:

- The need to evaluate an individual found to have *RNU4ATAC* pathogenic variants for medically actionable manifestations in the entire phenotypic spectrum (especially immunodeficiency, as early detection and management can be lifesaving) regardless of the clinical findings that prompted molecular genetic testing;
- The importance of counseling families that the finding of biallelic *RNU4ATAC* pathogenic variants is not necessarily equivalent to a diagnosis of one of the historically recognized phenotypes.

Table 1. RNU4atac-opathy: Phenotypic Spectrum Associated with Biallelic *RNU4ATAC* Pathogenic Variants

Severity	Phenotype(s)
Most severe ¹	Microcephalic osteodysplastic primordial dwarfism type I/III (MOPDI) / Taybi-Linder syndrome ²
Variable severity depending on system involvement ¹	Lowry-Wood syndrome ²
	Roifman syndrome ²
	Undefined; variable findings not aligned with historically defined clinical phenotypes

1. See Table 2.

2. Included in the "primordial dwarfism and slender bones" group of the 2019 revision of the "Nosology and Classification of Genetic Skeletal Disorders" [Mortier et al 2019].

Diagnosis

Where no specific reference is cited, data came from the Primordial Dwarfism Registry (NCT04569149). —ED.

No consensus clinical diagnostic criteria for RNU4atac-opathy have been published.

Suggestive Findings

RNU4atac-opathy **should be suspected** in individuals with a combination of the following clinical and radiographic findings and family history.

Clinical findings

- Pre- and postnatal growth restriction
- Microcephaly. In the most severely affected individuals (clinically designated as MOPDI), the skull is microcephalic and dolichocephalic with prominent occiput and sloping forehead. Ridged metopic suture may be present.
- Skeletal dysplasia (see Figure 1). Radiographic evidence of epiphyseal dysplasia as a minimum. As severity increases, the degree of dysplasia broadens to include spinal and metaphyseal changes. Note: While there is no pathognomonic skeletal finding that suggests RNU4atac-opathy, the constellation of skeletal and extraskeletal features should suggest the diagnosis.
- Developmental delay / cognitive impairment (mild, moderate, or profound)
- Facial features (see Figure 2). In the most severely affected individuals, the recognizable facial gestalt includes prominent eyes and nose with full lips and micrognathia. While such findings have not been consistently noted at the milder end of the phenotypic spectrum, a long philtrum and thin upper lip have been variably described.

Variably present but highly suggestive findings

- Brain anomalies
 - Individuals at the most severe end of the spectrum (MOPDI) characteristically have significant brain abnormalities.

Brain imaging findings include lissencephaly, abnormal cortical gyral pattern, hypoplastic frontal lobes, intracranial (interhemispheric) cyst, colpocephaly, cerebellar vermis agenesis/hypoplasia, arachnoid cyst, and complete or partial agenesis of the corpus callosum [Abdel-Salam et al 2013, Putoux et al 2016] (see also Primordial Dwarfism Registry).
 - Individuals who do not have MOPDI can still have one or more of the abovementioned brain anomalies, including partial agenesis of the corpus callosum and bilateral hypoplastic and malrotated hippocampi [Fairchild et al 2011] as well as arachnoid cyst [Farach et al 2018].
 - Individuals with the mildest cognitive impairment do not always demonstrate brain abnormalities on MRI.
- Immunodeficiency. Findings include recurrent sinopulmonary infections, severe bacterial infections, hypogammaglobulinemia, and impaired antibody responses.
- Ophthalmologic findings
 - Findings of retinal dystrophy consistent with cone-rod dystrophy include decreased central visual acuity, constricted visual fields, defective dark adaptation (evident when moving from a well-lit environment to a poorly-lit environment), pale optic discs, narrowing of retinal vasculature, and variable retinal pigmentary changes; presence of nystagmus is variable [Lowry et al 1989, Pierce & Morse 2012, Merico et al 2015] (see also Primordial Dwarfism Registry).
 - Other findings include strabismus [Lowry et al 1989] and congenital or early-onset dense cataracts [Kilic et al 2015, Krøigård et al 2016].

Family history is consistent with autosomal recessive inheritance (e.g., affected sibs and/or parental consanguinity). Absence of a known family history does not preclude the diagnosis.

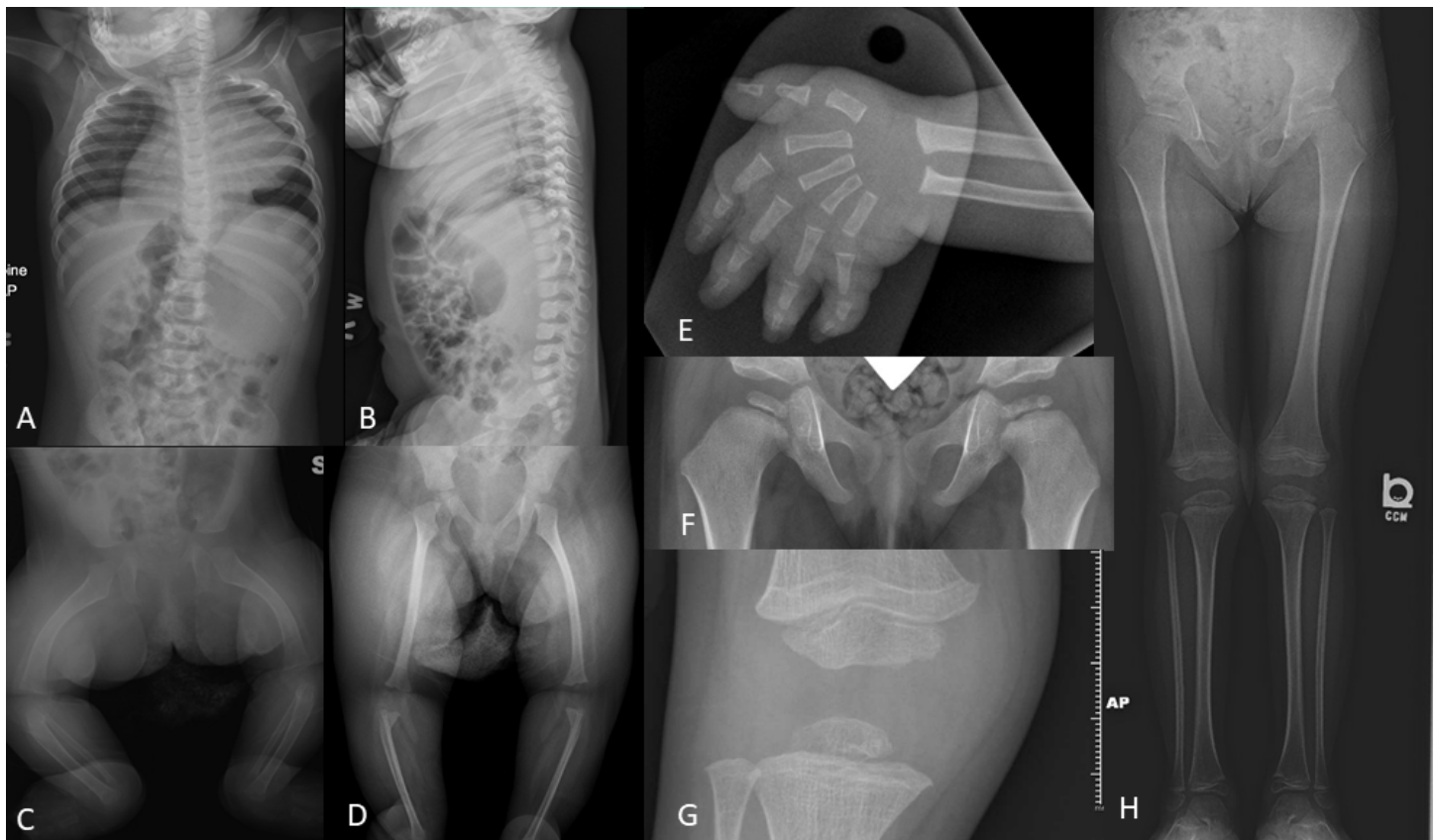


Figure 1. Radiographic features of RNU4atac-opathy

Panels A/B: Anteroposterior (AP) and lateral thoracolumbar spine images of a nine-month-old female with microcephalic osteodysplastic primordial dwarfism type I/III (MOPDI). The chest is broad and scoliosis is present. Note a thoracolumbar kyphosis with end plate irregularities of the vertebral bodies.

Panels C/D: AP images of the lower extremities of a different female with MOPDI at ages ten months and three years, eight months, respectively. Note flattening of the acetabular roofs and femoral bowing in both images. Metaphyseal changes are present. Note that the femoral shafts appear thinner and more gracile over time, and capital femoral epiphyseal ossification is delayed (Panel D).

Panel E: AP radiograph of the hand of a nine-month-old female with MOPDI. Note delayed carpal ossification, tapered phalanges, and dysplastic radial metaphysis.

Panels F/G: AP radiographs of the hips and knees of a female age three years, eight months with a more moderate RNU4atac-opathy phenotype. The capital femoral, distal femoral, and proximal tibial epiphyses are small and dysplastic.

Panel H: Standing AP radiograph of the lower extremities of the female in Panels F/G at age five years, six months. Note mesomelic proportions with genu valgum, significant and predominant epiphyseal dysplasia throughout, as well as minor metaphyseal changes.

Establishing the Diagnosis

The diagnosis of RNU4atac-opathy **is established** in a proband with suggestive findings and biallelic pathogenic (or likely pathogenic) variants in *RNU4ATAC* identified by molecular genetic testing (see Table 2).

Note: (1) Per ACMG/AMP variant interpretation guidelines, the terms "pathogenic variant" and "likely pathogenic variant" are synonymous in a clinical setting, meaning that both are considered diagnostic and can be used for clinical decision making [Richards et al 2015]. Reference to "pathogenic variants" in this *GeneReview* is understood to include likely pathogenic variants. (2) Identification of biallelic *RNU4ATAC* variants of uncertain significance (or of one known *RNU4ATAC* pathogenic variant and one *RNU4ATAC* variant of uncertain significance) does not establish or rule out the diagnosis.

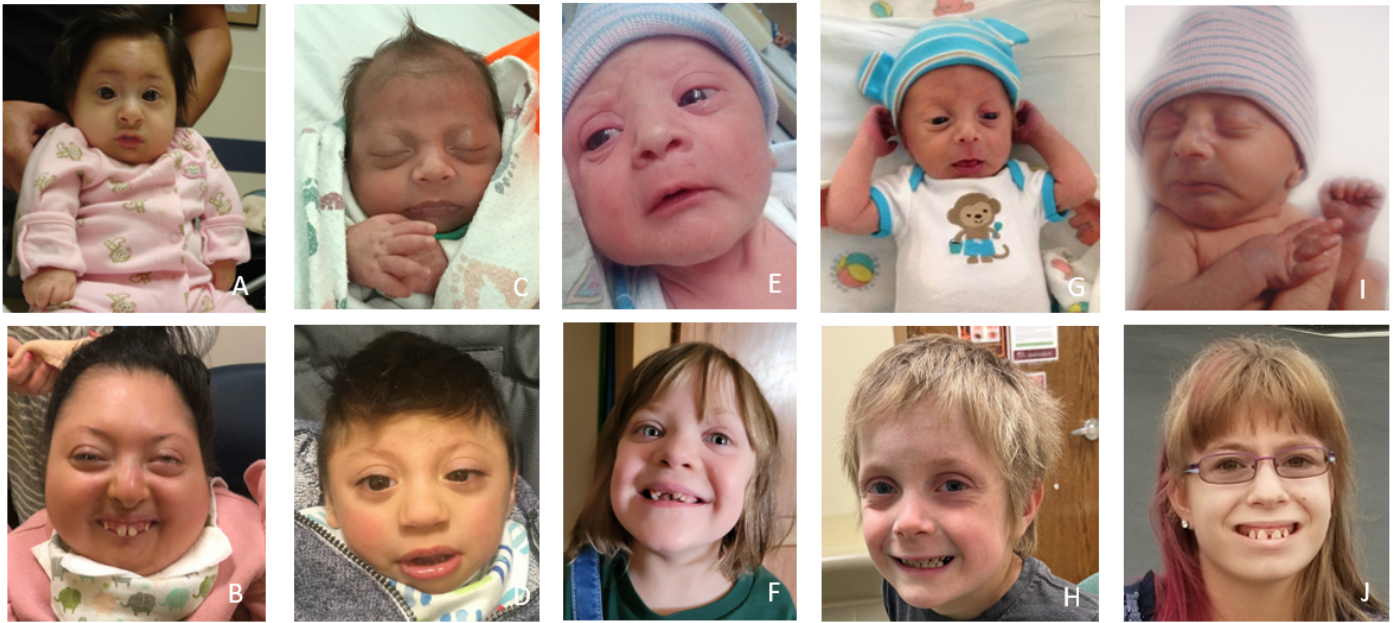

Figure 2. Facial phenotype of RNU4atac-opathy

Craniofacial features vary, with a more consistent and notable gestalt associated with the more severe end of the RNU4atac-opathy spectrum, whereas features seen in the mild/moderate range of the spectrum are more variable. In addition to microcephaly and dolicocephaly, individuals with microcephalic osteodysplastic primordial dwarfism type I/III (MOPDI) have a sloping forehead and ridged metopic suture at birth. The eyes are prominent and appear large; the nasal root is high and the nasal bridge is broad. Lips tend to be full and chin is micrognathic. Ears tend to be small, low set, and posteriorly rotated [Taybi & Linder 1967, Winter et al 1985, Sigaudy et al 1998, Edery et al 2011, Abdel-Salam et al 2012, Kilic et al 2015].

In contrast, the midfacial phenotype in individuals with the historical diagnosis of Roifman syndrome have been variably reported to show thin vermilion of the upper lip, long philtrum, and narrow nasal tip in childhood [Roifman 1999, Robertson et al 2000, de Vries et al 2006, Merico et al 2015, Bogaert et al 2017, Dinur Schejter et al 2017, Hallermayr et al 2018].

Panels A/B: Female at ages 15 months and 11 years, respectively, diagnosed with MOPDI. Note sloping forehead, prominent eyes, and high and broad nasal bridge with bulbous nasal tip (which is more apparent with age), as well as full lips and micrognathia.

Panels C/D: Male in infancy and at age 20 months, respectively, diagnosed with moderate RNU4atac-opathy.

Panels E/F: Female in infancy and at age eight years, respectively, diagnosed with moderate RNU4atac-opathy. In Panels C/D and E/F, note that eyes appear large and prominent, with broad and high nasal bridge and broad nasal tip, with full lips and micrognathia.

Panels G/H: Male in infancy and at age 7.5 years, respectively, diagnosed with Roifman syndrome. Note long philtrum and thin upper lip with narrow nasal tip. Eyes are prominent in infancy.

Panels I/J: Female in infancy and at age 13 years, respectively, diagnosed with Lowry-Wood syndrome. Note broad and high nasal bridge with long philtrum and micrognathia.

Molecular genetic testing approaches can include a combination of **gene-targeted testing** (single-gene testing, multigene panel) and **comprehensive genomic testing** (exome sequencing, genome sequencing).

Gene-targeted testing requires that the clinician determine which gene(s) are likely involved, whereas genomic testing does not. Individuals with the distinctive findings described in Suggestive Findings are likely to be diagnosed using gene-targeted testing (see Option 1), whereas those in whom the diagnosis of RNU4atac-opathy has not been considered are more likely to be diagnosed using genomic testing (see Option 2).

Option 1

When the phenotypic and imaging findings suggest the diagnosis of RNU4atac-opathy, molecular genetic testing approaches can include **single-gene testing** or use of a **multigene panel**.

- **Single-gene testing.** Sequence analysis of *RNU4ATAC* is performed first to detect variants including single-nucleotide substitutions and small deletions or insertions. Note: Depending on the sequencing method used, whole-gene deletions may not be detected. While whole-gene deletions are yet to be reported, if only one variant is detected by the sequencing method used, gene-targeted deletion analysis to detect whole-gene deletions or duplications could be considered.
- **A skeletal dysplasia, primordial dwarfism, or microcephaly multigene panel** that includes *RNU4ATAC* and other genes of interest (see Differential Diagnosis) is most likely to identify the genetic cause of the condition while limiting identification of variants of uncertain significance and pathogenic variants in genes that do not explain the underlying phenotype. Note: (1) The genes included in the panel and the diagnostic sensitivity of the testing used for each gene vary by laboratory and are likely to change over time. (2) Some multigene panels may include genes not associated with the condition discussed in this *GeneReview*. (3) In some laboratories, panel options may include a custom laboratory-designed panel and/or custom phenotype-focused exome analysis that includes genes specified by the clinician. (4) Methods used in a panel may include sequence analysis, deletion/duplication analysis, and/or other non-sequencing-based tests.

For an introduction to multigene panels click [here](#). More detailed information for clinicians ordering genetic tests can be found [here](#).

Option 2

Comprehensive genomic testing does not require the clinician to determine which gene is likely involved. **Exome sequencing** is most commonly used. Note: Exome sequencing may not include analysis of *RNU4ATAC*. **Genome sequencing** is also possible.

For an introduction to comprehensive genomic testing click [here](#). More detailed information for clinicians ordering genomic testing can be found [here](#).

Table 2. Molecular Genetic Testing Used in *RNU4atac*-opathy

Gene ¹	Method	Proportion of Pathogenic Variants ² Identified by Method
<i>RNU4ATAC</i>	Sequence analysis ³	100% ⁴
	Gene-targeted deletion/duplication analysis ⁵	See footnote 6.

1. See Table A. Genes and Databases for chromosome locus and protein.

2. See Molecular Genetics for information on variants detected in this gene.

3. Sequence analysis detects variants that are benign, likely benign, of uncertain significance, likely pathogenic, or pathogenic. Variants may include missense, nonsense, and splice site variants and small intragenic deletions/insertions; typically, exon or whole-gene deletions/duplications are not detected. For issues to consider in interpretation of sequence analysis results, click [here](#).

4. Data derived from the subscription-based professional view of Human Gene Mutation Database [Stenson et al 2020]

5. Gene-targeted deletion/duplication analysis detects intragenic deletions or duplications. Methods used may include a range of techniques such as quantitative PCR, long-range PCR, multiplex ligation-dependent probe amplification (MLPA), and a gene-targeted microarray designed to detect larger deletions or duplications.

6. A tandem duplication of 85 bp (nt. 16_100) detected by sequence analysis was reported in two affected sibs who were also heterozygous for n.40C>T [Krøigård et al 2016]. To date, larger duplications or deletions have not been reported.

Clinical Characteristics

Clinical Description

To date, fewer than 100 individuals have been identified with *RNU4ATAC* biallelic pathogenic variants [Benoit-Pilven et al 2020].

In this *GeneReview*, the term "RNU4atac-opathy" refers to the entire phenotypic spectrum that can be associated with biallelic *RNU4ATAC* pathogenic variants. This includes the historically defined clinical diagnoses microcephalic osteodysplastic primordial dwarfism type I/III (MOPDI), Roifman syndrome, and Lowry-Wood syndrome, as well as varying combinations of disease features that do not match specific defined phenotypes (see Table 3). However, for the purposes of delineating the phenotypes included in the 2019 revision of the "Nosology and Classification of Genetic Skeletal Disorders" [Mortier et al 2019], much of the following discussion – when possible – is organized by the clinically described diagnoses.

Table 3. RNU4atac-opathy: Comparison of Phenotypes by Select Features

Feature	MOPDI ¹	Roifman Syndrome ¹	Lowry-Wood Syndrome ¹	Other Phenotypes ²
Growth restriction	+++ (extreme)	+++	+++	+++
Microcephaly	+++ (extreme)	++	+++	+++
Skeletal dysplasia	+++ (SEMD)	+++ (SED)	+++ (MED)	+++
Cognitive impairment	+++ (profound)	++ (mild)	++ (mild)	++
Brain anomalies	+++ (complex)	+ (mild)	+ (mild)	+
Seizures	++	U	U	+
Strokes	+	U	U	U
Immunodeficiency	++	+++	+(subclinical)	++
Ophthalmologic involvement	++	++	++	++
Cardiac anomalies	++	+	+	+
Skin involvement	++	++	+	++
Genital anomalies	++ (males)	U	U	+(males)
Renal involvement	+	+	U	+
Gastrointestinal involvement	+	+	U	+
Hearing loss	+	+	U	+
Endocrine involvement	+	+	U	+

+ = reported / variably described; ++ = common; +++ = present in nearly all affected individuals; U = unknown / not reported
 MED = multiple epiphyseal dysplasia; MOPDI = microcephalic osteodysplastic primordial dwarfism type I/III (MOPDI); SED = spondyloepiphyseal dysplasia; SEMD = spondyloepimetaphyseal dysplasia

1. Phenotype clinically designated in the "primordial dwarfism and slender bones" group the 2019 revision of the "Nosology and Classification of Genetic Skeletal Disorders" [Mortier et al 2019]

2. Phenotypes not clinically designated in the 2019 revision of the "Nosology and Classification of Genetic Skeletal Disorders" [Mortier et al 2019]

Growth Restriction and Microcephaly

Pre- and postnatal growth restriction is typical in RNU4atac-opathy, with one published exception [McMillan et al 2021] (see Table 4).

Table 4. RNU4atac-opathy: Growth Restriction and Microcephaly

Feature	MOPDI ¹	Roifman Syndrome ¹	Lowry-Wood Syndrome ¹	Other Phenotypes ²
Growth restriction	Extreme growth restriction. ^{3, 4} Note: Persons w/the n.55G>A pathogenic variant have been taller (about 4 SD below mean). ³	Short stature	Length/height is 3.5 to 6.3 SD below mean ⁵	Short stature
Head circumference	Extreme microcephaly noted at birth that can progress to ≥9 SD below mean ³	Borderline to microcephalic ⁶	5 to 9 SD below mean ⁵	Microcephaly
Comment	Expectation for weight gain should be exceedingly slow (<2 g/day).			Degree of cognitive impairment is not correlated w/degree of microcephaly. ⁷

SD = standard deviation(s)

1. Phenotype clinically designated in the "primordial dwarfism and slender bones" group the 2019 revision of the "Nosology and Classification of Genetic Skeletal Disorders" [Mortier et al 2019]

2. Phenotypes not clinically designated in the 2019 revision of the "Nosology and Classification of Genetic Skeletal Disorders" [Mortier et al 2019]

3. Abdel-Salam et al [2016], Putoux et al [2016]

4. Primordial Dwarfism Registry

5. Farach et al [2018]

6. Merico et al [2015]

7. MB and AD, personal observation

Skeletal Dysplasia

While all individuals with RNU4atac-opathy have epiphyseal involvement, the extent of skeletal involvement varies across the phenotypic spectrum (see Table 5). See also Figure 1.

Table 5. RNU4atac-opathy: Skeletal Dysplasia

Feature	MOPDI ¹	Roifman Syndrome ¹	Lowry-Wood Syndrome ¹	Other Phenotypes ²
Epiphyseal involvement	+++ (SEMD)	+++ (SED)	+++ (MED)	+++
Mesomelia	+++	U	+	++
Disproportion	+++ (short-limbed dwarfism w/flexion contractures)	++ (short-trunk or proportionate short stature)	++ (short-trunk or proportionate short stature)	++ (short-trunk or proportionate short stature)
Flattened/horizontal acetabulum & short/broad femoral necks	++	++	++	++
Brachydactyly, tapered fingers, & 5th finger clinodactyly ³	++	++	++	++
Coxa vara, genu valgum	+	++	++	++
Irregular vertebrae ⁴	+	+	U	+
Dislocated hips ⁵	+	U	+	U

Table 5. continued from previous page.

Feature	MOPDI ¹	Roifman Syndrome ¹	Lowry-Wood Syndrome ¹	Other Phenotypes ²
Osteopenia & fractures ⁶	+	U	U	U
Patellar hypoplasia ⁶	+	U	U	U
Scoliosis ⁷	+	U	+	+

+ = reported / variably described; ++ = common; +++ = present in nearly all affected individuals; U = unknown / not reported
 MED = multiple epiphyseal dysplasia; SED = spondyloepiphyseal dysplasia; SEMD = spondyloepimetaphyseal dysplasia

1. Phenotype clinically designated in the "primordial dwarfism and slender bones" group the 2019 revision of the "Nosology and Classification of Genetic Skeletal Disorders" [Mortier et al 2019]

2. Phenotypes not clinically designated in the 2019 revision of the "Nosology and Classification of Genetic Skeletal Disorders" [Mortier et al 2019]

3. Lowry et al [1989], Putoux et al [2016], Dinur Schejter et al [2017], Hallermayr et al [2018], Shelihan et al [2018]

4. Dinur Schejter et al [2017]; MB and AD, personal observation

5. Abdel-Salam et al [2016]; Shelihan et al [2018]; MB and AD, personal observation

6. Berger et al [1998]; MB and AD, personal observation

7. Farach et al [2018]; Shelihan et al [2018]; MB and AD, personal observation

Developmental Delay / Cognitive Impairment

It is important to note that the degree of cognitive impairment does not correlate with the degree of microcephaly. See Table 6.

Table 6. RNU4atac-opathy: Developmental Delay / Cognitive Impairment

Feature	MOPDI ¹	Roifman Syndrome ¹	Lowry-Wood Syndrome ¹	Other Phenotypes ²
DD/ID	Profound DD & cognitive impairment ³	DD & mild ID may be observed.		DD & mild-to-moderate ID may be observed.
Comment	Children sometimes achieve sitting but often do not achieve milestones of standing/ walking/talking. More than 1 family has described their child as a "forever infant" given their small size & developmental level.	Children achieve ability to talk & ambulate. ⁴ However, cognitive functioning may be more impaired on formal testing than perceived by family & teachers. ⁵		

DD = developmental delay; ID = intellectual disability

1. Phenotype clinically designated in the "primordial dwarfism and slender bones" group the 2019 revision of the "Nosology and Classification of Genetic Skeletal Disorders" [Mortier et al 2019]

2. Phenotypes not clinically designated in the 2019 revision of the "Nosology and Classification of Genetic Skeletal Disorders" [Mortier et al 2019]

3. Pierce & Morse [2012]

4. Roifman [1999], de Vries et al [2006], Abdel-Salam et al [2012], Nagy et al [2012], Krøigård et al [2016], Farach et al [2018], Hallermayr et al [2018]

5. Fairchild et al [2011]

Other Manifestations

Brain anomalies. Individuals with RNU4atac-opathy have had varying degrees of brain malformations (see Suggestive Findings).

In MOPDI, some individuals have required shunting for hydrocephalus and/or cyst drainage.

Seizures. Abnormal EEGs and seizures have been observed with children along the RNU4atac-opathy spectrum who have brain abnormalities [Abdel-Salam et al 2011] (see also Primordial Dwarfism Registry).

In MOPDI, seizures are common [Juric-Sekhar et al 2011, Pierce & Morse 2012] (see also Primordial Dwarfism Registry).

Strokes. Strokes have only been observed to date in MOPDI. Autopsies of young children have repeatedly identified acute and chronic infarcts most commonly in the brainstem but also in the frontal, parietal, and temporal lobes, hemispheric white matter, and deep grey nuclei [Winter et al 1985; Juric-Sekhar et al 2011; Primordial Dwarfism Registry].

During two separate episodes of physiologic stress, one individual with MOPDI experienced atypical hemorrhagic hypoxic events (that did not follow a vascular pattern and that included the cortex and brainstem) each of which resulted in a dramatic neurologic decline.

In another child, symptoms resulting from an acute ischemic event in the left frontal region (with no areas of significant stenosis noted on MRA) resolved within a few months.

Context of acute events has repeatedly been in times of stress, with significant illness and/or anesthesia, so minimizing unnecessary anesthesia is preferred.

Immunodeficiency. Immune system abnormalities are present from infancy onward. Hypogammaglobulinemia, impaired antibody responses, and B and/or T cell lymphopenia have been identified in individuals across the phenotypic spectrum [Roifman 1999, Kilic et al 2015, Bogaert et al 2017, Dinur Schejter et al 2017, Farach et al 2018, Hagiwara et al 2021] (see also Primordial Dwarfism Registry).

In many of these individuals, infection frequency and severity improved with immunoglobulin replacement therapy (see Management, Treatment of Manifestations).

In MOPDI, severe infection has been reported as a cause of early death [Sigaudy et al 1998, Abdel-Salam et al 2013].

Ophthalmologic findings. Retinal dystrophy (consistent with cone-rod dystrophy), as well as other eye findings, have been noted in some but not all individuals with RNU4atac-opathy. While details in findings over time in individuals reported with retinal dystrophy are limited [Lowry et al 1989], decreased visual acuity, constriction of visual fields, and night blindness would be expected to be progressive.

Cardiac. Cardiac malformations have been variably described across the RNU4atac-opathy spectrum. Cardiac septal defects (both atrial septal defect and ventricular septal defect) and aortic coarctation have been reported in multiple children [Sigaudy et al 1998, Gray et al 2011, Putoux et al 2016, Farach et al 2018, Hallermayr et al 2018]. Additionally, one individual with Roifman syndrome had left ventricular noncompaction and heart failure at age 14 years [Mandel et al 2001].

Skin. Skin findings have been noted across the RNU4atac-opathy spectrum, with many individuals having dry, eczematous skin with accompanying eosinophilia [Lowry & Wood 1975, Roifman 1999, Putoux et al 2016, Dinur Schejter et al 2017, Hallermayr et al 2018] (see also Primordial Dwarfism Registry).

Some individuals have fair skin/hair; one has also had features of ectodermal dysplasia with minimal sweating. Chilblain-like lesions have also been observed [Abdel-Salam et al 2011] (see also Primordial Dwarfism Registry).

In MOPDI, skin can be hyperkeratotic. Scant scalp hair and eyebrows are common, as are small nails and dental findings including enamel hypoplasia [Putoux et al 2016].

Genital anomalies. Cryptorchidism with or without micropenis is common [Abdel-Salam et al 2013, Kilic et al 2015, Abdel-Salam et al 2016, Krøigård et al 2016].

Renal involvement. In MOPDI, congenital anomalies of the kidney and urinary tract (CAKUT), including unilateral cystic or cystic dysplastic kidneys, have been reported. Electrolyte derangements suggestive of renal tubular dysfunction have been described in infants [Eason et al 1995, Berger et al 1998]. In one individual, a unilateral cystic kidney that apparently involuted resulted in hypertension [Edery et al 2011].

In Roifman syndrome, electrolyte derangements suggestive of renal tubular dysfunction have been described in late childhood [de Vries et al 2006].

Gastrointestinal. Gastrointestinal malformations are uncommon in RNU4atac-opathy; however, some hepatic dysfunction has been observed.

In MOPDI, persistent neonatal hyperbilirubinemia (not requiring additional intervention) with or without hepatosplenomegaly has been frequently reported [Taybi & Linder 1967, Berger et al 1998, Abdel-Salam et al 2011, Edery et al 2011, Ferrell et al 2016]. Also, fundoplication with gastrostomy tube placement has been performed due to feeding intolerance, gastroesophageal reflux disease (GERD), and/or increased risk of aspiration [Edery et al 2011, Abdel-Salam et al 2013, Hagiwara et al 2021] (see also Primordial Dwarfism Registry).

In Roifman syndrome, neonatal cholestasis and hepatosplenomegaly have been reported [Roifman 1999, Gray et al 2011, Hallermayr et al 2018]. Liver biopsy in one individual showed mild hepatic fibrosis [Robertson et al 2000], and another kinship had both hepatic fibrosis and extramedullary hematopoiesis [Gray et al 2011].

Hearing loss. Bilateral conductive, sensorineural, and mixed hearing loss have been observed in individuals with a RNU4atac-opathy, with at least one individual having bilateral Mondini malformations [Gray et al 2011, Pierce & Morse 2012, Abdel-Salam et al 2013, Kilic et al 2015, Merico et al 2015].

Endocrine. Diabetes insipidus has been reported for children with RNU4atac-opathy [Pierce & Morse 2012, McMillan et al 2021].

In Roifman syndrome, hypogonadotropic hypogonadism has been described for at least one individual [Robertson et al 2000].

In Lowry-Wood syndrome, normal pubertal development was noted for at least one male and one female [Lowry et al 1989] (see also Primordial Dwarfism Registry).

Life expectancy. Adults with RNU4atac-opathy have been reported [Krøigård et al 2016].

In MOPDI, although children have historically died in infancy or early childhood, they can also live for years. Death has often followed a severe infection with fever [Abdel-Salam et al 2013, Putoux et al 2016]. In hindsight, it is possible that many of these children had an unrecognized/untreated immunodeficiency associated with the RNU4atac-opathy spectrum. Identification and treatment of underlying immunodeficiency could improve life expectancy. Strokes in times of physiologic stress could also contribute to early death for those on the severe end of the RNU4atac-opathy spectrum.

Genotype-Phenotype Correlations

Genotype-phenotype correlations have been described, but due to the small number of individuals with RNU4atac-opathy, caution should be exercised in prospective prediction of phenotype severity. Intrafamilial variability has been reported [Abdel-Salam et al 2011, Gray et al 2011].

- **n.16G>A.** Two unrelated individuals homozygous for this variant in the stem II region had a Roifman syndrome phenotype [Benoit-Pilven et al 2020]. (See Figure 3.)
- **n.51G>A.** Individuals from 14 families who were homozygous for this variant had the MOPDI phenotype at the severe end of the RNU4atac-opathy spectrum [Benoit-Pilven et al 2020].

- **n.55G>A.** Individuals from five families who were homozygous for this variant had a more moderate phenotype [Benoit-Pilven et al 2020] with longer survival [Putoux et al 2016, McMillan et al 2021].

Nomenclature

The term "RNU4atac-opathy" refers to the entire phenotypic spectrum that can be associated with biallelic *RNU4ATAC* pathogenic variants and encompasses the historically designated clinical diagnoses microcephalic osteodysplastic primordial dwarfism type I/III (MOPDI) / Taybi-Linder syndrome [Taybi & Linder 1967], Roifman syndrome [Roifman 1999, Hallermayr et al 2018], and Lowry-Wood syndrome [Lowry et al 1989, Shelihan et al 2018], as well as varying combinations of disease features / system involvement that do not match clinically defined phenotypes. Given the totality of the variability associated with biallelic *RNU4ATAC* pathogenic variants, the authors of this *GeneReview* recommend RNU4atac-opathy as the best diagnostic name, as this molecularly defined term does not imply a specific subset of *RNU4ATAC*-associated features (in contrast to the clinically defined diagnoses).

MOPDI, Roifman syndrome, and Lowry-Wood syndrome are listed in the "primordial dwarfism and slender bones" group of the 2019 revision of the "Nosology and Classification of Genetic Skeletal Disorders" [Mortier et al 2019].

Prevalence

To date, fewer than 100 individuals have been reported worldwide with biallelic *RNU4ATAC* pathogenic variants [Benoit-Pilven et al 2020]. However, milder phenotypes in the RNU4atac-opathy spectrum are likely underrecognized, particularly as *RNU4ATAC* is not often included on exome sequencing.

The n.51G>A variant is a founder variant in the Amish population [Nagy et al 2012].

Genetically Related (Allelic) Disorders

No phenotypes other than those discussed in this *GeneReview* are known to be associated with germline pathogenic variants in *RNU4ATAC*.

Differential Diagnosis

The differential diagnosis of RNU4atac-opathy depends on presenting features and the severity of the findings on the phenotype spectrum. While the differential diagnosis can be narrowed for individuals with a severe phenotype, the differential diagnosis for individuals with milder growth restriction and skeletal dysplasia is extensive; thus, all genes known to be associated with the primary clinical finding (e.g., microcephaly / skeletal dysplasia / retinal dystrophy / immunodeficiency) should be considered.

Growth Restriction

When growth restriction is extreme (occipitofrontal circumference and height >4 SD below the mean), the differential diagnosis is the same as for other forms of microcephalic dwarfism (see Microcephalic Osteodysplastic Primordial Dwarfism Type II, [Differential Diagnosis](#)). Brain malformations and skeletal features are significant discriminants in individuals with extreme growth restriction and may allow for a clinical/syndromic diagnosis of RNU4atac-opathy.

Milder growth restriction has a wider differential, in which either skeletal dysplasia, retinal dystrophy, and/or immunodeficiency may provide diagnostic prompts.

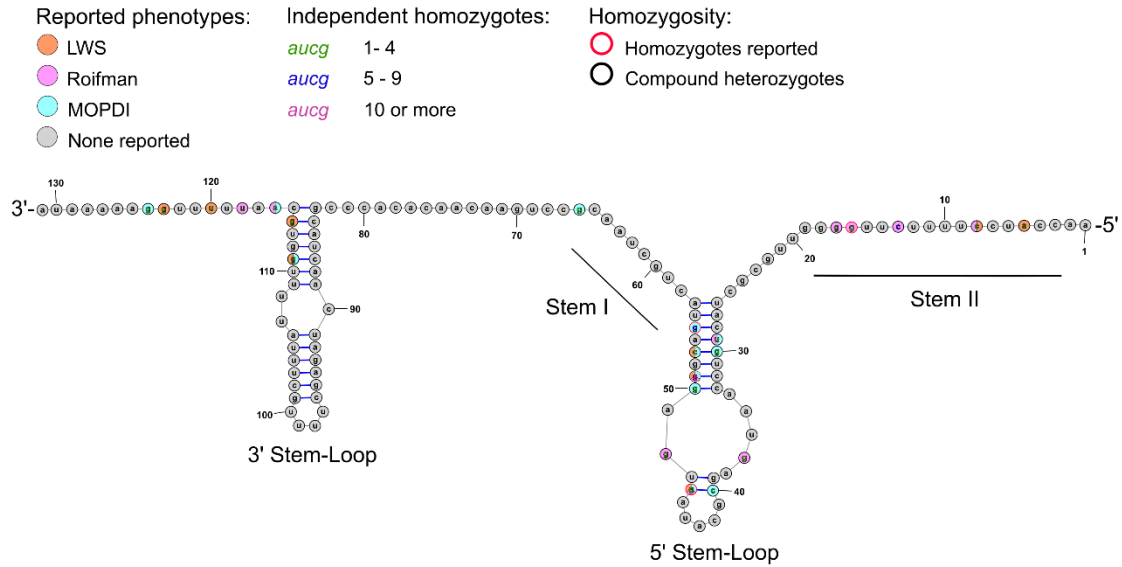


Figure 3. Reported pathogenic variants in RNU4atac-opathy

In addition to the single nucleotide variants shown, a disease-associated tandem 85-bp duplication (nt. 16_100) has been reported [Krøigård et al 2016]. Note: Pathogenic variants are labeled with the phenotype assigned by Benoit-Pilven et al [2020]. Individuals with moderate disease are therefore not distinguished.

LWS = Lowry-Wood syndrome; MOPDI = microcephalic osteodysplastic primordial dwarfism type I/III; Roifman = Roifman syndrome

Adapted from Benoit-Pilven et al [2020]

Skeletal Dysplasia

Epiphyseal dysplasia (with or without spondylo/metaphyseal involvement) alongside microcephaly should be strongly discriminant for RNU4atac-opathy with a limited differential diagnosis, particularly if immunodeficiency and/or retinal dystrophy is also present (see Table 7).

Individuals with RNU4atac-opathy do not always have microcephaly; therefore, absence of this clinical feature does not exclude the diagnosis.

Table 7. Skeletal Dysplasias Associated with Microcephaly in the Differential Diagnosis of RNU4atac-opathy

Gene(s)	Disorder	MOI	Key Features of Disorder	
			Overlapping w/RNU4atac-opathy	Distinguishing from RNU4atac-opathy
CDC6 CDC45 CDT1 GMNN ORC1 ORC4 ORC6	Meier-Gorlin syndrome (OMIM PS224690)	AR AD ¹	IUGR, extreme short stature w/ microcephaly; patella hypoplasia	Microtia; craniosynostosis; congenital lobar emphysema; typically normal intellect
COG4	Saul-Wilson syndrome	AD	IUGR, extreme short stature; occasional microcephaly; retinal dystrophy & hearing loss; intermittent neutropenia (but no known B cell defects)	Relative macrocephaly; distinct facial features; megaepiphyses; lamellar cataracts; clubfoot; normal intellect

Table 7. continued from previous page.

Gene(s)	Disorder	MOI	Key Features of Disorder	
			Overlapping w/RNU4atac-opathy	Distinguishing from RNU4atac-opathy
<i>PCNT</i>	Microcephalic osteodysplastic primordial dwarfism type II	AR	IUGR, extreme short stature; microcephaly; neurovascular disease	Distinct facial features; renovascular & cardiovascular disease; microdontia; insulin resistance
<i>POLE</i>	IMAGe-I syndrome (OMIM 618336)	AR	IUGR, extreme short stature; often microcephalic; immune dysfunction (T, B, or NK cell lymphopenia or hypogammaglobulinemia)	Adrenal insufficiency; cryptorchidism, small penis; distinct facial features (long, thin nose, small, low-set, posteriorly rotated ears); short wide neck; metaphyseal changes often absent or mild (linear striations)
<i>RMRP</i>	Cartilage-hair hypoplasia – anauxetic dysplasia spectrum disorders	AR	Growth deficiency; sparse hair; immune dysfunction (e.g., CVID, SCID); microcephaly sometimes a feature of CHH (OFC range: 4 SD below to 2 SD above the mean)	Disproportionately long fibula; anemia; predisposition to malignancy; intestinal dysfunction (e.g., congenital megacolon, Hirschsprung disease); head circumference can be normal
<i>POPI</i>	Anauxetic dysplasia 2 (OMIM 617396)	AR	Short stature	Metaphyseal dysplasia; no clinical symptoms of immunodeficiency
<i>NEPRO</i>	Anauxetic dysplasia 3 (OMIM 618853)	AR	Short stature; hair hypoplasia	Metaphyseal dysplasia; no clinical symptoms or laboratory signs of immunodeficiency
<i>SMARCAL1</i>	Schimke immunosseous dysplasia	AR	IUGR, extreme short stature; ± microcephaly; neurovascular disease; immune dysfunction (T cell lymphocyte deficiency rather than humoral deficiency)	Disproportionately short trunk; focal segmental glomerulosclerosis / nephrotic syndrome, leading to progressive kidney failure

AD = autosomal dominant; AR = autosomal recessive; CVID = combined variable immunodeficiency; IUGR = intrauterine growth restriction; MOI = mode of inheritance; SCID = severe combined immunodeficiency; SD = standard deviation(s)

1. Meier-Gorlin syndrome is inherited in an autosomal recessive manner with the exception of *GMNN*-related Meier-Gorlin syndrome, which is inherited in an autosomal dominant manner.

Other Genes Identified in Individuals with Growth Deficiency and Microcephaly

The genes listed below are those in which pathogenic variants were identified in at least two persons in a cohort of individuals with microcephalic dwarfism (defined as height and head circumference both greater than 4 SD below the mean at the time of exam) [A], personal communication]. Other genes are also associated with extreme microcephalic dwarfism in some persons.

- *ASPM*
- *ATR*
- *BLM*
- *CDK5RAP2*
- *CPAP (CENPJ)*
- *CEP152*
- *DNA2*
- *DNMT3A*
- *DONSON*
- *ERCC6*

- *IGF1R*
- *NBN*
- *NCAPD3*
- *PHGDH*
- *PLK4*
- *PRIM1*
- *RTTN*
- *SMARCAL1*
- *SRCAP*
- *TOP3A*
- *TRAIP*
- *VPS13B*

Management

No clinical practice guidelines for RNU4atac-opathy have been published. The recommendations in this section are based on the authors' experience in caring for 20 individuals over almost 20 years.

Evaluations Following Initial Diagnosis

To establish the extent of disease and needs in an individual diagnosed with RNU4atac-opathy, the evaluations summarized in Table 8 (if not performed as part of the evaluation that led to the diagnosis) are recommended.

Table 8. RNU4atac-opathy: Recommended Evaluations Following Initial Diagnosis

System/Concern	Evaluation	Comment
Growth	Measure height, weight, & head circumference.	For MOPDI, expectation for weight gain should be exceedingly slow growth (<2 g/day)
Gastrointestinal/Feeding	To incl eval of aspiration risk & nutritional status	Consider eval for gastrostomy tube placement in persons w/ dysphagia &/or aspiration risk.
Skeletal dysplasia	AP/lateral full spine, flexion-extension cervical spine, & AP lower extremity radiographs	To screen for scoliosis, cervical spine instability, hip dislocation, & lower extremity alignment
Cognitive impairment	Developmental assessment	<ul style="list-style-type: none"> • To incl motor, adaptive, cognitive, & speech-language eval • Eval for early intervention / special education
Neurologic	Neurologic assessment	<ul style="list-style-type: none"> • Baseline brain MRI if not previously performed • Consider EEG if seizures are a concern. • Referral to neurologist as indicated
Immunodeficiency	Immunologist consultation w/lab eval	<p>Perform immunologic eval prior to administering live vaccines:</p> <ul style="list-style-type: none"> • Immunoglobulins (IgG, IgA, IgM) • Tetanus & pneumococcal antibody titers • Complete blood count w/differential • Lymphocyte subsets <p>Consider, based on above results & infection history:</p> <ul style="list-style-type: none"> • B cell phenotyping • T lymphocyte proliferation assay

Table 8. continued from previous page.

System/Concern	Evaluation	Comment
Ophthalmologic	Ophthalmologic eval	To assess for ↓ vision, abnormal ocular movement, refractive errors, strabismus, & more complex findings (e.g., cataract, retinal dystrophy) that may require referral for subspecialty care &/or low vision services
Cardiac	Echocardiogram	To assess for structural malformations or evidence of cardiomyopathy
Liver	Measure transaminases & direct & conjugated bilirubin levels.	Most important in neonatal period
Genital	Assess for cryptorchidism & micropenis in males.	
Renal	Assess renal function & kidney & urinary tract structure	Assess for: <ul style="list-style-type: none"> Evidence of renal tubular acidosis; Renal ultrasound for CAKUT incl cystic or dysplastic kidneys.
Hearing loss	Otolaryngology exam	To evaluate possible causes of conductive hearing loss, if present
	Audiogram	To document baseline & determine need for intervention
Genetic counseling	By genetics professionals ¹	To inform persons w/RNU4atac-opathy & their families re nature, MOI, & implications of RNU4atac-opathy to facilitate medical & personal decision making
Family support & resources	Assess need for: <ul style="list-style-type: none"> Community or online resources such as Parent to Parent; Social work involvement for parental support; Home nursing referral. 	

AP = anteroposterior; CAKUT = congenital anomalies of the kidney and urinary tract; MOI = mode of inheritance; MOPDI = microcephalic osteodysplastic primordial dwarfism type I/III

1. Medical geneticist, certified genetic counselor, certified advanced genetic nurse

Treatment of Manifestations

Supportive care to improve quality of life, maximize function, and reduce complications is recommended. This ideally involves multidisciplinary care by specialists in relevant fields (see Table 9).

Table 9. RNU4atac-opathy: Treatment of Manifestations

Manifestation/Concern	Treatment	Considerations/Other
Growth	At severe end of phenotypic spectrum (MOPDI), gastrostomy tube & Nissen fundoplication may be indicated for children who cannot orally feed, who aspirate, or who are unable to meet weight gain expectations.	
Skeletal dysplasia	<ul style="list-style-type: none"> Standard treatments as indicated by orthopedics If possible, referral to skeletal dysplasia center for care 	For those who are ambulatory, limit repetitive pounding activities to maximize joint preservation & minimize pain assoc w/epiphyseal dysplasia.

Table 9. continued from previous page.

Manifestation/Concern	Treatment	Considerations/Other
Cognitive impairment	See Developmental Delay / Intellectual Disability Management Issues.	
Neurologic	Standard treatment for seizures as indicated by neurologist	<ul style="list-style-type: none"> • Shunting may be required for interhemispheric cyst or hydrocephalus. • MOPDI: Minimize medically stressful situations as much as possible, incl stress during anesthesia, due to energy-related strokes.
Immunodeficiency	Standard treatment per immunologist, incl immunoglobulin replacement therapy if indicated	<ul style="list-style-type: none"> • Prompt identification & treatment of infections requiring antibiotics • Antimicrobial prophylaxis may be indicated for some persons.
Ophthalmologic	Standard treatment per ophthalmologist	For refractive errors, strabismus, cataracts
	Low vision services for those w/visual impairment	Initiate low vision therapies, cane skills, etc., through school or low vision clinics.
Cardiac	Standard treatment per cardiologist	
GI	Standard treatment per gastroenterologist	
Skin	Standard treatment per dermatologist	Typically over-the-counter emollients; topical corticosteroids used in some instances
Genital	Standard treatment per urologist/endocrinologist	
Renal	<ul style="list-style-type: none"> • Standard treatment of CAKUT by urologist • Standard treatment of renal functional impairment by nephrologist 	
Hearing loss	Standard treatment per otolaryngologist/audiologist	

MOPDI = microcephalic osteodysplastic primordial dwarfism type I/III

Developmental Delay / Intellectual Disability Management Issues

The following information represents typical management recommendations for individuals with developmental delay / intellectual disability in the United States; standard recommendations may vary from country to country.

Ages 0-3 years. Referral to an early intervention program is recommended for access to occupational, physical, speech, and feeding therapy as well as infant mental health services, special educators, and sensory impairment specialists. In the US, early intervention is a federally funded program available in all states that provides in-home services to target individual therapy needs.

Ages 3-5 years. In the US, developmental preschool through the local public school district is recommended. Before placement, an evaluation is made to determine needed services and therapies and an individualized education plan (IEP) is developed for those who qualify based on established motor, language, social, or cognitive delay. The early intervention program typically assists with this transition. Developmental preschool is center based; for children too medically unstable to attend, home-based services are provided.

All ages. Consultation with a developmental pediatrician is recommended to ensure the involvement of appropriate community, state, and educational agencies (US) and to support parents in maximizing quality of life. Some issues to consider:

- IEP services:
 - An IEP provides specially designed instruction and related services to children who qualify.

- IEP services will be reviewed annually to determine whether any changes are needed.
- Special education law requires that children participating in an IEP be in the least restrictive environment feasible at school and included in general education as much as possible, when and where appropriate.
- Vision and hearing consultants should be a part of the child's IEP team to support access to academic material.
- Physical accommodations for short stature should be a part of the IEP.
- PT, OT, and speech services will be provided in the IEP to the extent that the need affects the child's access to academic material. Beyond that, private supportive therapies based on the affected individual's needs may be considered. Specific recommendations regarding type of therapy can be made by a developmental pediatrician.
- As a child enters the teen years, a transition plan should be discussed and incorporated in the IEP. For those receiving IEP services, the public school district is required to provide services until age 21.
- A 504 plan (Section 504: a US federal statute that prohibits discrimination based on disability) can be considered for those who require accommodations or modifications such as front-of-class seating, assistive technology devices, classroom scribes, extra time between classes, modified assignments, enlarged text, and modified classroom equipment/furniture for short stature.
- Developmental Disabilities Administration (DDA) enrollment is recommended. DDA is a US public agency that provides services and support to qualified individuals. Eligibility differs by state but is typically determined by diagnosis and/or associated cognitive/adaptive disabilities.
- Families with limited income and resources may also qualify for supplemental security income (SSI) for their child with a disability.

Surveillance

To monitor existing manifestations, the individual's response to supportive care, and the emergence of new manifestations, the evaluations listed in Table 10 are recommended.

Table 10. RNU4atac-opathy: Recommended Surveillance

System/Concern	Evaluation	Frequency
Growth	In children w/MOPDI, expectation should be for exceedingly slow growth (<2g/day).	At each visit
Skeletal dysplasia	Monitor lower extremity alignment & spinal curves.	Annually, through age of skeletal maturity, or more often as needed
Cognitive impairment	Monitor developmental progress & educational needs.	At each visit
Neurology	<ul style="list-style-type: none"> • In children w/MOPDI, be aware that stroke can occur & that brain MRI could be warranted if deterioration is apparent.¹ • Low threshold for EEG, as seizures can be associated 	As clinically indicated
Immunodeficiency	Monitor w/immunoglobulins (IgG, IgA, IgM) & complete blood count w/differential.	<ul style="list-style-type: none"> • Annually; more often as clinically indicated • Repeat immune eval as performed on initial diagnosis (see Table 8) may be indicated depending on course.
Ophthalmologic	Assessment of visual acuity & visual fields followed by dilated eye exam w/attention to any other potential findings due to cataracts &/or progression of retinal dystrophy	Annually or as clinically indicated
	Low vision needs	Per low vision service provider

Table 10. continued from previous page.

System/Concern	Evaluation	Frequency
Cardiac	Per treating cardiologist	Per treating cardiologist
Gastrointestinal	Per treating gastroenterologist	Per treating gastroenterologist
Skin	Per treating dermatologist	Per treating dermatologist
Genital	Per treating endocrinologist/urologist	Per treating endocrinologist/urologist
Renal	Per treating nephrologist for evidence of renal dysfunction	Per treating nephrologist
Hearing	Per treating otolaryngologist/audiologist	Per treating otolaryngologist/audiologist

MOPDI = microcephalic osteodysplastic primordial dwarfism type I/III

1. As prenatal and postnatal strokes have not followed a vascular distribution and were associated with normal vascular anatomy, a screening brain MRA/I (as recommended with [microcephalic primordial dwarfism type II](#)) would seem ineffective and is **not** recommended.

Agents/Circumstances to Avoid

For those with microcephalic osteodysplastic primordial dwarfism type I/III (MOPDI), minimize medically stressful situations as much as possible, including stress during anesthesia, due to energy-related strokes previously described in MOPDI.

Perform immunologic evaluation prior to administration of live vaccines.

Evaluation of Relatives at Risk

See Genetic Counseling for issues related to testing of at-risk relatives for genetic counseling purposes.

Therapies Under Investigation

Search [ClinicalTrials.gov](#) in the US and [EU Clinical Trials Register](#) in Europe for access to information on clinical studies for a wide range of diseases and conditions. Note: There may not be clinical trials for this disorder.

Genetic Counseling

Genetic counseling is the process of providing individuals and families with information on the nature, mode(s) of inheritance, and implications of genetic disorders to help them make informed medical and personal decisions. The following section deals with genetic risk assessment and the use of family history and genetic testing to clarify genetic status for family members; it is not meant to address all personal, cultural, or ethical issues that may arise or to substitute for consultation with a genetics professional. —ED.

Mode of Inheritance

RNU4atac-opathy is inherited in an autosomal recessive manner.

Risk to Family Members

Parents of a proband

- The parents of an affected child are presumed to be heterozygous for an *RNU4ATAC* pathogenic variant.
- Molecular genetic testing is recommended for the parents of a proband to confirm that both parents are heterozygous for an *RNU4ATAC* pathogenic variant and to allow reliable recurrence risk assessment.

- If a pathogenic variant is detected in only one parent and parental identity testing has confirmed biological maternity and paternity, it is possible that one of the pathogenic variants identified in the proband occurred as a *de novo* event in the proband or as a postzygotic *de novo* event in a mosaic parent [Jónsson et al 2017]. If the proband appears to have homozygous pathogenic variants (i.e., the same two pathogenic variants), additional possibilities to consider include:
 - A single- or multiexon deletion in the proband that was not detected by sequence analysis and that resulted in the artifactual appearance of homozygosity;
 - Uniparental isodisomy for the parental chromosome with the pathogenic variant that resulted in homozygosity for the pathogenic variant in the proband.
- Heterozygotes (carriers) are asymptomatic and are not at risk of developing the disorder.

Sibs of a proband

- If both parents are known to be heterozygous for an *RNU4ATAC* pathogenic variant, each sib of an affected individual has at conception a 25% chance of being affected, a 50% chance of being an asymptomatic carrier, and a 25% chance of inheriting neither of the familial pathogenic variants.
- Intrafamilial clinical variability has been reported between sibs who inherit the same biallelic *RNU4ATAC* pathogenic variants [Abdel-Salam et al 2011, Gray et al 2011, Bogaert et al 2017].
- Heterozygotes (carriers) are asymptomatic and are not at risk of developing the disorder.

Offspring of a proband. Unless an affected individual's reproductive partner also has *RNU4atac*-opathy or is a carrier, offspring will be obligate heterozygotes (carriers) for a pathogenic variant in *RNU4ATAC*.

Other family members. Each sib of the proband's parents is at a 50% risk of being a carrier of an *RNU4ATAC* pathogenic variant.

Carrier Detection

Carrier testing for at-risk relatives requires prior identification of the *RNU4ATAC* pathogenic variants in the family.

Related Genetic Counseling Issues

Family planning

- The optimal time for determination of genetic risk and discussion of the availability of prenatal/preimplantation genetic testing is before pregnancy.
- It is appropriate to offer genetic counseling (including discussion of potential risks to offspring and reproductive options) to young adults who are affected, are carriers, or are at risk of being carriers.
- Carrier testing for the reproductive partners of known carriers and for the reproductive partners of individuals affected with *RNU4atac*-opathy can be considered. An *RNU4ATAC* founder variant has been identified in individuals of Amish descent (see Table 11).

Prenatal Testing and Preimplantation Genetic Testing

Once the *RNU4ATAC* pathogenic variants have been identified in an affected family member, prenatal and preimplantation genetic testing are possible.

Differences in perspective may exist among medical professionals and within families regarding the use of prenatal and preimplantation genetic testing. While most health care professionals would consider use of prenatal and preimplantation genetic testing to be a personal decision, discussion of these issues may be helpful.

Resources

GeneReviews staff has selected the following disease-specific and/or umbrella support organizations and/or registries for the benefit of individuals with this disorder and their families. GeneReviews is not responsible for the information provided by other organizations. For information on selection criteria, click [here](#).

- **Dwarfism Support Organizations and Groups**
www.lpaonline.org/dwarfism-support-organizations
- **Little People of America**
Phone: 888-LPA-2001; 714-368-3689
Fax: 707-721-1896
Email: info@lpaonline.org
lpaonline.org
- **Little People UK**
United Kingdom
Phone: 07925893398
Email: admin@littlepeopleuk.org
littlepeopleuk.org
- **Potentials Foundation**
Email: potentialsfoundation@gmail.com
www.potentialsfoundation.org
- **Walking with Giants Foundation**
United Kingdom
Phone: +44 151-526-0134
Email: enquiries@walkingwithgiants.org
www.walkingwithgiants.org
- **Primordial Dwarfism Registry**
Nemours Children's Health
1600 Rockland Road
Wilmington DE 19803
Phone: 302-651-4181
Email: aduker@nemours.org
[ClinicalTrials.gov Identifier: NCT04569149](https://clinicaltrials.gov/ct2/show/study/NCT04569149)
- **UCLA International Skeletal Dysplasia Registry (ISDR)**
Phone: 310-825-8998
[International Skeletal Dysplasia Registry](http://InternationalSkeletalDysplasiaRegistry.org)

Molecular Genetics

Information in the Molecular Genetics and OMIM tables may differ from that elsewhere in the GeneReview: tables may contain more recent information. —ED.

Table A. RNU4atac-opathy: Genes and Databases

Gene	Chromosome Locus	Protein	HGMD	ClinVar

Table A. continued from previous page.

RNU4ATAC	2q14.2	N/A (non-coding RNA)	RNU4ATAC	RNU4ATAC
--------------------------	--------	----------------------	--------------------------	--------------------------

Data are compiled from the following standard references: gene from [HGNC](#); chromosome locus from [OMIM](#); protein from [UniProt](#). For a description of databases (Locus Specific, HGMD, ClinVar) to which links are provided, click [here](#).

Table B. OMIM Entries for RNU4atac-opathy ([View All in OMIM](#))

210710	MICROCEPHALIC OSTEODYSPLASTIC PRIMORDIAL DWARFISM, TYPE I; MOPD1
226960	LOWRY-WOOD SYNDROME; LWS
601428	RNA, U4ATAC SMALL NUCLEAR; RNU4ATAC
616651	ROIFMAN SYNDROME; RFMN

Molecular Pathogenesis

RNU4ATAC encodes a noncoding RNA, U4atac, which forms part of the minor spliceosome, a complex responsible for removing minor introns. Minor introns are present in about 700 human transcripts and are distinguished from major introns by different splice site and branch point sequences. Like the major spliceosomes, the minor spliceosomes are a ribonucleoprotein complex. Although the two types of spliceosomes share many proteins, their noncoding RNA complements are largely unique: U4atac, U11, U12, and U6atac are found only in the minor spliceosome, whereas U5 is shared with the major complex [Bai et al 2021]. U4atac binds U6atac and loads it on U12-containing complexes, creating a catalytically active minor spliceosome. Most pathogenic *RNU4ATAC* variants do not reduce the abundance of this RNA, but instead destabilize its RNA:RNA interactions or RNA:protein interactions [Jafarifar et al 2014].

RNU4ATAC pathogenic variants impair minor intron excision; however, the extent of intron retention varies among transcripts and tissues [Cologne et al 2019]. Intron retention appears to be more pronounced in monocytes, with one study reporting rates of 25%-40% in affected individuals compared to 2%-4% in controls [Merico et al 2015]. Intron retention may reduce translation by introducing premature stop codons; increased retention in particular tissues or transcripts may account for certain phenotypes in RNU4atac-opathy [Heremans et al 2018].

Mechanism of disease causation. Partial loss of function

***RNU4ATAC*-specific laboratory technical considerations.** Interpreting novel *RNU4ATAC* variants is challenging as many computational prediction algorithms are not applicable to noncoding RNAs and cannot distinguish benign from pathogenic variants [Benoit-Pilven et al 2020]. However, disease-associated variants in U4atac cluster in three important regions (see Figure 3):

- The 5' stem II region. Interacts with U6atac (n.1-19)
- The 5' stem loop structure. Interacts with RNA binding proteins during minor spliceosome assembly (n.26-57)
- The Sm protein binding region at the 3' end of the molecule. Sm proteins are required for small nuclear RNA maturation (n.83-115).

Mapping novel variants to the Figure 3 schematic may provide some insight, with variants close to reported variants in functional regions having a higher chance of being clinically significant. Although functional assays would be preferable to confirm clinical relevance, to the authors' knowledge these are not available diagnostically. Benoit-Pilven et al [2020] developed a relevant functional assay to measure cellular minor intron splicing in fibroblasts in which cells are transfected with two plasmids, one encoding a minor intron gene and the other *RNU4ATAC* of either wild type or mutated sequence. Minor intron excision is measured with

quantitative PCR. Most pathogenic variants show significantly reduced splicing compared to wild types, whereas most incidental variants behave as wild types. Note: A limitation of this assay is the misclassification of n.124G>A, which reduces the level of the RNA itself, a finding that cannot be detected by this overexpression assay.

Table 11. Notable *RNU4ATAC* Pathogenic Variants

Reference Sequence	DNA Nucleotide Change	Comment [Reference]
NR_023343.1	n.16G>A	Only variant found in homozygous state in persons w/Roifman syndrome to date [Benoit-Pilven et al 2020]
	n.51G>A	Founder variant in Amish population (Ohio, US) [Benoit-Pilven et al 2020]
	n.55G>A	Second most common disease-assoc variant [Benoit-Pilven et al 2020]
	n.124G>A	Assoc w/↓ U4atac levels but not reduction of splicing in cellular assay [Benoit-Pilven et al 2020]
	85-bp dup (nt. 16_100) ¹	Krøigård et al [2016]

Variants listed in the table have been provided by the authors. *GeneReviews* staff have not independently verified the classification of variants.

GeneReviews follows the standard naming conventions of the Human Genome Variation Society (varnomen.hgvs.org). See [Quick Reference](#) for an explanation of nomenclature.

1. Variant designation that does not conform to current naming conventions

Chapter Notes

Author Notes

Angela Duker and Michael B Bober are actively involved in clinical research regarding individuals with RNU4atac-opathy. They would be happy to communicate with persons who have any questions regarding this diagnosis or other considerations.

Andrew Jackson is interested in hearing from clinicians treating families affected by microcephalic dwarfism or findings suggestive of an RNU4atac-opathy in whom no causative variant has been identified through molecular genetic testing.

Acknowledgments

The authors wish to sincerely thank the Potentials Foundation and the Walking With Giants Foundation for their support of families worldwide with primordial dwarfism, as well as for their support of research on this condition. Work in the Jackson lab has been supported by the European Union's Horizon 2020 research and innovation program ERC Advanced Grant (788093) and by a UK Medical Research Council (MRC) Human Genetics Unit core grant (MRC, U127580972).

Revision History

- 16 February 2023 (bp) Review posted live
- 24 May 2022 (mb) Original submission

References

Literature Cited

- Abdel-Salam GM, Abdel-Hamid MS, Hassan NA, Issa MY, Effat L, Ismail S, Aglan MS, Zaki MS. Further delineation of the clinical spectrum in RNU4ATAC related microcephalic osteodysplastic primordial dwarfism type I. *Am J Med Genet A*. 2013;161A:1875-81. PubMed PMID: 23794361.
- Abdel-Salam GM, Abdel-Hamid MS, Issa M, Magdy A, El-Kotoury A, Amr K. Expanding the phenotypic and mutational spectrum in microcephalic osteodysplastic primordial dwarfism type I. *Am J Med Genet A*. 2012;158A:1455-61. PubMed PMID: 22581640.
- Abdel-Salam GM, Emam BA, Khalil YM, Abdel-Hamid MS. Long-term survival in microcephalic osteodysplastic primordial dwarfism type I: evaluation of an 18-year-old male with g.55G>A homozygous mutation in RNU4ATAC. *Am J Med Genet A*. 2016;170A:277-82. PubMed PMID: 26419500.
- Abdel-Salam GM, Miyake N, Eid MM, Abdel-Hamid MS, Hassan NA, Eid OM, Effat LK, El-Badry TH, El-Kamah GY, El-Darouti M, Matsumoto N. A homozygous mutation in RNU4ATAC as a cause of microcephalic osteodysplastic primordial dwarfism type I (MOPD I) with associated pigmentary disorder. *Am J Med Genet A*. 2011;155A:2885-96. PubMed PMID: 21990275.
- Bai R, Wan R, Wang L, Xu K, Zhang Q, Lei J, Shi Y. Structure of the activated human minor spliceosome. *Science*. 2021;371:eabg0879. PubMed PMID: 33509932.
- Benoit-Pilven C, Besson A, Putoux A, Benetollo C, Saccaro C, Guguin J, Sala G, Cologne A, Delous M, Lesca G, Padgett RA, Leutenegger AL, Lacroix V, Edery P, Mazoyer S. Clinical interpretation of variants identified in RNU4ATAC, a non-coding spliceosomal gene. *PLoS One*. 2020;15:e0235655. PubMed PMID: 32628740.
- Berger A, Haschke N, Kohlhauser C, Amman G, Unterberger U, Weninger M. Neonatal cholestasis and focal medullary dysplasia of the kidneys in a case of microcephalic osteodysplastic primordial dwarfism. *J Med Genet*. 1998;35:61-4. PubMed PMID: 9475098.
- Bogaert DJ, Dullaers M, Kuehn HS, Leroy BP, Niemela JE, De Wilde H, De Schryver S, De Bruyne M, Coppeters F, Lambrecht BN, De Baets F, Rosenzweig SD, De Baere E, Haerynck F. Early-onset primary antibody deficiency resembling common variable immunodeficiency challenges the diagnosis of Wiedeman-Steiner and Roifman syndromes. *Sci Rep*. 2017;7:3702. PubMed PMID: 28623346.
- Cologne A, Benoit-Pilven C, Besson A, Putoux A, Campan-Fournier A, Bober MB, De Die-Smulders CEM, Paulussen ADC, Pinson L, Toutain A, Roifman CM, Leutenegger AL, Mazoyer S, Edery P, Lacroix V. New insights into minor splicing—a transcriptomic analysis of cells derived from TALS patients. *RNA*. 2019;25:1130-49. PubMed PMID: 31175170.
- de Vries PJ, McCartney DL, McCartney E, Woolf D, Wozencroft D. The cognitive and behavioural phenotype of Roifman syndrome. *J Intellect Disabil Res*. 2006;50:690-6. PubMed PMID: 16901296.
- Dinur Schejter Y, Ovadia A, Alexandrova R, Thiruvahindrapuram B, Pereira SL, Manson DE, Vincent A, Merico D, Roifman CM. A homozygous mutation in the stem II domain of RNU4ATAC causes typical Roifman syndrome. *NPJ Genom Med*. 2017;2:23. PubMed PMID: 29263834.
- Eason J, Hall CM, Trounce JQ. Renal tubular leakage complicating microcephalic osteodysplastic primordial dwarfism. *J Med Genet*. 1995;32:234-5. PubMed PMID: 7783178.
- Edery P, Marcaillou C, Sahbatou M, Labalme A, Chastang J, Touraine R, Tubacher E, Senni F, Bober MB, Nampoothiri S, Jouk PS, Steichen E, Berland S, Toutain A, Wise CA, Sanlaville D, Rousseau F, Clerget-Darpoux F, Leutenegger AL. Association of TALS developmental disorder with defect in minor splicing component U4atac snRNA. *Science* 2011;332:240-3. PubMed PMID: 21474761.

- Fairchild HR, Fairchild G, Tierney KM, McCartney DL, Cross JJ, de Vries PJ. Partial agenesis of the corpus callosum, hippocampal atrophy, and stable intellectual disability associated with Roifman syndrome. *Am J Med Genet A*. 2011;155A:2560-5. PubMed PMID: 21910238.
- Farach LS, Little ME, Duker AL, Logan CV, Jackson A, Hecht JT, Bober M. The expanding phenotype of RNU4ATAC pathogenic variants to Lowry Wood syndrome. *Am J Med Genet A*. 2018;176:465-9. PubMed PMID: 29265708.
- Ferrell S, Johnson A, Pearson W. Microcephalic osteodysplastic primordial dwarfism type 1. *BMJ Case Rep*. 2016;2016:bcr2016215502. PubMed PMID: 27312855.
- Gray PE, Sillence D, Kakakios A. Is Roifman syndrome an X-linked ciliopathy with humoral immunodeficiency? Evidence from 2 new cases. *Int J Immunogenet*. 2011;38:501-5. PubMed PMID: 21977988.
- Hagiwara H, Matsumoto H, Uematsu K, Zaha K, Sekinaka Y, Miyake N, Matsumoto N, Nonoyama S. Immunodeficiency in a patient with microcephalic osteodysplastic primordial dwarfism type I as compared to Roifman syndrome. *Brain Dev*. 2021;43: 337-42. PubMed PMID: 33059947.
- Hallermayr A, Graf J, Koehler U, Laner A, Schönfeld B, Benet-Pagès A, Holinski-Feder E. Extending the critical regions for mutations in the non-coding gene RNU4ATAC in another patient with Roifman syndrome. *Clin Case Rep*. 2018;6:2224-8. PubMed PMID: 30455926.
- Heremans J, Garcia-Perez J, Turro E, Schlenner S, Casteels I, Collin R, de Zegher F, Greene D, Humblet-Baron S, Lesage S, Matthys P, Penkett C, Put K, Stirrups K, NIHR Bioresource, Thys C, Geet C, Nieuwenhove E, Wouters C, Meyts I, Freson K, Liston A. Abnormal differentiation of B cells and megakaryocytes in patients with Roifman syndrome. *J Allergy Clin Immunol*. 2018;142:630-46. PubMed PMID: 29391254.
- Jafarifar F, Dietrich R, Hiznay J, Padgett, R. Biochemical defects in minor spliceosome function in the developmental disorder MOPD I. *RNA*. 2014;20:1078-89. PubMed PMID: 24865609.
- Jónsson H, Sulem P, Kehr B, Kristmundsdóttir S, Zink F, Hjartarson E, Hardarson MT, Hjorleifsson KE, Eggertsson HP, Gudjonsson SA, Ward LD, Arnadóttir GA, Helgason EA, Helgason H, Gylfason A, Jonasdóttir A, Jonasdóttir A, Rafnar T, Frigge M, Stacey SN, Th Magnusson O, Thorsteinsdóttir U, Masson G, Kong A, Halldorsson BV, Helgason A, Gudbjartsson DF, Stefansson K. Parental influence on human germline de novo mutations in 1,548 trios from Iceland. *Nature*. 2017;549:519-22. PubMed PMID: 28959963.
- Juric-Sekhar G, Kapur RP, Glass IA, Murray ML, Parnell SE, Hevner RF. Neuronal migration disorders in microcephalic osteodysplastic primordial dwarfism type I/III. *Acta neuropathologica*. 2011;121:545-54. PubMed PMID: 20857301.
- Kilic E, Yigit G, Utine GE, Wollnik B, Mihci E, Nur BG, Boduroglu K. A novel mutation in RNU4ATAC in a patient with microcephalic osteodysplastic primordial dwarfism type I. *Am J Med Genet A*. 2015;167A:919-21. PubMed PMID: 25735804.
- Krøigård AB, Jackson AP, Bicknell LS, Baple E, Brusgaard K, Hansen LK, Ousager LB. Two novel mutations in RNU4ATAC in two siblings with an atypical mild phenotype of microcephalic osteodysplastic primordial dwarfism type 1. *Clin Dysmorphol*. 2016;25:68-72. PubMed PMID: 26641461.
- Lowry RB, Wood BJ. Syndrome of epiphyseal dysplasia, short stature, microcephaly and nystagmus. *Clin Genet*. 1975;8:269-74. PubMed PMID: 1183069.
- Lowry RB, Wood BJ, Cox TA, Hayden MR. Epiphyseal dysplasia, microcephaly, nystagmus, and retinitis pigmentosa. *Am J Med Genet*. 1989;33:341-5. PubMed PMID: 2801768.
- Mandel K, Grunebaum E, Benson L. Noncompaction of the myocardium associated with Roifman syndrome. *Cardiol Young*. 2001;11:240-3. PubMed PMID: 11293748.
- McMillan HJ, Davila J, Osmond M, Chakraborty P; Care4Rare Canada Consortium, Boycott KM, Dymont DA, Kernohan KD. Whole genome sequencing identifies pathogenic RNU4ATAC variants in a child with

- recurrent encephalitis, microcephaly, and normal stature. *Am J Med Genet A*. 2021;185:3502-6. PubMed PMID: 34405953.
- Merico D, Roifman M, Braunschweig U, Yuen RK, Alexandrova R, Bates A, Reid B, Nalpathamkalam T, Wang Z, Thiruvahindrapuram B, Gray P, Kakakios A, Peake J, Hogarth S, Manson D, Buncic R, Pereira SL, Herbrick JA, Blencowe BJ, Roifman CM, Scherer SW. Compound heterozygous mutations in the noncoding RNU4ATAC cause Roifman syndrome by disrupting minor intron splicing. *Nat Commun*. 2015;6:8718. PubMed PMID: 26522830.
- Mortier GR, Cohn DH, Cormier-Daire V, Hall C, Krakow D, Mundlos S, Nishimura G, Robertson S, Sangiorgi L, Savarirayan R, Sillence D, Superti-Furga A, Unger S, Warman ML. Nosology and classification of genetic skeletal disorders: 2019 revision. *Am J Med Genet A*. 2019;179:2393-419. PubMed PMID: 31633310.
- Nagy R, Wang H, Albrecht B, Wieczorek D, Gillessen-Kaesbach G, Haan E, Meinecke P, de la Chapelle A, Westman JA. Microcephalic osteodysplastic primordial dwarfism type I with biallelic mutations in the RNU4ATAC gene. *Clin Genet*. 2012;82:140-6. PubMed PMID: 21815888.
- Pierce MJ, Morse RP. The neurologic findings in Taybi-Linder syndrome (MOPD I/III): case report and review of the literature. *Am J Med Genet A*. 2012;158A:606-10. PubMed PMID: 22302400.
- Putoux A, Alqahtani A, Pinson L, Paulussen AD, Michel J, Besson A, Mazoyer S, Borg I, Nampoothiri S, Vasiljevic A, Uwineza A, Boggio D, Champion F, de Die-Smulders CE, Gardeitchik T, van Putten WK, Perez MJ, Musizzano Y, Razavi F, Drunat S, Verloes A, Hennekam R, Guibaud L, Alix E, Sanlaville D, Lesca G, Edery P. Refining the phenotypical and mutational spectrum of Taybi-Linder syndrome. *Clin Genet*. 2016;90:550-5. PubMed PMID: 27040866.
- Richards S, Aziz N, Bale S, Bick D, Das S, Gastier-Foster J, Grody WW, Hegde M, Lyon E, Spector E, Voelkerding K, Rehm HL, et al. Standards and guidelines for the interpretation of sequence variants: a joint consensus recommendation of the American College of Medical Genetics and Genomics and the Association for Molecular Pathology. *Genet Med*. 2015;17:405-24. PubMed PMID: 25741868.
- Robertson SP, Rodda C, Bankier A. Hypogonadotrophic hypogonadism in Roifman syndrome. *Clin Genet*. 2000;57:435-8. PubMed PMID: 10905663.
- Roifman CM. Antibody deficiency, growth retardation, spondyloepiphyseal dysplasia and retinal dystrophy: a novel syndrome. *Clin Genet*. 1999;55:103-9. PubMed PMID: 10189087.
- Shelihan I, Ehresmann S, Magnani C, Forzano F, Baldo C, Brunetti-Pierri N, Campeau PM. Lowry-Wood syndrome: further evidence of association with RNU4ATAC, and correlation between genotype and phenotype. *Hum Genet*. 2018;137:905-9. PubMed PMID: 30368667.
- Sigaudy S, Toutain A, Moncla A, Fredouille C, Bourlière B, Ayme S, Philip N. Microcephalic osteodysplastic primordial dwarfism Taybi-Linder type: report of four cases and review of the literature. *Am J Med Genet*. 1998;80:16-24. PubMed PMID: 9800907.
- Stenson PD, Mort M, Ball EV, Chapman M, Evans K, Azevedo L, Hayden M, Heywood S, Millar DS, Phillips AD, Cooper DN. The Human Gene Mutation Database (HGMD®): optimizing its use in a clinical diagnostic or research setting. *Hum Genet*. 2020;139:1197-207. PubMed PMID: 32596782.
- Taybi H, Linder D. Congenital familial dwarfism with cephaloskeletal dysplasia. *Radiology*. 1967;88:275-81.
- Winter RM, Wigglesworth J, Harding BN. Osteodysplastic primordial dwarfism: report of a further patient with manifestations similar to those seen in patients with types I and III. *Am J Med Genet*. 1985;21:569-74. PubMed PMID: 4025388.

License

GeneReviews® chapters are owned by the University of Washington. Permission is hereby granted to reproduce, distribute, and translate copies of content materials for noncommercial research purposes only, provided that (i) credit for source (<http://www.genereviews.org/>) and copyright (© 1993-2024 University of Washington) are included with each copy; (ii) a link to the original material is provided whenever the material is published elsewhere on the Web; and (iii) reproducers, distributors, and/or translators comply with the [GeneReviews® Copyright Notice and Usage Disclaimer](#). No further modifications are allowed. For clarity, excerpts of GeneReviews chapters for use in lab reports and clinic notes are a permitted use.

For more information, see the [GeneReviews® Copyright Notice and Usage Disclaimer](#).

For questions regarding permissions or whether a specified use is allowed, contact: admasst@uw.edu.